

Giant duodenal posterior wall ulcers complicated with hemorrhage: Long-term results of surgical treatment

Kraujuojančios dvylikapirštės žarnos užpakalinės sienos gigantinės opos: ilgalaikiai chirurginio gydymo rezultatai

Jaan Soplepmann¹, Margot Peetsalu², Toomas Väli², Ants Peetsalu²

¹ *Department of Surgical Oncology, Clinic of Hematology and Oncology of Tartu University Clinics, Vallikraavi 10, EST-51003 Tartu, Estonia*

² *Department of Abdominal Surgery, Clinic of Surgery of Tartu University Clinics, Puusepa 8, Tartu, Estonia*
E-mail: jaan.soplepmann@kliinikum.ee

Background / Objective

Giant duodenal posterior wall ulcers penetrating into the pancreas, complicated with hemorrhage are technically difficult to operate on. The aim of this investigation was to assess long-term results in patients operated on for GDPU complicated with hemorrhage, using the methods of Helwing and Herfarth, combined with vagotomy.

Patients and methods

During 1984-1993, 18 patients were operated on using procedures exteriorizing the giant ulcer base from the duodenal lumen. In 14 cases duodenal resection with plasty and in 4 cases antrectomy were performed, both combined with vagotomy. Two of the patients died postoperatively during hospital treatment. Long-term results were evaluated clinically and endoscopically according to the Visick scale 7-16 years (mean, 11 years) after operation in 10 patients. Four patients died from causes unrelated to peptic ulcer or operation and two patients were lost for follow-up.

Results

Long-term results were excellent or good in 90% (9/10) of the cases. In one patient the long-term result was assessed as satisfactory. Endoscopy revealed no cases of ulcer recurrence.

Conclusions

Ulcer base exteriorizing operations, i.e. duodenal resection with plasty or antrectomy, combined with vagotomy, yield good long-term results in the case of giant duodenal posterior wall ulcers penetrating into the pancreas, complicated with hemorrhage.

Key words: duodenal ulcer, penetration, hemorrhage, surgical treatment, long-term results

Introduction

The annual incidence of peptic ulcer hemorrhage varies from 25 to 58 cases per 100,000 population [1, 2]. In Estonia, the incidence is high, reaching 57 cases per 100,000 adults per year [3]. The need for the surgical treatment of ulcer hemorrhage has significantly decreased mainly owing to the use of endoscopic management both elsewhere [4, 5] and in Estonia [6].

When bleeding cannot be stopped endoscopically, or when it recurs after repeated endoscopic procedures, operative management is indicated. In certain high-risk cases early elective operations are recommended [7, 8].

The aim of the surgical treatment of hemorrhage is to stop bleeding, to prevent complications including bleeding recurrence, as well as to obtain good long-term outcome. Since 1977, our method of choice in duodenal ulcer hemorrhage has been excision of ulcer(s), and form and function preserving pyloro- or duodenoplasty after Holle plus vagotomy. This has yielded good or excellent long-term results in 86% of cases, with ulcer recurrence in 10% of cases on average 8 years after operation [9].

The most complicated phase of the operation is ulcer excision, particularly in the case of giant (larger than 2 cm in diameter) duodenal posterior wall ulcers penetrating into the pancreas (GDPU), which are often combined with stenosis. The operation is time-consuming, with the probability of intraoperative bleeding and with the danger of damaging the bile ducts and the pancreas; development of postoperative pancreatitis is possible. To avoid these problems, we have since 1984 introduced duodenal resection with plasty after Helwing et al. [10], combined with vagotomy (DPV) and antrectomy with reconstruction after Herfarth et al. [11], combined with vagotomy (AEV). In these methods, GDPU are not excised but exteriorized, i.e. the ulcer base is left out of the duodenal lumen.

The aim of this investigation was to assess long-term results in patients operated on for GDPU complicated with hemorrhage, using the methods of Helwing and Herfarth, combined with vagotomy.

Patients and methods

1. Patients

Between 1984 and 1993, 18 patients were operated on at the Department of Abdominal Surgery of Tartu University Clinics for GDPU complicated with hemorrhage, using DPV in 14 cases and AEV in 4 cases. Giant duodenal ulcers were defined as ulcers larger than 2 cm in diameter [12]. Patient data were obtained from the computer database of the Clinics. The age of the patients at the time of operation was 29–74 years (mean, 55 years). There were four female and fourteen male patients. Endoscopy had been performed in all patients preoperatively and the type of hemorrhage was classified according to the Forrest classification. Five of the patients had persistent bleeding (Forrest I); ten had stigmata of recent bleeding: a visible vessel, a clot in the ulcer base (Forrest II); three patients lacked stigmata of recent bleeding (Forrest III). Stenosis due to GDPU occurred in 11 patients of 18. Two of the patients died postoperatively during hospital treatment.

2. Operative methods

2.1. DPV after Helwing

The duodenum is mobilised employing the Kocher manoeuvre. Further, hemipylorotomy is performed with two semicircular incisions, one above and the other below the pylorus (Fig. 1A). GDPU becomes visible (Fig. 1B). Current bleeding is stopped by oversewing the bleeding vessel. The proximal part of the duodenum is mobilised from the ulcer and the pancreas by severing the duodenum proximal to the ulcer (Fig. 1C). In the case of stenosis, a circular resection of the stenosed region is performed. Thus two separate ends are formed, one on the gastric side and the other on the duodenal side. The posterior wall is then sutured in a one-row manner through all layers of the posterior wall of the gastric end to the distal edge of the giant ulcer with the posterior wall of the duodenal end (Fig. 1D). Thus the mobile posterior gastric wall is shifted to cover the ulcer base, leaving it out of the duodenal lumen, i.e. the ulcer

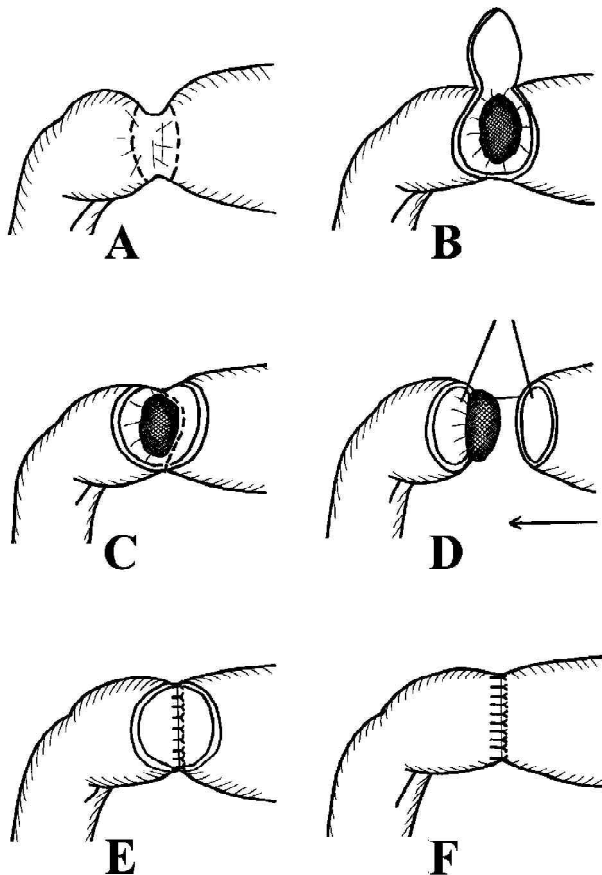


Fig. 1. Duodenal resection with plasty after Helwing. (A) Two semi-circular incisions for opening the duodenum. (B) A giant duodenal posterior wall ulcer is exposed. (C) Severing of the duodenum proximal to the ulcer. (D) The posterior wall is sutured, the gastric end to the distal edge of the ulcer. (E) The posterior wall sutures in place. The ulcer is exteriorized. (F) The anterior wall is sutured

base is exteriorized (Fig. 1E). Then the anterior wall is closed by a two-row suture (Fig. 1F). Further, vagotomy is carried out.

2.2. *AEV after Herfarth*

The Kocher manoeuvre is performed to mobilize the duodenum. Further, antrectomy is done so that the base of GDPU remains on the pancreas. Current bleeding is stopped by oversewing the bleeding vessel. Then the gastric stump is closed leaving an opening for the anastomosis. The posterior wall of the opening of the gastric stump is fixed by one-row sutures, involving all gastric layers, to the distal edge of the ulcer and the

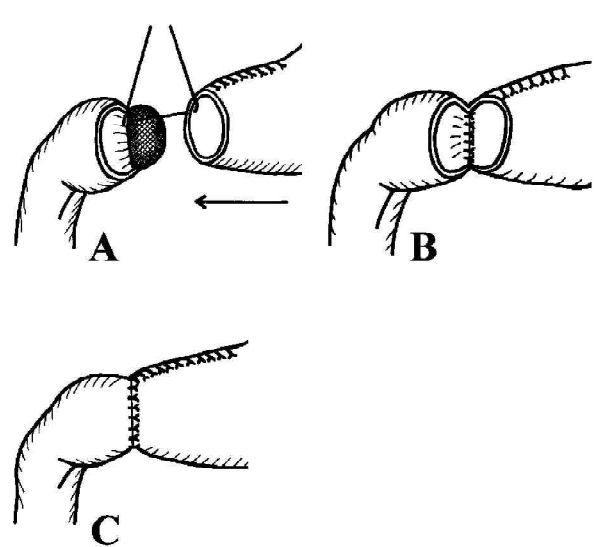


Fig. 2. Antrectomy after Herfarth. (A) Antrectomy has been performed. The posterior wall is sutured, the gastric end to the distal edge of the ulcer. (B) Posterior wall sutures are completed. The ulcer is exteriorized. (C) The anterior wall is sutured

back wall of the duodenum (Fig. 2A). In this way the posterior wall of the gastric stump is shifted to cover the ulcer base, while the latter is left out of the lumen, i.e. is exteriorized (Fig. 2B). Then the two-row suturing of the anterior wall will restore the integrity of the digestive tract (Fig. 2C). Further, bilateral truncal vagotomy is performed.

3. *Methods of assessment of long-term outcome*

A series of 16 patients that survived the operation was studied. All the patients were invited for outpatient follow-up between 2000 and 2001. Long-term results were assessed 7–16 years (mean, 11 years) after the operation. Nine patients turned up for the follow-up and one more patient agreed with a telephone interview. Four patients had died from causes unrelated to peptic ulcer or operation during the years that had passed from the operation. This was established on the basis of the death certificates obtained from the Population Registry. Two patients were lost to follow-up. No patient had been under peptic ulcer medication after the operation.

On follow-up the results were assessed according to a modified Visick scale [13] and an endoscopic in-

vestigation was performed. The Visick scale estimates were the following:

- Visick I – excellent: no symptoms
- Visick II – good: mild symptoms not interfering with normal life or work
- Visick III –satisfactory: mild or moderate symptoms causing a certain degree of discomfort or disability
- Visick IV – poor: severe symptoms or recurrent ulcer on endoscopy

On endoscopic investigation the status of the esophageal, gastric and duodenal mucosa was assessed for presence of recurrent ulcer and for the status of the anastomosis. Endoscopy was performed by a single experienced endoscopist.

Informed consent was obtained from each subject before entering the study.

Results

The long-term result was graded as Visick I in one patient (10%) and Visick II in eight patients (80%). In one patient (10%) the long-term result was assessed as Visick III. Endoscopy revealed no cases of ulcer recurrence. The anastomoses after DPV and AEV were sufficiently wide in all cases.

Discussion

GDPU are often the cause of severe hemorrhage, primarily owing to the erosion of a. gastroduodenalis [14]. In such cases the choice of the operative method is complicated [15], particularly when ulcer hemorrhage is accompanied with stenosis of the pyloroduodenal zone.

The results of our investigation demonstrate that in these cases, excellent or good long-term results without ulcer recurrence can be obtained in 90% of patients with the application of DPV or AEV. An earlier study of 15 patients by Helwing et al. [10], yielded good results in all cases 8–24 months after operation. Our results confirm good outcome for the first time for a much longer period, on average 11 years after operation.

In our opinion, the important determinant accounting for the achievement of such good long-term results

with the use of Helwing's method is the focus on the salvaging resection of the pyloroduodenal region together with form and function preserving plasty after Holle's concept [16]. Holle's pyloroplasty, though not widely used, showed good long-term results in our earlier study [13] and has also been recommended recently by other researchers [17]. According to Holle's concept, duodenal posterior wall ulcer is excised. This is feasible in the case of relatively small ulcers. However, in the case of GDPU, there arise technical problems. DPV enables to skip possible hazards and is technically simpler compared with ulcer excision. Stenosis from scarring around the ulcer, which according to our present study is frequent (in 61% of cases), can be simultaneously excised.

Our data show that DPV in the case of a bleeding GDPU can prevent several postoperative complications that may develop with applying other widely used operative techniques.

Some authors have recommended, in duodenal posterior wall ulcer hemorrhage, the oversewing of the bleeding vessel with or without pyloroplasty, combined with vagotomy [18, 19]. However, a significant drawback of oversewing is occurrence of early recurrent hemorrhage in up to 17–23% of operated on patients [20, 21], with a high mortality [21, 22].

Bumm and Siewert [23] recommend to combine the oversewing of the bleeding vessel in the ulcer base, through duodenotomy, with the extraluminal ligation of a. gastroduodenalis, a. gastroepiploica dextra and a. pancreatoduodenalis. Although postoperative mortality in this case has been reported as 3–6%, long-term results obtained with this method are not available. Besides, one should also take into account that the mere ligation of the bleeding vessel or the oversewing of the ulcer does not eliminate stenosis that may be present in cases of giant ulcer.

As an alternative, Billroth II gastric resection is performed in giant duodenal ulcers [15, 20]. However, we believe that Billroth II gastric resection is less appropriate than Billroth I type resection because of the possibility of duodenal leakage following the atypical closure of the duodenal stump, as well as a significantly

more frequent occurrence of postgastrectomy syndromes. Therefore, as our study shows, AEV with Billroth I reconstruction after Herfarth should be recommended [11], together with truncal vagotomy. A similar method has also been suggested by Herrington and Davidson [24]. Our earlier study of a long-term outcome on average 8 years after operation shows that truncal vagotomy with antrectomy in duodenal ulcer

patients yields excellent and good results without ulcer recurrence in 98% of cases [13].

Conclusion

Duodenal resection with plasty after Helwing and antrectomy after Herfarth, both combined with vagotomy, yield good long-term results in terms of local control in cases of GDPUs complicated with hemorrhage.

REFERENCES

1. Panos MZ, Walt RP. Current management of bleeding peptic ulcer. *Drugs* 1993; 46: 269–280.
2. Cutler JA, Mendeloff AI. Upper gastrointestinal bleeding. Nature and magnitude of the problem in the U.S. *Dig Dis Sci* 1981; 26 (July Suppl): 90–96.
3. Soplepmann J, Peetsalu A, Peetsalu M, Tein A, Juhola M. Peptic ulcer haemorrhage in Tartu county, Estonia: Epidemiology and mortality risk factors. *Scand J Gastroenterol* 1997; 32: 1195–1200.
4. Villanueva C, Balanzo J. A practical guide to the management of bleeding ulcers. *Drugs* 1997; 53: 389–403.
5. Asaki S. Efficacy of endoscopic pure ethanol injection method for gastrointestinal ulcer bleeding. *World J Surg* 2000; 24: 294–298.
6. Peetsalu M, Sillakivi T, Väli T, Tein A. Endoscopic diagnoses and treatment of peptic ulcer hemorrhage at the Clinic of Surgery of Tartu University Clinics. *Acta Medica Lituanica* 2001; 7 (Suppl): 109.
7. Mönig SP, Lübke T, Baldus SE, Schäfer H, Hölscher AH. Early elective surgery for bleeding ulcer in the posterior duodenal bulb. Own results and review of the literature. *Hepato-Gastroenterol* 2002; 49: 416–418.
8. Imhof M, Ohmann C, Röher HD, Glutig H. Endoscopic versus operative treatment in high-risk ulcer bleeding patients – results of a randomised study. *Langenbeck's Arch Surg* 2003; 387: 327–336.
9. Peetsalu A, Vardja T, Peetsalu M, Väli T. Long-term results of surgical treatment of bleeding duodenal ulcers. *Br J Surg* 1994; 81 (Suppl): 57.
10. Helwing E, Heymann H. Postpylorische Resektion des komplizierten Ulcus der Duodenalhinterwand im Rahmen form- und funktionsgerechter Magen Chirurgie. *Chirurg* 1978; 49: 29–32.
11. Herfarth C, Merkle P, Mattes P. Billroth I-Resektion beim großen penetrierenden Duodenalhinterwand-Ulkus. *Chirurg* 1977; 48: 123–124.
12. Collen MJ, Santoro MJ, Chen YK. Giant duodenal ulcer. Evaluation of basal acid output, nonsteroidal antiinflammatory drug use, and ulcer complications. *Dig Dis Sci* 1994; 39: 1113–1116.
13. Vardja T, Peetsalu A, Peetsalu M, Soplepmann J, Tein A, Väli T. Surgical treatment of duodenal ulcer disease: A long term follow-up study. *Acta Medica Baltica* 1996; 3: 256–263.
14. Swain CP. Pathophysiology of bleeding lesions. *Gastrointest Endosc* 1990; 36: 21–22.
15. Wu X, Zen D, Xu S, Zhang L, Wang P. A modified surgical technique for the emergent treatment of giant ulcers concomitant with hemorrhage in the posterior wall of the duodenal bulb. *Am J Surg* 2002; 184: 41–44.
16. Holle FK. The physiopathologic background and standard technique of selective proximal vagotomy and pyloroplasty. *Surg Gynecol Obstet* 1977; 145: 853–859.
17. Donahue PE. Parietal cell vagotomy versus vagotomy–antrectomy: Ulcer surgery in the modern era. *World J Surg* 2000; 24: 264–269.
18. Mills PR. Upper gastrointestinal hemorrhage. *Curr Opin Gastroenterol* 1991; 7: 920–924.
19. Gostout CJ, Wang KK, Ahlquist DA, Clain JE, Hughes RW, Larson MV, Petersen BT, Schroeder KW, Tremaine WJ, Viggiano TR, Balm RK. Acute gastrointestinal bleeding. Experience of a specialized management team. *J Clin Gastroenterol* 1992; 14: 260–267.
20. Hunt PS, McIntyre RLE. Choice of emergency operative procedure for bleeding duodenal ulcer. *Br J Surg* 1990; 77: 1004–1006.
21. Kubba AK, Choudari C, Rajgopal C, Palmer KR. The outcome of urgent surgery for major peptic ulcer haemorrhage following failed endoscopic therapy. *Eur J Gastroenterol Hepatol* 1996; 8: 1175–1178.
22. Kuttala K, Havia T, Pekkala E, Ali-Melkkilä T. Surgery of acute peptic ulcer haemorrhage. *Ann Chir Gynaecol* 1991; 80: 26–29.
23. Bumm R, Siewert JR. Chirurgisches Vorgehen beim Ulcus ventriculi und Ulcus duodeni. *Chirurg* 1998; 69: 588–596.
24. Herrington JL, Davidson J. Bleeding gastroduodenal ulcers: Choice of operations. *World J Surg* 1987; 11: 304–314.

Paper received: 10 September 2004

Paper accepted: 10 November 2004

Invited commentary

Recently, with having started to apply the endoscopic and medicamental treatment of bleeding gastroduodenal ulcers on a wide scale, surgical intervention remains necessary only in case bleeding from giant penetrating ulcers occurs. Usually such patients are delivered after having profusely bled frequently they are in the hemorrhagic shock condition. In the course of the operation, surgeons have to stop bleeding and to ensure that bleeding will not occur once again [1, 2]. This kind of operation is offered in the present article.

Annually in our clinic (VUH SC in the Center of Abdominal Surgery) 10–15 patients undergo an operation for the reasons of bleeding from duodenum ulcers. Almost all such patients are operated on for giant ulcers, half of which have already penetrated into the pancreas. Actually, our patients undergo the operation which is

REFERENCES

1. Nyhus LM, Sheaff CM. Surgery of the Esophagus, Stomach, and Small Intestine. In: Duodenal ulcers surgery. Edited by Wastell Ch, Nyhus LM, Donahue PE. 5th ed. Boston, New York, Toronto, London, 1995, p. 331–342.
2. Cowles RA, Mulholland MW. Surgical Management of Peptic Ulcer Disease in the Helicobacter Era – Management of Bleeding Peptic Ulcer. *Surgical Laparoscopy, Endoscopy & Percutaneous Techniques* 2002; 11 (1): 2–8.
3. Bubnys A. Chirurginė ulcerogeninės zonos ir skrandžio sekrecinės funkcijos korekcija gydančiam gastroduodeninės opas. Darbas habil. m. dr. laipsniui įgyti. Vilnius, 1994.

Invited commentary

Acute hemorrhage from intestinal tract is still serious problem. The bleeding duodenal ulcer with penetration into the pancreas is troublesome when endoscopic hemostasis is failed. Authors' proposed methods are usefull, good long-term result are noteworthy. We believe that surgical method is still one of the appropriate means for hemostasis.

In Japan, however, an emergency operation due to acute massive hemorrhage from the duodenal as well as from the gastric ulcer has decreased in recent

years. The overall complication rate after operation due to bleeding duodenal ulcer penetrating into pancreas is not low. In such cases we, therefore, choose radiological intervention, first of all. Angiography shows feeding vessels to the bleeding lesion in almost all cases. Arterial embolization can be performed even for the small artery with super-selector catheter [1,2].

After radiological hemostasis we treat duodenal ulcer with proton-pump inhibitor (PPI). It brings good healing of the ulcer. Additionally, we think that an eradication of *Helicobacter pylori* (*H.pylori*) and alternation of nonsteroidal anti-inflammatory drugs

identical to the one suggested by the author. In the course of the operation the bleeding is stopped, whereas the ulcers themselves recur very rarely (the number of recurrences makes 10.2%) [3]. This operation helps to avoid the common bile duct transgression; the possibility of the post-operational pancreatitis becomes reduced, since the posterior wall of the ventricle is sewn to the lower edge of the ulcer (as shown in Fig. 1D), without attempting to separate the duodenal ulcer from its lower edge [1, 4, 5].

Attention should be drawn to the fact that the patients usually remain in a serious general condition. Thus, in cases of duodenal ulcer a larger operation, i.e. antrumectomy, is not recommended, except the cases, pertaining to the post-operational ulcer recurrence.

Audrius Šileikis, M.D., Ph.D.

*Vilnius University Hospital "Santariškių klinikos",
Lithuania*

4. Meyer Ch, Brigand C, Rohr S. Surgical treatment of bleeding duodenal ulcer by antroduodenal resection, exclusion of the ulcer base, and duodenal closure after partial intramural dissection? *J Chir (Paris)* 2004; 141(2): 98–102.

5. Wu X, Zen D, Xu S, Zhang L, Wang P. A modified surgical technique for the emergent treatment of giant ulcers concomitant with hemorrhage in the posterior wall of the duodenal bulb. *Am J Surg* 2002; 184(1): 41–44.

(NSAIDs) (if the patient requires anti-inflammatory drugs) are useful in preventing the recurrence of duodenal ulcer. There are a lot of evidences that *H. pylori* infection is acknowledged to be an initial etiological factor of the duodenal ulcer, nevertheless serious bleeding is often seen in the *H. pylori*-negative patients especially who need NSAIDs, for whom we think reducing NSAIDs consumption and continu-

ous PPI or H2-receptor antagonist administration are necessary [3,4].

Michitaka Fujiwara, M.D., Ph.D.

Associate Professor,

Director of department of endoscopic surgery,

Nagoya University, School of Medicine

Nagoya 466-8550, Japan

REFERENCES

1. Ljungdahl M, Eriksson LG, Nyman R, et al. Arterial embolisation in management of massive bleeding from gastric and duodenal ulcers. *Eur J Surg* 2002; 168: 384–390.
2. Ripoll C, Banares R, Beceiro I, et al: Comparison of transcatheter arterial embolization and surgery treatment of bleeding peptic ulcer after endoscopic treatment failure. *J Vasc Interv Radiol* 2004; 15: 447–450.
3. Hunt RH, Bazzoli F.: Review article: should NSAID/low-dose aspirin takers be tested routinely for *H. pylori* infection and treated if positive? Implications for primary risk of ulcer and ulcer relapse after initial healing. *Aliment Pharmacol Ther* 2004; 19 Suppl 1: 9–16.
4. Adamopoulos AB, Efstathiou SP, Tsioulos DI, et al. Bleeding duodenal ulcer: comparison between *Helicobacter pylori* positive and *Helicobacter pylori* negative bleeders. *Dig Liver Dis* 2004; 36: 13–20.