

Isolated fallopian tube torsion associated with hydrosalpinx: case report and review of the literature

Izoliuotas kiaušintakio užsisukimas dėl kiaušintakio vandenės: atvejo aprašymas ir literatūros apžvalga

Rokas Trainavičius¹, Matas Mongirdas¹, Jonas Povilavičius², Kęstutis Trainavičius²

¹ *Vilniaus universiteto Medicinos fakultetas, M. K. Čiurlionio g. 21, LT-03101 Vilnius, Lietuva*

² *Vilniaus universitetas, Gastroenterologijos, nefrourologijos ir chirurgijos klinika, Vaikų chirurgijos centras, Santariškių g. 7, LT-08406 Vilnius, Lietuva*
El. paštas RokTrainav@gmail.com

¹ *Vilnius University, Faculty of Medicine, M.K. Čiurlionio Str. 21, LT-03101 Vilnius, Lithuania*

² *Vilnius University, Department of Gastroenterology, Nefrourology and Surgery, Center of Pediatric Surgery, Santariškių Str. 7, LT-08406 Vilnius, Lithuania*
E-mail: RokTrainav@gmail.com

Background

Isolated fallopian tube torsion due to hydrosalpinx is a rare cause of abdominal pain in adolescent patients. The incidence in reproductive age woman is 1:1 500 000. Only few cases have been reported of isolated fallopian tube torsion caused by hydrosalpinx in pediatric patients. The clinical manifestation is non-specific and usually diagnosis is set during diagnostic laparoscopy.

Case report

We present the case of 11 year old virgin girl, presented with acute lower right-sided abdominal pain. No specific symptoms were identified. Ultrasound showed an elongated cystic mass, measuring 80 mm in length and 15 mm width in the pelvic cavity. Hydrosalpinx of the right fallopian tube was suspected. The patient was scheduled for an laparoscopic operation, during which an enlarged and twisted fallopian tube was found. Detorsion ant puncture was performed.

Conclusion

Isolated fallopian tube torsion is very rare in adolescent patients and it can be often misdiagnosed. Although uncommon, isolated fallopian tube torsion should be included in every case of abdominal pain differential diagnosis.

Key words: hydrosalpinx, isolated fallopian tube torsion, children, laparoscopy.

Įvadas

Izoliuotas kiaušintakio užsisukimas dėl vandenės nustatomas 1:1 500 000 reprodukcinio amžiaus moterų. Itin retai ši liga yra vaikų pilvo skausmų priežastis. Literatūroje aprašyta tik keletas vaikų izoliuoto kiaušintakio užsisukimo dėl kiaušintakio vandenės atvejų. Liga neturi specifinių simptomų. Galutinė diagnozė patvirtinama atlikus laparoskopiją.

Klinikinis atvejis

11 metų mergaitė atvyko į priėmimo skyrių dėl staiga atsiradusių skausmų pilvo apačioje. Tiriant skausmas nustatytas dešinėje klubo srityje. Ultragarsinio tyrimo metu dubenyje pastebėtas 80 mm ilgio ir 15 mm skersmens cistinis darinys, prisipildęs skysčio. Buvo įtarta dešiniojo kiaušintakio vandenė. Atlikta laparoskopija, rastas išsiplėtęs, prisipildęs skysčio ir apsisukęs dešinysis kiaušintakis. Kiaušintakis atsuktas ir išpunktuotas.

Išvada

Kiaušintakio vandenės sukeltas izoliuotas kiaušintakio užsisukimas yra reta, todėl gana sunkiai nustatoma vaikų pilvo skausmų priežastis.

Reikšminiai žodžiai: hydrosalpinx'as, izoliuotas kiaušintakio užsisukimas, vaikai, laparoskopija.

Introduction

Torsion of the ovary is a rare cause of abdominal pain in adolescent patients. 2.7% of all abdominal pain causes is due to torsed ovary [1]. Isolated fallopian tube torsion is an even more uncommon clinical entity. The reported incidence of 1 in 1,5 million reproductive age woman. Only a few cases of isolated fallopian tube torsion have been reported in adolescent population. Hydrosalpinx is the main cause provoking fallopian tube torsion. This report describes an 11-year-old sexually inactive girl with isolated tubal torsion due to hydrosalpinx.

Case presentation

An 11-year-old virgin girl presented to our hospital's emergency room with a one-month history of intermittent pain in the lower left abdominal quadrant. On the day of admission, the pain intensified and the patient was hospitalized in the pediatric surgery department for further investigation. The patient was evaluated by an abdominal ultrasound and it showed an elongated cystic "C" shaped mass (Fig. 1), measuring 80 mm in length and 15 mm in width in the pelvic cavity. Hydrosalpinx of the right fallopian tube was suspected.

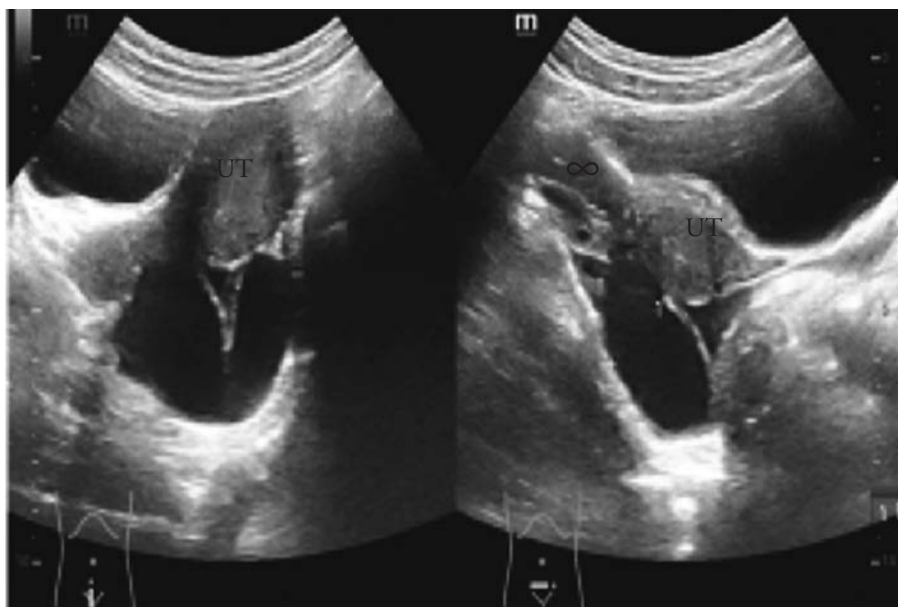


Figure 1. Ultrasound showing torsed fallopian tube, forming a "C" shape

The patient was scheduled for a laparoscopic operation, during which an enlarged and twisted fallopian tube was found. Detorsion and puncture was performed. The postoperative course was uneventful. The patient was discharged on the 6 postoperative day and sent for further observation.

Discussion

Hydrosalpinx (gr. *hydōr* – ‘water’; gr. *salpinx* – ‘trumpet’) is a fluid filled fallopian tube due to its distal part complete occlusion [2, 3]. Physiologically the tubal fluid is discharged through the fimbriated end into the peritoneal cavity from where it is absorbed. Occlusion of the distal part of the fallopian tube does not allow the tubal fluid to pass, resulting in its accumulation and reversal of flow downstream, into the uterus. The tube becomes fluid filled, distended and unable to participate in the reproductive process [2].

The main reason of hydrosalpinx in reproductive age woman is PID (pelvic inflammatory disease) caused by *Chlamydia trachomatis*, less often – ectopic pregnancy, endometriosis, appendicitis, former operations, *Mycoplasma tuberculosis* peritonitis, etc [4, 5]. Factors provoking development of hydrosalpinx in children differs from the ones in adult population. Boukaidi et al. reported thirteen cases of hydrosalpinx treatment in adolescent patients and found that none of them had conditions written above. Authors presume that progression of hydrosalpinx may be caused by congenital malformation. Levels of FSH (follicle-stimulating hormone) start to rise in girls of age 9 to 14 resulting in activation of the ovaries and fallopian tubes. Obstructed tube then becomes dilated, therefore symptomatic [1].

This illness has no specific symptoms. Patients usually complain about fewer, lower abdominal pain, associated with nausea and vomiting [6]. Rachel Casey et al. noticed that duration, intensity and localization of pain may vary. However, lower abdominal pain on the affected side is the most common display of hydrosalpinx [7]. Mobility of the left fallopian tube is limited by sigmoid colon therefore right fallopian tube torsion

is more usual. Furthermore, slower venous flow in right side forces the fallopian tube to bend [8].

Because of rare incidence and non-specific symptoms this pathology is often not included in differential diagnostics. More frequent conditions such as acute appendicitis or torsion of adnexa are suspected [9, 10]. That leads to inaccurate diagnostics and the choice of suboptimal treatment.

Ultrasound is the imaging modality of choice for adnexal torsion because it is safe, non-invasive and quick to perform [11]. Hydrosalpinx is visible as fluid-filled tubular structure forming C or S shape and separated from the ovaries [2]. Colour Dopler is important, however its hard to determine if the fallopian tube is viable, because of dual fallopian tube blood flow [12, 13]. CT and MRA are not used as first choice diagnostic methods [14]. Although diagnosis may be suspected on imaging, fallopian tube torsion is ultimately diagnosed during exploratory surgery [7].

Isolated fallopian tube torsion should be treated as fast as the diagnosis is set. Without early surgical intervention the tube may undergo irreversible vascular changes requiring salpingectomy and possibly salpingoophrectomy [15]. Boukaidi et al. suggested two step surgical approach for isolated fallopian tube torsion due to hydrosalpinx. Firstly, the tube should be untwisted with or without puncturing. Secondly, in another surgical session, authors recommend performing salpingoneostomy or salpingectomy, depending on the viability of the tube [2]. There is no long-term data supporting management of hydrosalpinx and what impact it makes for women's future fertility. More research is needed on the subject to produce a clearer evidence based treatment algorithm.

Conclusion

Isolated fallopian tube torsion is very rare in adolescent patients and it can be often misdiagnosed. Although uncommon, isolated fallopian tube torsion should be included in every case of abdominal pain differential diagnosis.

REFERENCES

1. Legro RS, Lin HM, Demers LM, Lloyd T. Rapid maturation of the reproductive axis during perimenarche independent of body composition. *J Clin Endocrinol Metab* 2000; 85: 1021–1025.
2. Boukaidi SA, Delotte J, Steyaert H, Valla JS, Sattonet C, Bouaziz J, Bongain A. Thirteen cases of isolated tubal torsions associated with hydrosalpinx in children and adolescents, proposal for conservative management: retrospective review and literature survey. *J Pediatr Surg* 2011; 46: 1425–1431.
3. Granot I, Dekel N, Segal I, Fieldust S, Shoham Z, Barash A. Is hydrosalpinx fluid cytotoxic? *Hum Reprod* 1998; 13(6): 1620–1624.
4. Pampal A, Atac GK, Nazli ZS, Ozen IO, Sipahi T. A rare cause of acute abdominal pain in adolescence: hydrosalpinx leading to isolated torsion of fallopian tube. *J Pediatr Surg* 2012; 47(12): e31–e34.
5. Bontis JN, Dinas KD. Management of hydrosalpinx: reconstructive surgery or IVF? *Ann N Y Acad Sci* 2000; 900: 260–271.
6. Dunnington DR, Wolff J. Bilateral torsion of the adnexa: case report and a review of the world literature. *Obstet Gynecol* 1984; 64(3): 55S–59S.
7. Casey RK, Damle LF, Gomez-Lobo V. Isolated fallopian tube torsion in pediatric and adolescent females: a retrospective review of 15 cases at a single institution. *J Pediatr Adolesc Gynecol* 2013; 26: 189–192.
8. Powell JL, Foley GP, Llorens AS. Torsion of the fallopian tube in the premenopausal women. *Am J Obstet Gynecol* 1972;113: 115–118.
9. Maynard SR, Peipert JF, Brody JM. Tubal torsion appearing as acute pelvic inflammatory disease. *J Am Assoc Gynecol Laparoscopy* 1996; 3: 431–433.
10. Krissi H, Shalev J, Bar-Hava I, Langer R, Herman A, Kaplan B. Fallopian tube torsion; laparoscopic evaluation and treatment of rare gynaecological entity. *J Am Board Fam Pract* 2001; 14(4): 274–277.
11. Meyer JS, Harmon CM, Harty MP, Markowitz RI, Hubbard AM, Bellah RD. Ovarian torsion: clinical and imaging presentation in children. *J Pediatr Surg* 1995; 30: 1433–1436.
12. Baumgartel P, Fleischer A, Cullinan J, Bluth R. Color Doppler sonography of tubal torsion. *Ultrasound Obstet Gynecol* 1996; 7: 367–370.
13. Origoni M, Cavoretto P, Conti E, Ferrari A. Isolated tubal torsion in pregnancy. *European Journal of Obstetrics Gynecology and Reproductive Biology* 2009; 146(2): 116–120.
14. Merlini L, Anooshiravani M, Vunda A, Borzani I, Napolitano M, Hanquinet S. Noninflammatory fallopian tube pathology in children. *Pediatr Radiol* 2008; 38(12): 1330–1337.
15. Dadhwal V, Gupta N, Gupta B, Deka D, Mittal S. Laparoscopic management of isolated fallopian tube torsion in a premenarchal 13-year-old adolescent girl. *Arch Gynecol Obstet* 2009; 279: 909–910.