

Successful Endovascular Management of Recurrent Hemoptysis due to Multiple Rasmussen Aneurysms in a Case of Pulmonary Tuberculosis: A Rare Case Scenario

Shritik Devkota

Department of Radiodiagnosis and Imaging, Post Graduate Institute of Medical Education & Research, Chandigarh, India
<https://orcid.org/0000-0001-5051-2037>

Harish Bhujade*

Department of Radiodiagnosis and Imaging, Post Graduate Institute of Medical Education & Research, Chandigarh, India

Abhiman Baloji

Department of Radiodiagnosis and Imaging, Post Graduate Institute of Medical Education & Research, Chandigarh, India
<https://orcid.org/0000-0002-3369-6409>

Nidhi Prabhakar

Department of Radiodiagnosis and Imaging, Post Graduate Institute of Medical Education & Research, Chandigarh, India

Atul Saroch

Department of Internal Medicine, Post Graduate Institute of Medical Education & Research, Chandigarh, India
<https://orcid.org/0000-0001-9723-6500>

Ujjwal Gorski

Department of Radiodiagnosis and Imaging, Post Graduate Institute of Medical Education & Research, Chandigarh, India

Abstract. Background: Hemoptysis is defined as coughing out of blood. Pulmonary tuberculosis is the most common cause of hemoptysis in tuberculosis-endemic countries like India. Rasmussen aneurysm is a pseudoaneurysm arising from the pulmonary artery adjacent to or within a tuberculous cavity. Chest radiographs, chest computed tomography angiography (CTA), and digital subtraction angiography (DSA) are the imaging tools for evaluating a case of hemoptysis.

Case: A 32-year-old man with a history of pulmonary tuberculosis presented with complaints of recurrent hemoptysis. On imaging evaluation, multiple pulmonary artery pseudoaneurysms were seen in the left lung. The patient was shifted to the DSA lab and the pseudoaneurysms were subsequently treated by endovascular coil embolization. Hemoptysis resolved following the procedure and the patient was again started on anti-tubercular therapy.

Conclusion: Endovascular coiling is minimally invasive, safe, and effective management of multiple Rasmussen aneurysms for preventing possible torrential blood loss and unfortunate death.

Keywords: Rasmussen aneurysm, pulmonary tuberculosis, pulmonary artery pseudoaneurysm, coil embolization

* Corresponding author: Harish Bhujade, Department of Radiodiagnosis and Imaging, Post Graduate Institute of Medical Education & Research, Chandigarh, India. E-mail: harish_bhujade@yahoo.com

Received: 23/01/2024. Revised: 25/03/2024. Accepted: 29/05/2024

Copyright © 2024 Shritik Devkota, Harish Bhujade, Abhiman Baloji, Nidhi Prabhakar, Atul Saroch, Ujjwal Gorski. Published by Vilnius University Press. This is an Open Access article distributed under the terms of the Creative Commons Attribution License, which permits unrestricted use, distribution, and reproduction in any medium, provided the original author and source are credited.

Sėkmingas endovaskulinis pasikartojančios hemoptizės dėl daugybinių Rasmusseno aneurizmų plaučių tuberkuliozės atveju gydymas: retas atvejis

Santrauka. Įvadas: Hemoptizė yra kosulys su krauju. Endeminėse šalyse, pavyzdžiui, Indijoje, plaučių tuberkuliozė yra dažniausia hemoptizės priežastis. Rasmusseno aneurizma yra pseudoaneurizma, atsirandanti iš plaučių arterijos, esančios šalia tuberkuliozinės ertmės arba jos viduje. Krūtinės ląstos rentgenogramos, krūtinės ląstos kompiuterinės tomografijos angiografija (KTA) ir skaitmeninė subtrakcinė angiografija (DSA) – tai vaizdinimo priemonės hemoptizės atvejui įvertinti.

Atvejis: 32 metų vyras, sirgęs plaučių tuberkulioze, skundėsi pasikartojančia hemoptize. Atlikus vaizdų vertinimą, kairiajame plautyje buvo matomos daugybinės plaučių arterijos pseudoaneurizmos. Pacientas buvo perkeltas į DSA laboratoriją, o vėliau pseudoaneurizmos gydytos endovaskuline spiraline embolizacija. Po procedūros hemoptizė išnyko ir pacientui vėl buvo pradėtas antituberkuliozinis gydymas.

Išvados: Endovaskulinė embolizacija yra minimaliai invazinis, saugus ir veiksmingas daugybinių Rasmusseno aneurizmų gydymas, siekiant išvengti galimo didelio kraujo netekimo ir nelaimingos mirties.

Raktažodžiai: Rasmusseno aneurizma, plaučių tuberkuliozė, plaučių arterija

Introduction

Hemoptysis is defined as coughing out of blood [1-5]. There are many definitions cited in literature for grading hemoptysis as massive or life threatening. A consistent definition for “massive haemoptysis” remains elusive, with the literature offering a wide range of thresholds based on expectorated blood volume [1-4]. 100 ml is the smallest volume of hemoptysis in 24 hours that has been described in the literature as endangering the patient’s life [2].

There are several causes of hemoptysis such as pulmonary tuberculosis (both primary and post-primary), malignancies, other infections, bronchiectasis, pulmonary embolism, heart failure, iatrogenic (anticoagulants, bronchoscopy, biopsy), arteriovenous malformation, trauma, foreign body, bronchitis and vasculitis [6-10]. Hemoptysis may be associated with pulmonary tuberculosis (PTB) in about 8–10% of all cases. The sources of bleed in case of pulmonary tuberculosis can be either due to Rasmussen aneurysm caused by destructive cavitory lung changes, bronchial artery hypertrophy or erosion of a calcified granulomatous lymph node into the airway [6-10].

Rasmussen aneurysm is a pseudoaneurysm arising from the pulmonary artery adjacent to or within a tuberculous cavity [11-13]. Rasmussen’s aneurysm arises from a sequential weakening of the pulmonary artery wall. Granulation tissue replaces the structurally supportive adventitia and media layers, ultimately being replaced by less robust fibrin. This progressive deterioration renders the wall thin and susceptible to pseudoaneurysm formation [11,14-18].

Pseudoaneurysms, lacking a complete vascular wall, are prone to haemorrhage within the lung parenchyma or bronchial tree. Mycobacterial tuberculosis isn’t the sole infectious cause of pulmonary artery pseudoaneurysms; fungal and bacterial pneumonia can also lead to them. Non-infectious mechanisms, including tumor invasion, vasculitis, radiation, trauma, and iatrogenic procedures, are also prevalent [6,19,20].

Chest X-ray guides initial hemoptysis evaluation, but chest CT angiography remains the gold standard for definitive diagnosis. Detailed imaging evaluation followed by timely intervention is needed for mitigating the risk of increased morbidity and mortality related to Rasmussen aneurysm [5-7,9,10,19,20].

Hemoptysis primarily leads to mortality through asphyxiation rather than exsanguination [7,12]. The cornerstone of hemoptysis management involves hemodynamic resuscitation and airway patency followed by targeted therapy addressing the underlying etiology to minimize mortality risk [7,9,10,12].

Hemoptysis secondary to Rasmussen aneurysm is a rare entity. Furthermore, only few case reports are available in the literature regarding hemoptysis secondary to multiple Rasmussen aneu-

rysm [12,21-24]. We aimed to share our experience in successfully managing a rare and challenging case of multiple Rasmussen's aneurysms in a patient with known pulmonary tuberculosis with endovascular embolization.

Case report

A 32-year-old male presented to the emergency department with recurrent episodes of mild hemoptysis (volume of ~20–25 ml/episode) and intermittent low-grade fever for last 6 months. He had previous history of pulmonary tuberculosis one year back for which he had completed 6 months of antitubercular therapy (ATT). He had no other comorbidities. Vitals were stable at the time of presentation (Pulse rate – 76/min, blood pressure – 116/78 mm of Hg, respiratory rate – 16/min, oxygen saturation – 97% and normal general survey).

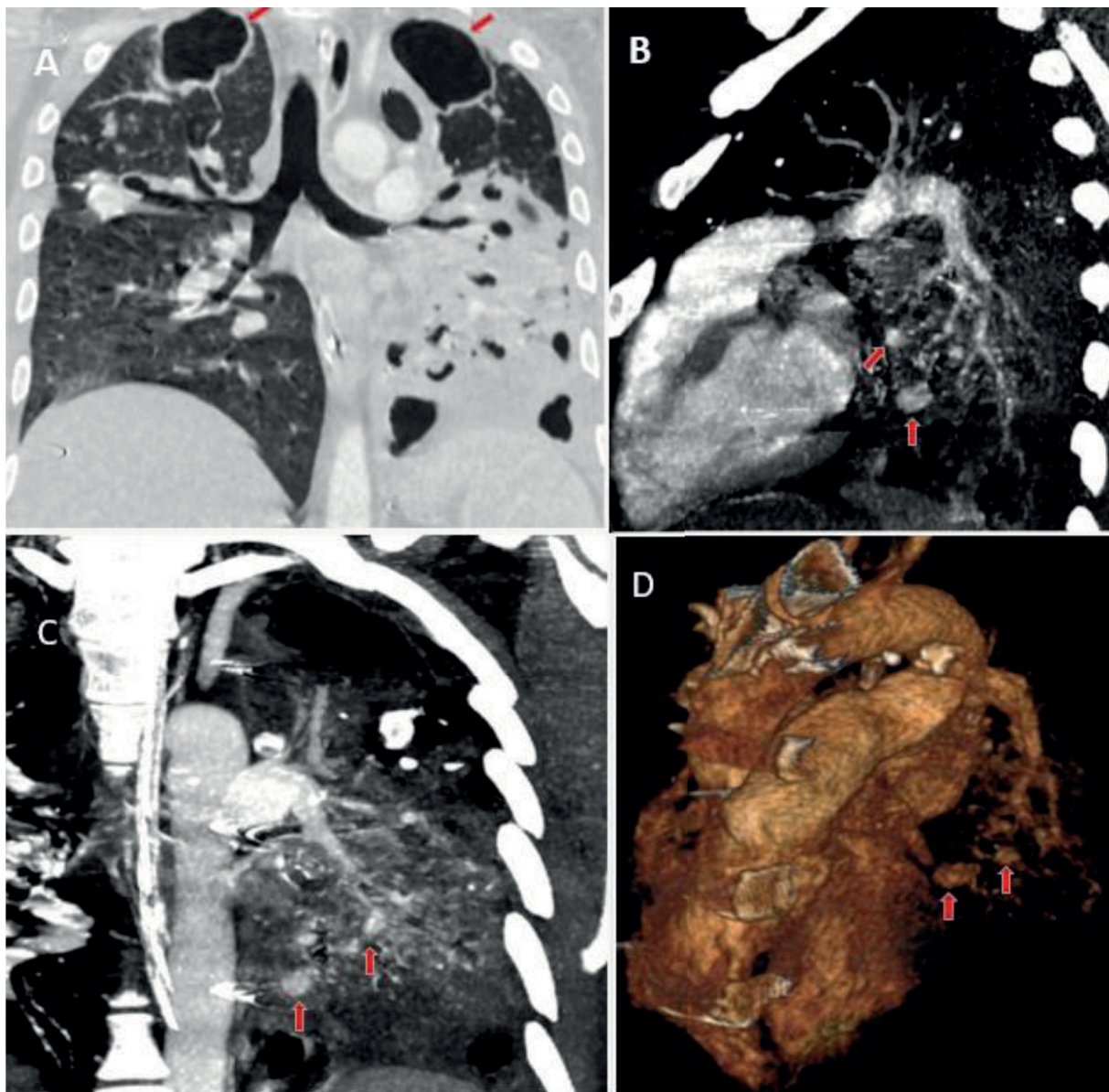


Fig. 1. Chest CT angiography (CTA). Lung window (A) showing cavitations in bilateral upper lobes (red arrows) with destroyed lingula and left lower lobe. Maximum intensity projection (MIP) sagittal (B), coronal (C) and 3D virtual (D) reconstructions showing contrast filled outpouchings (red arrows) arising from branches of left pulmonary artery.

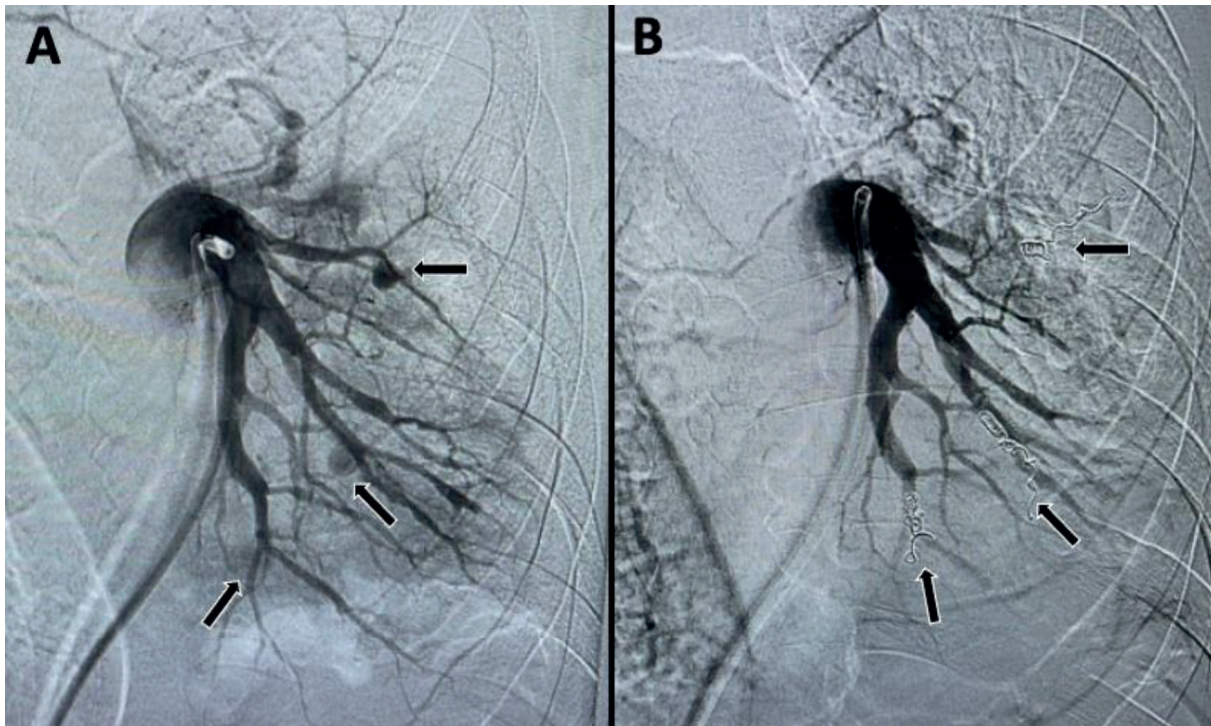


Fig. 2. Digital subtraction angiography (DSA). Left pulmonary artery run (A) showing three contrast filled outpouchings (black arrows) from its branches. Final left pulmonary artery run (B) showing coil mass in situ with nonopacification of the previous outpouchings suggesting successful embolization (black arrows).

Sputum Gene-xpert was positive for *Mycobacterium tuberculosis*. He had low Hb level (~10.5 gm/dL). CTA (Figure 1) was done which revealed multiple contrast-filled outpouchings from branches of left pulmonary artery adjacent to fibrocavitary and fibro-bronchiectatic changes.

Thereafter, patient was shifted for pulmonary digital subtraction angiography (DSA). Informed consent was taken for the procedure. Using right common femoral venous access, left pulmonary angiogram (Figure 2A) was taken which showed three contrast-filled outpouchings from branches of left pulmonary artery. Superselective cannulation of each branch supplying the pseudoaneurysm was done using the Progreat microcatheter (Terumo medical corporation, New Jersey). The branch supplying each pseudoaneurysm was embolized using two 5 mm x 14 cm and one 4 mm x 14 cm Nester microcoils (Cook Medical, Bloomington, USA). Post-embolization, there was complete non-opacification of all pseudoaneurysms (Figure 2B). Hemoptysis resolved following the procedure. Patient was again started on multi-drug resistant ATT regimen.

Discussion

Pulmonary tuberculosis can present in varying spectrum extending from insidious systemic and respiratory symptoms to hemoptysis and multisystemic dissemination. Important causes of hemoptysis in pulmonary tuberculosis include bleeding from cavity wall, Rasmussen aneurysm, and bronchial artery hypertrophy [5,6,11,12,15,16]. Rasmussen aneurysm in itself is a rare entity, while literature regarding multiple Rasmussen aneurysms in same patient in same lung are scarce [12,21-24].

The term "Rasmussen" originates from the work of Fritz Valdemar Rasmussen et al., who provided a comprehensive pathological analysis of 11 cases in 1868 [25]. Rasmussen's aneurysm manifests as a sequela of a progressive and detrimental cascade within the pulmonary arterial wall. This deleterious process commences with the insidious substitution of the structurally robust adventitia and

media layers by less resilient granulation tissue. This initial compromise is ultimately compounded by the further supplantation of the granulation tissue with the markedly less robust fibrin. The culmination of this pathological odyssey is a demonstrably thinned and structurally compromised arterial wall, rendering it exceedingly susceptible to the formation of a pseudoaneurysm [5,6, 11,14-18].

Extensive clinical, laboratory and imaging evaluation is needed in patients presenting with hemoptysis. Patients' symptomatology, history of comorbidities and prior ATT are critical when investigating a case of prior pulmonary tuberculosis [5,6,9,10,15]. Chest radiograph, chest CTA and DSA are the imaging tools. Chest radiograph is predominantly used as initial screening tool to have an overall gross idea about the disease. Chest X-ray can show cavitations, bronchiectasis, consolidations in such cases of tuberculosis [9,10,26]. Contrast enhanced CT (CECT) or chest CTA can further help us in knowing the culprit for hemoptysis in addition to the severity of parenchymal disease. On CTA, Rasmussen aneurysm is seen as a focal outpouching arising from pulmonary artery branches. The outpouching may show irregular wall. Surrounding contained hematoma may also be observed [5,6,19,20]. DSA serves as both diagnostic and interventional tool for management of Rasmussen aneurysm [5-7,16,17,19,20,22,23]. Furthermore, bronchoscopy serves a pivotal role in the management of hemoptysis by facilitating the precise localization of the bleeding site. This localization capability allows for the targeted application of therapeutic interventions aimed at achieving definitive haemostasis [9, 26-28].

Hemodynamic and airway stabilization are the foremost considerations when managing a case of hemoptysis [7,9,15,26,27]. Patients' vitals are continuously monitored, and oxygenation is provided. Massive hemoptysis may even require endotracheal intubation for securing adequate respiratory gas exchange [9, 26-28]. Following the initial stabilization of vital signs, a comprehensive imaging workup is then undertaken. This detailed diagnostic evaluation aims to identify the underlying etiology responsible for the hemoptysis event. Only after a definitive diagnosis is established, targeted therapeutic interventions can be implemented to address the root cause and definitively control bleeding.

The vascular cause for hemoptysis is primarily treated by endovascular route. Endovascular management for Rasmussen aneurysm includes coil, plug or glue embolization [7-9,22,23,28]. In index case, microcoils were used as there is better control and precision compared to endovascular glue embolization. The side-branch anchor technique was used to place the microcoils to avoid the distal migration. For larger calibre vessels, vascular plug may be used. The microcoil is more cost-effective than vascular plug. Therefore, careful planning and choice of embolizing agent should be done to get desired outcome and less complications considering the cost of the embolization agents. This case highlights the usefulness of cross-sectional imaging for the diagnosis and planning of embolization. Coil embolization can be considered when there are multiple Rasmussen aneurysms without major complications.

Conclusion

The index case emphasizes that hemoptysis may occur due to multiple Rasmussen aneurysms in a patient with post-primary tuberculosis. Careful evaluation of chest CTA helps to localize multiple aneurysms and is also beneficial for planning of the therapy. Endovascular coiling is a minimally invasive, safe and effective method for treatment of multiple Rasmussen aneurysms.

References

1. Ibrahim WH. Massive haemoptysis: the definition should be revised. *Eur Respir J*. 2008;32(4):1131-1132. doi:10.1183/09031936.00080108
2. Amirana M, Frater R, Tirschwell P, Janis M, Bloomberg A, State D. An aggressive surgical approach to significant hemoptysis in patients with pulmonary tuberculosis. *Am Rev Respir Dis*. 1968;97(2):187-192. doi:10.1164/arrd.1968.97.2.187

3. Corey R, Hla KM. Major and massive hemoptysis: reassessment of conservative management. *Am J Med Sci.* 1987;294(5):301-309. doi:10.1097/00000441-198711000-00003
4. Knott-Craig CJ, Oostuizen JG, Rossouw G, Joubert JR, Barnard PM. Management and prognosis of massive hemoptysis. Recent experience with 120 patients. *J Thorac Cardiovasc Surg.* 1993;105(3):394-397.
5. Bruzzi JF, Rémy-Jardin M, Delhaye D, Teisseire A, Khalil C, Rémy J. Multi-detector row CT of hemoptysis. *Radiographics.* 2006;26(1):3-22. doi:10.1148/rg.261045726
6. Marquis KM, Raptis CA, Rajput MZ, et al. CT for Evaluation of Hemoptysis. *Radiographics.* 2021;41(3):742-761. doi:10.1148/rg.2021200150
7. Davidson K, Shojaee S. Managing Massive Hemoptysis. *Chest.* 2020;157(1):77-88. doi:10.1016/j.chest.2019.07.012
8. Panda A, Bhalla AS, Goyal A. Bronchial artery embolization in hemoptysis: a systematic review. *Diagn Interv Radiol.* 2017;23(4):307-317. doi:10.5152/dir.2017.16454
9. Larici AR, Franchi P, Occhipinti M, et al. Diagnosis and management of hemoptysis. *Diagn Interv Radiol.* 2014;20(4):299-309. doi:10.5152/dir.2014.13426
10. Gagnon S, Quigley N, Dutau H, Delage A, Fortin M. Approach to Hemoptysis in the Modern Era. *Can Respir J.* 2017;2017:1565030. doi:10.1155/2017/1565030
11. Iqbal S, Nassar M, Kondaveeti R, O'Brien T, Siddiqui RS, Lopez R. Massive Hemoptysis in Previously Treated Pulmonary Tuberculosis: A Case Series. *Cureus.* 2022;14(8):e27882. doi:10.7759/cureus.27882
12. Chatterjee K, Colaco B, Colaco C, Hellman M, Meena N. Rasmussen's aneurysm: A forgotten scourge. *Respir Med Case Rep.* 2015;16:74-76. doi:10.1016/j.rmcr.2015.08.003
13. Marak JR, Kumar T, Gara H, Dwivedi S. Rasmussen aneurysm: Case series of a rare complication of Pulmonary Tuberculosis. *Respir Med Case Rep.* 2023;45:101897. doi:10.1016/j.rmcr.2023.101897
14. Jadhav SS, Dhok A, Chaudhari SV, Khandaitkar S, Ambhore AN. Rasmussen's Aneurysm: A Rare Case. *Cureus.* 2022;14(6):e25740. doi:10.7759/cureus.25740
15. Lin F, Chen N, Li C, Liu L. Rasmussen's aneurysm. *QJM.* 2018;111(4):273. doi:10.1093/qjmed/hcx230
16. Kim HY, Song KS, Goo JM, Lee JS, Lee KS, Lim TH. Thoracic sequelae and complications of tuberculosis. *Radiographics.* 2001;21(4):839-860. doi:10.1148/radiographics.21.4.g01jl06839
17. Guillaume B, Vendrell A, Stefanovic X, Thony F, Ferretti GR. Acquired pulmonary artery pseudoaneurysms: a pictorial review. *Br J Radiol.* 2017;90(1073):20160783. doi:10.1259/bjr.20160783
18. Gomes de Farias LP, Kaiser Ururahy Nunes Fonseca E, Chate RC, Sawamura MVY. Rasmussen Aneurysm. *Radiol Cardiothorac Imaging.* 2021;3(3):e210026. doi:10.1148/ryct.2021210026
19. Chen Y, Gilman MD, Humphrey KL, et al. Pulmonary Artery Pseudoaneurysms: Clinical Features and CT Findings. *AJR Am J Roentgenol.* 2017;208(1):84-91. doi:10.2214/AJR.16.16312
20. Nguyen ET, Silva CI, Seely JM, Chong S, Lee KS, Müller NL. Pulmonary artery aneurysms and pseudoaneurysms in adults: findings at CT and radiography. *AJR Am J Roentgenol.* 2007;188(2):W126-W134. doi:10.2214/AJR.05.1652
21. Wu J, Tang Z. A case of multiple Rasmussen's aneurysm. *Quant Imaging Med Surg.* 2023;13(12):8803-8806. doi:10.21037/qims-23-460
22. Diakité AT, Nguyen B, Mihalciou S, Morin C, Philie M. Multiple Rasmussen Aneurysms in Active Cavitary Pulmonary TB: Endovascular Management for Submassive Hemoptysis. *Chest.* 2020;158(4):A492-A493. doi:10.1016/j.chest.2020.08.472
23. Santelli ED, Katz DS, Goldschmidt AM, Thomas HA. Embolization of multiple Rasmussen aneurysms as a treatment of hemoptysis. *Radiology.* 1994;193(2):396-398. doi:10.1148/radiology.193.2.7972750
24. Cueto-Robledo G, Graniel-Palafox LE, Garcia-Cesar M, Cueto-Romero HD, Roldan-Valadez E. Images in Vascular Medicine: Multiple Rasmussen aneurysms in noncavitary, multidrug-resistant tuberculosis. *Vasc Med.* 2022;27(3):308-309. doi:10.1177/1358863X211056681
25. Rasmussen V, Moore WD. On Hæmoptysis, Especially When Fatal, in Its Anatomical and Clinical Aspects. *Edinb Med J.* 1868;14(6):486-503.
26. Ittrich H, Bockhorn M, Klose H, Simon M. The Diagnosis and Treatment of Hemoptysis. *Dtsch Arztebl Int.* 2017;114(21):371-381. doi:10.3238/arztebl.2017.0371
27. Haponik EF, Fein A, Chin R. Managing life-threatening hemoptysis: has anything really changed? *Chest.* 2000;118(5):1431-1435. doi:10.1378/chest.118.5.1431
28. Earwood JS, Thompson TD. Hemoptysis: evaluation and management. *Am Fam Physician.* 2015;91(4):243-249.