

# Treatment of experimental amyloidosis with antirheumatic drugs

Laima Leonavičienė<sup>1</sup>,

Danutė Povilėnaitė<sup>1</sup>,

Rūta Bradūnaitė<sup>1</sup>,

Dalia Vaitkienė<sup>1,2</sup>,

Algirdas Venalis<sup>1,2</sup>

<sup>1</sup> State Research Institute,  
Centre for Innovative Medicine,  
Lithuania

<sup>2</sup> Faculty of Medicine,  
Vilnius University, Lithuania

**Background.** Because at present there is no known specific effective therapy for secondary amyloidosis, the aim of this study was to determine whether antirheumatic drugs inhibit the development of experimental AA amyloidosis induced in C57BL/6 mice by casein and fibrin injections.

**Materials and methods.** Monotherapy with sulfasalazine (SSL) and diclofenac (D) and a combined treatment with diclofenac and prednisolone (D/P) according to prophylactic and therapeutic treatment protocols were investigated. The drugs were administered through intragastric gavage 5 times a week for 5 or 4 weeks in the following doses: D – 1 mg/kg, P – 10 mg/kg, and SSL – 100 mg/kg. A histopathological examination of splenic, kidney and hepatic tissues of mice was performed. The amount of amyloid was assessed semi-quantitatively by polarizing microscopy after Congo red staining.

**Results.** Our study indicated that no positive effect of the prophylactic treatment with D could be seen on amyloid deposition in the target organs. Prophylactic combined treatment with D/P resulted in a significant improvement of disease symptoms and markedly reduced amyloid deposits in the spleen, kidneys and liver ( $p < 0.02$ – $0.001$ ). SSL therapy alone was more successful in the prophylactic treatment of experimental amyloidosis: the decrease of amyloid deposits was statistically significant in all examined organs ( $p < 0.04$ – $0.001$ ), and the suppression of amyloid formation was most significant in the kidneys and liver ( $p < 0.004$ – $0.001$ ). In the therapeutic treatment of experimental amyloidosis, combined treatment with D/P showed the most pronounced inhibition of amyloid formation in the internal organs ( $p < 0.006$ – $0.001$ ). The suppression (by 86.7%;  $p < 0.001$ ) of amyloid deposits was most notable in the liver. Treatment of mice with D alone produced a significant reduction in amyloid deposition only in the liver ( $p < 0.03$ ) and with SSL only in the spleen ( $p < 0.03$ ).

**Conclusions.** These findings suggest that D/P and SSL at relevant doses suppress amyloidogenesis, and this suppression is possibly related to the anti-inflammatory effect of antirheumatic drugs. Although these drugs cannot completely inhibit the disease in this model, a possibility remains that they may be clinically useful in rheumatic diseases associated with the formation of amyloidogenic derivatives.

**Key words:** mice, experimental AA amyloidosis, antirheumatic drugs

## INTRODUCTION

Secondary (AA) amyloidosis is a systemic disease characterized by the dysfunction and destruction of organs through the deposition of amyloid protein (1, 2). It can potentially complicate any disorder associated with sustained acute-

phase response (3) and the most frequent predisposing conditions in the developed world, i. e. idiopathic rheumatic diseases (4–6).

AA amyloidosis was probably the first amyloid described clinically and the first for which animal models were established experimentally (3, 7, 8). The induction and *in vivo* reversibility of AA amyloidogenesis have become powerful tools for investigating the amyloid deposition mechanism and possible therapies (7, 9, 10). Many of the lessons learned about amyloid have come from the study of rodent models

Correspondence to: Laima Leonavičienė, State Research Institute, Centre for Innovative Medicine, Žygimantų 9, LT-01102 Vilnius, Lithuania.  
E-mail: laima.leonaviciene@ekmi.vu.lt

of amyloid A. AA amyloidosis can easily be induced in mice, provoked by an inflammatory challenge (3). Mouse models of AA amyloidosis are still the best animal models of amyloidogenesis available (11, 12).

The aims of amyloidosis treatment are suppressing chronic inflammation and inhibiting the production and deposition of amyloid protein. However, the only, as well as the most practical, way to prevent the development or progression of reactive amyloidosis is to reduce inflammatory activity (13). Some chemotherapeutic drugs such as melphalan, prednisone, and colchicine have been shown to be effective in some patients (14). Other medications (terbutaline, aminophyllin, colchicine, and tenidap) are reported to inhibit experimental amyloidosis in mice (15, 16).

In this study, we focused on therapy with sulfasalazine (SSL), diclofenac (D), and prednisolone (P), which have been widely used for the treatment of rheumatoid arthritis (RA), and examined whether these drugs show an inhibitory potency against amyloid formation in internal organs and prevent the development of AA amyloidosis in mice.

## MATERIALS AND METHODS

### Animals

A total of 92 C57BL/6 male mice (approximately 10–12 weeks old), body weight 20–30 g, were obtained from the Institute of Immunology (Vilnius, Lithuania) and acclimated for 5 days.

They were maintained in plastic cages (5–8 per cage) with rodent chow and tap water *ad libitum*. During the experiment, the animals were housed at a temperature of 20–22 °C, at 50–60% relative humidity with a 12-hour light / dark cycle. Throughout the study, the animals were cared for in accordance with the European Convention and Guide for the Care and Use of Laboratory Animals and with Lithuanian laws. All the mice were used with the approval of the Lithuanian Laboratory Animal Use Ethics Committee under the State Food and Veterinary Service.

### Substances and drugs

Experimental AA amyloidosis was induced by using the following inflammatory substances: vitamin-free casein (Sigma Chemical Co, Germany) and fibrin (Chemical Dynamics Corporation, USA). For the treatment of amyloidosis, the following anti-inflammatory drugs were used: prednisolone (Gedeon Richter, Hungary), diclofenac (Glaxo Wellcome, Great Britain), and sulfasalazine (KRKA, Slovenia).

### Amyloidosis induction

Experimental AA amyloidosis was induced using casein and fibrin solutions: the animals received subcutaneous injections of 12% vitamin-free casein in a 0.02 N NaOH solution 5 days a week and injections of 5% fibrin once a week for a period of 5 or 6 weeks (17). All the injections were performed between 9 and 11 a. m. and had a total volume of 0.5 ml each.

### Groups of animals and treatment schedules

Two experiments were performed and two treatment regime protocols (prophylactic and therapeutic) were used. The drugs were prepared *ex tempore* in saline solution and injected in a 0.5 ml solution into the stomach through a metal probe 5 times a week. The animals in both experiments were divided into four groups. The control group (group 1) received the saline solution without any treatment. The test groups were treated with diclofenac (dose: 1 mg/kg) and prednisolone (10 mg/kg) (group 2; D/P), diclofenac alone (1 mg/kg) (group 3; D), and sulfasalazine (100 mg/kg) (group 4; SSL).

In the first experiment (40 C57BL/6 mice), the treatment was started simultaneously with the first casein injection (day 0) and lasted 5 weeks. In the second experiment (52 mice), the treatment was started after 2 weeks of stimulation with inflammatory substances and lasted 4 weeks.

### Other investigations

The body weight of the animals was determined once a week. The animals were sacrificed after the last drug application. The erythrocyte and leukocyte counts (made using a Picoscale, Hungary) and the erythrocyte sedimentation rate (ESR) were determined for the blood. The internal organs were examined macroscopically and weighed with kidney, spleen and liver samples being taken for morphological analysis. The indices obtained were compared with the indices for normal (healthy) animals and control groups.

### Histopathology

The formalin-fixed spleen, kidney and liver specimens were divided into two pieces and embedded in paraffin. Duplicate sets of 5 µm-thick sections from each piece of tissue were mounted on glass slides. One set was stained with haematoxylin-eosin and Brachet for light microscopic examination to determine the inflammation scores (general inflammatory reaction, inflammatory cell infiltration) and hepatocytes necrosis. Each parameter was scored on a 0 to 3 point scale. Tubular edema, glomerulonephritis, and connective tissue areas (the latter was evaluated in percentages) were observed by microscope. The other set of slides was stained with Congo red according to Eastwood (18) and examined in polarized light with an Olympus BX51 microscope to assess the degree of amyloid deposition in the tissue. The method used to detect amyloid protein included the traditional Congo red staining; the main method for diagnosing amyloid A (AA) amyloidosis is limited in animals because it requires a large array of animal-specific anti-AA antibodies which are not commercially available (19). The histological grading of the amyloid was made semi-quantitatively using a scale of 0 to 3 according to the density of the amyloid masses seen under a microscope, where '–' means amyloid was absent (0), '±' traces of amyloid were observed (0.5), '+' minimal (1), '++' moderate (2), and '+++ (3) heavy (abundant) amyloid deposits were present. Two histopathologists independently analysed all the specimen sections.

### Statistical analysis

All data were expressed as mean  $\pm$  SEM. Statistical analysis was done using SPSS / PC software version 8.0 using t test statistics for continuous variables, and P values less than 0.05 were considered to be significant. A nonparametric Mann–Whitney U statistical test was applied to analyse histologically observed differences and amyloid deposits in internal organs. The effects of treatments were compared with controls.

## RESULTS

### 1. Prophylactic treatment of experimental amyloidosis with antirheumatic drugs

**Animals, organs, and laboratory features.** The weight of the animals varied between 20 and 30 g. No animals were lost in the group treated with D/P and two (20%) each in the control group and in the groups which received SSL and only D.

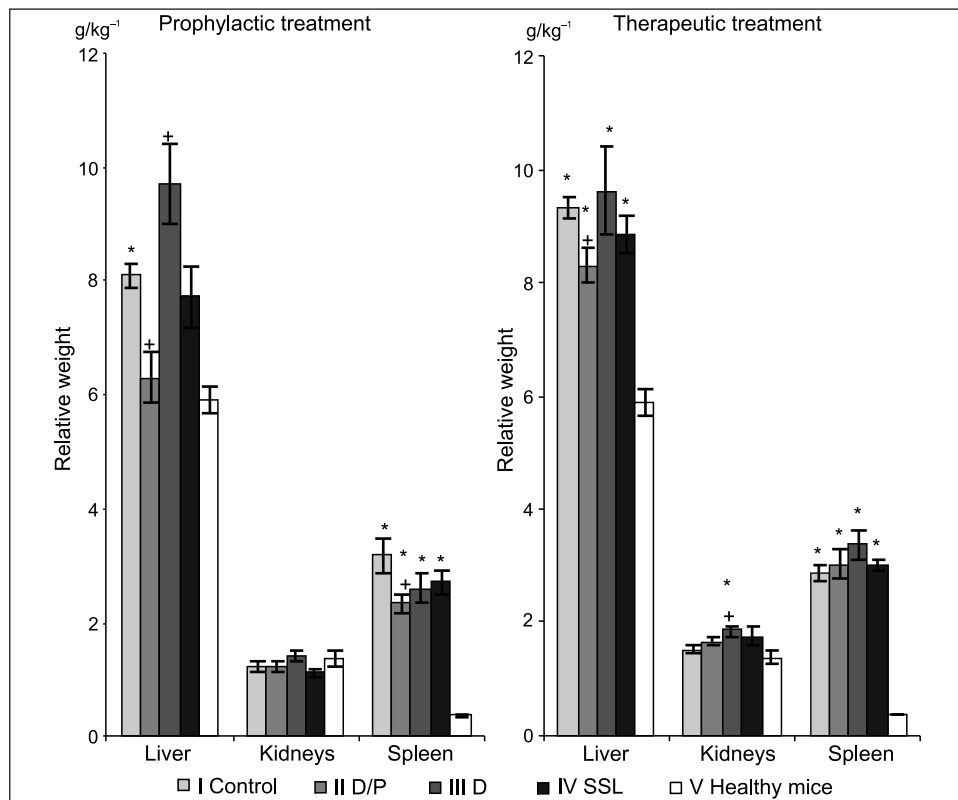
A post-mortem examination of the internal organs revealed splenomegaly ( $p < 0.001$ ) in all the groups in contrast to the healthy animals (Fig. 1). The absolute and relative

spleen weight was highest in the control group and lowest in the group treated with D/P. The absolute and relative weight of the liver also markedly increased in the control group and significantly differed from the healthy group and the group of animals treated with D/P. In the group which received D, the relative weight of the liver increased and was significantly higher than in the control group ( $p < 0.05$ ).

The blood indices (ESR, leukocytes, and erythrocytes) in all the groups were almost the same and differed significantly from those of the healthy animals (Fig. 2).

**Histological examination.** The frequency and extent of amyloid deposition and inflammatory lesions in various organs of the mice with experimental amyloidosis and treatment are summarized in Tables 1, 2 and shown in Figs. 3–5.

The amount of amyloid deposited in the spleen was significant in animals of the control group (Table 1, Fig. 3). Moderate (2+) and heavy (3+) deposits of perifollicular amyloid were observed in 12.5% and 87.5% of the animals, respectively (Table 2, Fig. 4C). An inflammatory reaction was observed in all the animals (Table 1); 87.5% of animals in the control group had multinuclear phagocytes and 100% had areas of



**Fig. 1.** Relative weight of organs in C57BL/6 mice with experimental amyloidosis prophylactically and therapeutically treated with antirheumatic drugs

Amyloidosis was induced by 0.5 ml subcutaneous injections of 12% casein solution 5 times a week and 5% fibrin solution once a week. Prophylactic treatment was started on day 0 and lasted five weeks. Therapeutic treatment was started after two weeks of stimulation with inflammatory substances and lasted four weeks. The drugs were administered by intragastric gavage 5 times a week. The 1st (control) group received 0.5 ml of saline solution, the 2nd diclofenac (dose: 1 mg/kg) and prednisolone (dose: 10 mg/kg) (D/P), the 3rd diclofenac (D) (dose 1: mg/kg), and the 4th sulfasalazine (SSL) (dose: 100 mg/kg). \* – the differences are significant between normal mice and the test groups. + – the differences are significant between the control group and the other test groups.

eosinophilic connective tissue around the follicles, which covered 25–50% of the spleen.

The majority of the mice in the control group had either 2+ (75%) or 3+ (25%) amyloid deposits in the liver (Table 2, Fig. 4D), and these deposits were also identified in the blood vessel walls (50% of animals) and pericollagenously (100%) (Table 1). Polymorphonuclear (PMN) infiltration of the liver was observed in all the tested animals.

Although amyloid was found in the kidneys in 87.5% of mice in the control group, its deposition was lower: 75% of the animals had traces of amyloid and 12.5% minimal deposits (Table 2). Amyloid was deposited predominantly in the

tubular basement membrane (87.5%) but occurred also in blood vessel walls (25%). Chronic renal lesions with glomerulonephritis were revealed in 87.5% of the mice, and 12.5% of animals had minimal glomerulonephritis (Table 1).

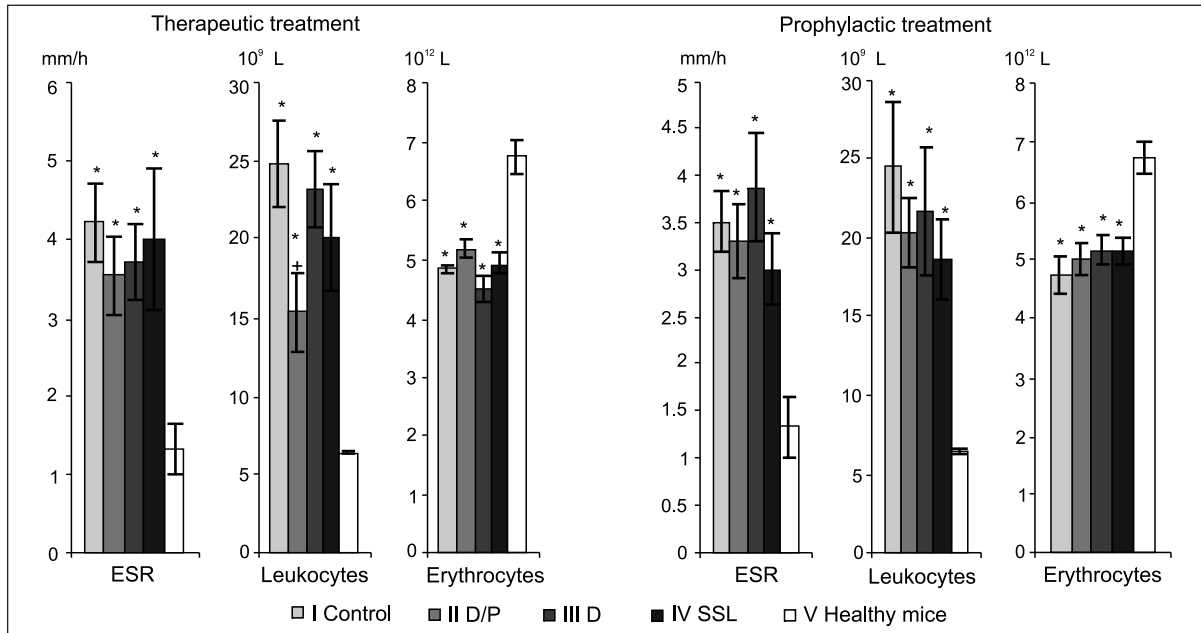
No positive effects of treatment with D could be seen on amyloid deposition in the spleen, kidneys, and liver (Tables 1, 2; Fig. 3).

However, the combination of D with P not only decreased the number of animals with amyloid deposits, but also significantly ( $p < 0.001$ ) suppressed (by 72.9%) amyloid formation in the spleen (Fig. 3). Only minimal (5 of 10 (50%) of the animals) and moderate (10%) amyloid deposits

Table 1. Pathomorphological changes and amyloid deposits (%) in the spleen, kidneys and liver of C57BL/6 mice with experimental amyloidosis treated with antirheumatic drugs

Organ		Prophylactic treatment				Therapeutic treatment					
		Groups				Groups					
		1st Control	2nd D/P	3rd D	4th SSL	1st Control	2nd D/P	3rd D	4th SSL		
Spleen	Connective tissue areas	n/n %	8/8 100	10/10 100	8/8 100	8/8 100	9/9 100	9/9 100	8/8 100	9/9 100	
	Multinuclear phagocytes	n/n %	7/8 87.5	10/10 100	8/8 100	8/8 100	9/9 100	9/9 100	8/8 100	9/9 100	
	Inflammatory reaction	n/n %	8/8 100	10/10 100	8/8 100	8/8 100	9/9 100	9/9 100	8/8 100	9/9 100	
	Amyloid	Perifollicularly	n/n %	8/8 100	4/10 40.0	8/8 100	8/8 100	9/9 100	6/9 66.7	8/8 100	9/9 100
		Blood vessel walls	n/n %	–	3/10 30.0	–	–	–	–	–	–
Kidneys	Minimal glomerulonephritis	n/n %	1/8 12.5	2/10 20.0	–	–	4/8*** 50	7/9+ 77.8	8/8**** 100	1/9*** 11.1	
	Glomerulonephritis	n/n %	7/8 87.5	4/10 40.0	5/8 62.5	–	3/8 37.5	–	–	1/9 11.1	
	Tubular edema	n/n %	–	10/10 100	5/8 62.5	7/8** 87.5	3/8 37.5	3/9 33.3	1/8 12.5	8/9 88.9	
	Amyloid deposits	n/n %	7/8 87.5	3/10 30.0	8/8 100	1/8 12.5	7/8 87.5	2/9 22.2	5/8 62.5	3/9 33.3	
	Amyloid deposit location	Blood vessel walls	n/n %	2/8 25	1/10 10.0	–	–	4/8 50	1/9 11.1	–	2/9 22.2
		Tubular base-ment membrane	n/n %	7/8 87.5	–	8/8 100	1/8 12.5	–	2/9 22.2	1/8 12.5	1/9 11.1
		Pericollagenous	n/n %	–	2/10 20.0	–	–	5/8 62.5	–	5/8 62.5	–
Liver	Inflammatory reaction (PMN/MMN)	n/n %	8/8 100	7/10* 70.0	8/8 100	8/8 100	9/9 100	9/9 100	8/8 100	9/9 100	
	Hepatocyte necrosis	n/n %	8/8 100	8/10* 80.0	8/8 100	8/8 100	9/9 100	7/9 77.8	8/8 100	9/9 100	
	Amyloid deposits	n/n %	8/8 100	8/10 80.0	8/8 100	7/8 87.5	9/9 100	5/8 62.5	7/8 87.5	9/9 100	
	Amyloid deposit location	Blood vessel walls	n/n %	4/8 50	8/10 80.0	8/8 100	3/8 37.5	7/9 77.78	1/8 12.5	6/8 75	5/7 55.5
		Pericollagenously	n/n %	8/8 100	5/10 50.0	8/8 100	7/8 87.5	9/9 100	5/8 62.5	7/8 87.5	9/9 100

Note: D/P – diclofenac (1 mg/kg) and prednisolone (10 mg/kg), D – diclofenac (1 mg/kg), SSL – sulfasalazine (100 mg/kg). PMN – polymorphonuclear infiltrates, MMN – monomorphonuclear infiltrates (lymphocytes, plasma cells, and macrophages). n / n – number of animals with organ changes / total number of animals investigated. % – percentage of animals with changes in organs and with amyloid deposits. Prophylactic treatment: \* – very small focal PMN and very small necrotic foci; + – amyloid in glomerulus; \*\* – 50% slight tubular edema, 25% moderate tubular edema, and 12.5% heavy tubular edema. Therapeutic treatment: + – very slight glomerular changes, \* – very slight increase in the mesangium, \*\* – a slight increase in the mesangium, ++ – focal glomerular sclerosis, \*\*\* – damage to the glomerulus (homogenization, thinning of the capillary walls, partial obstruction, dystrophy, an enlarged mesangium, and decreased cellularity).

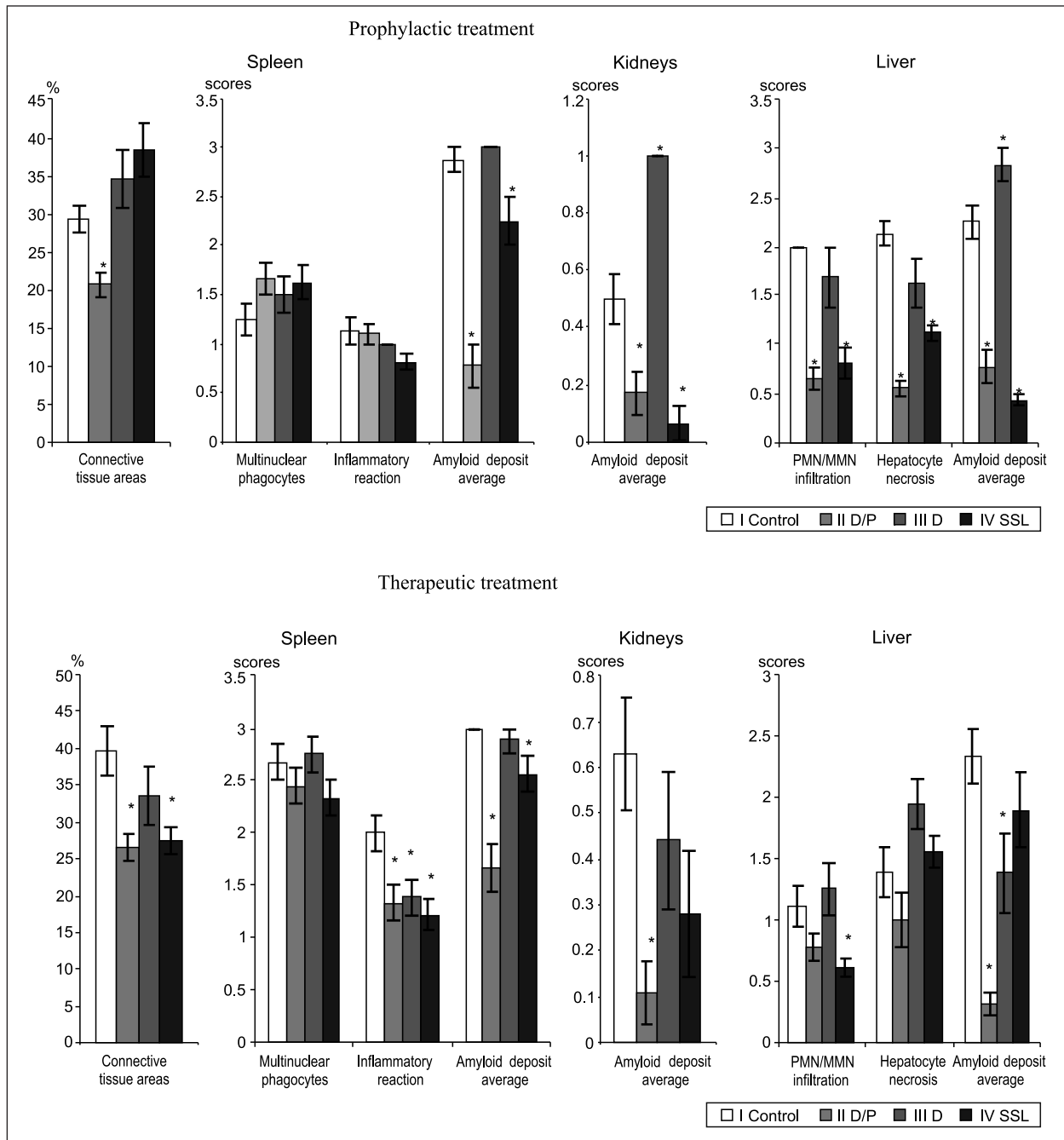


**Fig. 2.** Blood indices in C57BL/6 mice with experimental amyloidosis prophylactically and therapeutically treated with antirheumatic drugs  
 Amyloidosis was induced by 0.5 ml subcutaneous injections of 12% casein solution 5 times a week and 5% fibrin solution once a week. Prophylactic treatment was started on day 0 lasted for five weeks. Therapeutic treatment was started after two weeks of stimulation with inflammatory substances and lasted four weeks. The drugs were administered by intragastric gavage 5 times a week. The 1st (control) group received 0.5 ml of saline solution, the 2nd diclofenac (dose: 1 mg/kg) and prednisolone (dose: 10 mg/kg) (D/P), the 3rd diclofenac (D) (dose: 1 mg/kg), and the 4th sulfasalazine (SSL) (dose: 100 mg/kg). \* – the differences are significant between normal mice and the test groups. + – the differences are significant between the control group and the other test groups.

**Table 2.** Amyloid induction in the spleen, kidneys and liver of C57BL/6 mice with experimental amyloidosis treated with antirheumatic drugs

Organ	Prophylactic treatment				Therapeutic treatment					
	Groups				Groups					
	1st Control	2nd D/P	3rd D	4th SSL	1st Control	2nd D/P	3rd D	4th SSL		
Spleen	Traces (±)	n/n %	-	-	-	-	-	-	-	
	Minimal (+)	n/n %	-	5/10 50.0	-	1/8 12.5	4/9 44.4	-	-	
	Moderate (++)	n/n %	1/8 12.5	1/10 10.0	-	4/8 50	1/9 11.1	1/8 12.5	4/9 44.4	
	Heavy (++++)	n/n %	7/8 87.5	-	8/8 100	3/8 37.5	9/9 100	1/9 11.1	7/8 87.5	5/9 55.6
Kidneys	Traces (±)	n/n %	6/8 75	3/9 30.0	-	1/8 12.5	4/8 50	2/9 22.2	3/8 37.5	1/9 11.1
	Minimal (+)	n/n %	1/8 12.5	-	8/8 100	-	3/8 37.5	-	2/8 25	2/9 22.2
	Moderate (++)	n/n %	-	-	-	-	-	-	-	-
	Heavy (++++)	n/n %	-	-	-	-	-	-	-	-
Liver	Traces (±)	n/n %	-	6/10 60.0	-	7/8 87.5	5/8 62.5	-	-	
	Minimal (+)	n/n %	-	2/10 20.0	-	-	1/9 11.1	-	4/8 50	4/9 44.4
	Moderate (++)	n/n %	6/8 75	1/10 10.0	1/8 12.5	-	4/9 44.4	-	2/8 25	2/9 22.2
	Heavy (++++)	n/n %	2/8 25	-	7/8 87.5	-	4/9 44.4	-	1/8 12.5	3/9 33.3

**Note:** D/P – diclofenac (1 mg/kg) and prednisolone (10 mg/kg), D – diclofenac (1 mg/kg), SSL – sulfasalazine (100 mg/kg). n / n – number of animals with amyloid deposits / total number of animals investigated. % – percentage of animals with amyloid deposits.



**Fig. 3.** Pathomorphological changes and average amyloid deposits in internal organs of C57BL/6 mice with experimental amyloidosis prophylactically and therapeutically treated with antirheumatic drugs

Amyloidosis was induced by 0.5 ml subcutaneous injections of 12% casein solution 5 times a week and 5% fibrin solution once a week. Prophylactic treatment was started on day 0 and lasted five weeks. Therapeutic treatment was started after two weeks of stimulation with inflammatory substances and lasted four weeks. The drugs were administered by intragastric gavage 5 times a week. The 1st (control) group received 0.5 ml of saline solution, the 2nd diclofenac (dose: 1 mg/kg) and prednisolone (dose: 10 mg/kg) (D/P), the 3rd diclofenac (D) (dose: 1 mg/kg), and the 4th sulfasalazine (SSL) (dose: 100 mg/kg). \* – the differences are significant between control and the test groups.

(Table 2, Fig. 4A) were found perifollicularly (40% of mice) and in blood vessel walls (30%). Treatment with SSL also significantly (by 21.9%) suppressed amyloid formation in the spleen ( $p < 0.05$ ) (Fig. 3).

The same effect after prophylactic treatment in the kidneys was observed, where amyloid was absent in most of

the animals of the groups that received D/P and SSL, or only traces of amyloid were found (30% and 12.5% respectively), deposited in blood vessel walls (10%) and pericollagenously (20%) in the first case and in the tubular basement membrane (12.5%) in the second case. The D/P combination suppressed amyloid deposits in the kidneys by 66.0% ( $p < 0.02$ )



and SSL by 87.4% (Fig. 3). The pathological process in the kidneys was also lower in these groups than in the control group (Table 1, Fig. 3).

Although the number of animals with amyloid deposits in the liver did not decrease, the amyloid deposition was lower (by 65.3%; Fig. 3) after treatment with D/P: 70% of the animals had traces of amyloid, 20% minimal deposits, and 10% moderate deposits (Table 2, Fig. 4B). Amyloid was identified in blood vessel walls (80%) and pericollagenously (50%) (Table 1).

A more pronounced inhibitory effect (77.8% in comparison to the control group) on amyloid deposition in the liver was obtained by using SSL ( $p < 0.001$ , Fig. 3). Only traces of amyloid were found in 87.5% of animals (Table 2).

The D/P combination significantly decreased the connective tissue areas in the spleen ( $p < 0.007$ ), the polymorphonuclear (PMN) infiltration of the liver ( $p < 0.001$ ), and hepatocyte necrosis (by 72.4%;  $p < 0.001$ ; Fig. 3). Only very small focal PMN (Table 1) and very small necrotic foci were found in the hepatocytes using this treatment (Table 1).

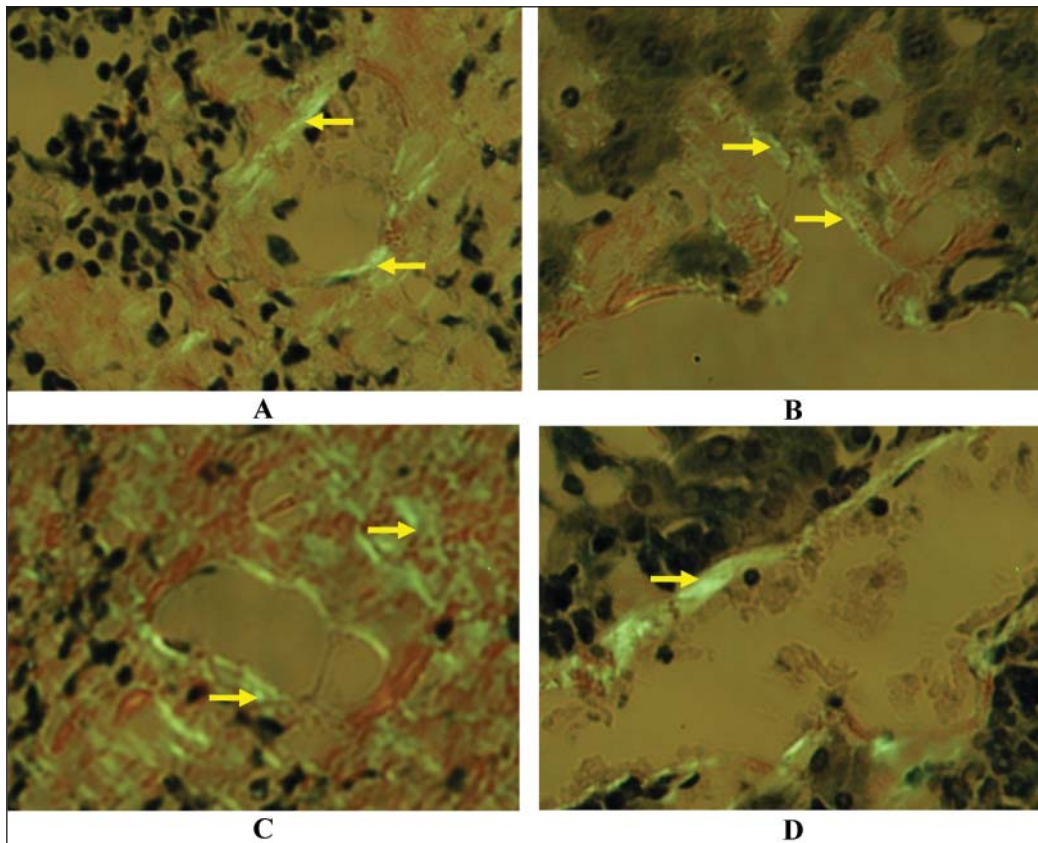
In the groups treated with D/P and D alone, glomerulonephritis was found in 40% and 66.7% of the animals, respectively.

Although treatment with SSL increased the connective tissue areas in the spleen ( $p < 0.04$ ), it markedly decreased PMN infiltration of the liver (by 59.5%;  $p < 0.001$ ) and hepatocyte necrosis (by 47.4%;  $p < 0.001$ ) (Fig. 3). Glomerulonephritis was not found in any animal of this group, but tubular edema developed in 87.5% of the animals (50% very slight, 25% moderate, and 12.5% notable) (Table 1).

Thus, both the D/P combination and SSL seem to be efficacious in the prophylactic treatment of experimental AA amyloidosis. D/P was more effective than D alone and more effective than SSL in inhibiting amyloid deposition in the spleen, but SSL was more effective with amyloid formation in the kidneys and liver. Prophylactic treatment of AA amyloidosis with D/P and SSL significantly improved this disorder and did not produce any side effects during the whole experiment.

## 2. Therapeutic treatment of experimental amyloidosis with antirheumatic drugs

**Animals, organs, and laboratory features.** In the control group and the groups treated with D/P and SSL, 30.8% of animals (4 of 13) were lost during the experiment. The mortality of animals (5 of 13) in the D group was 38.5%.



**Fig. 4.** Amyloid deposits in C57BL/6 mice with experimental AA amyloidosis prophylactically treated with diclofenac and prednisolone (D/P)

Minimal amyloid deposits in the spleen (A) and liver (B) of mice treated with D/P. Heavy deposits in the spleen (C) and liver (D) of the control group mice. Stained with Congo red acid solution,  $\times 200$ .

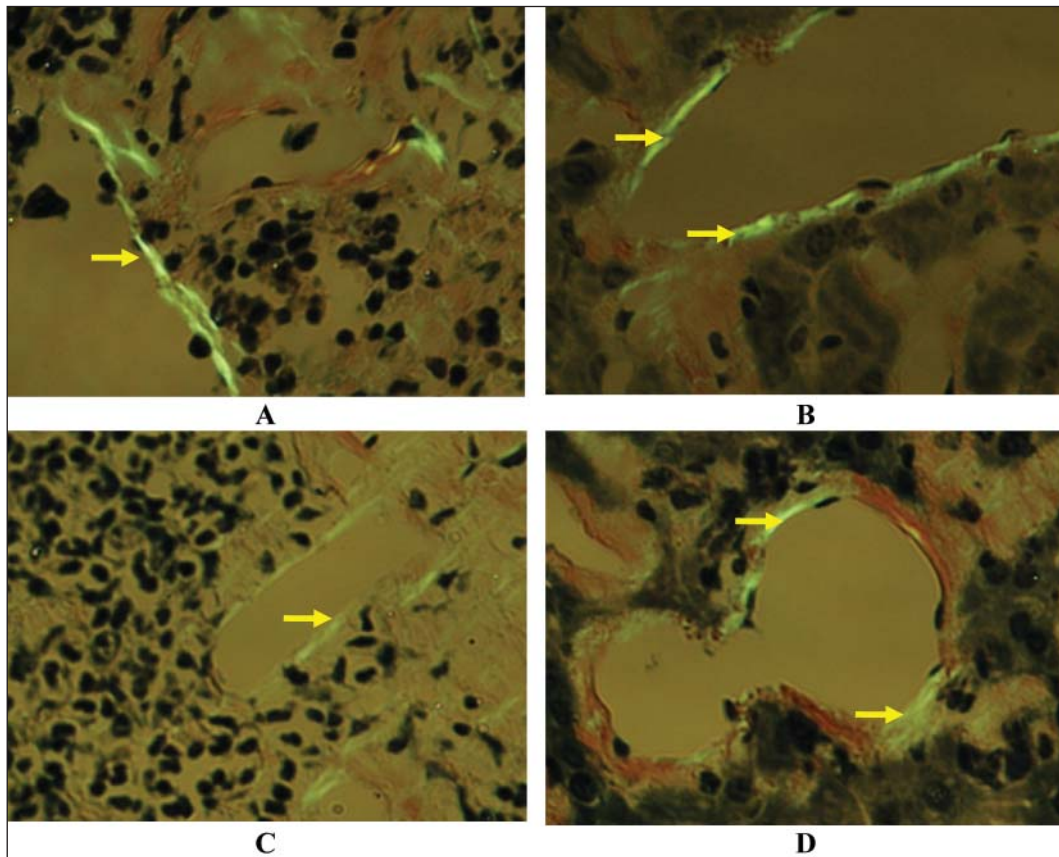


Fig. 5. Amyloid deposits in C57BL/6 mice with experimental AA amyloidosis following therapeutic treatment with D/P and sulfasalazine (SSL)

Moderate and minimal deposits in the spleen and liver of the mice treated with SSL (A, B respectively) and D/P (C, D). Stained with Congo red acid solution,  $\times 200$ .

The average body weight at the end of the experiment was significantly lower in all the test groups in comparison to the healthy animals (Fig. 1). The absolute and relative liver weight was the highest in the control group and significantly differed from those of the healthy animals ( $p < 0.01$  and  $p < 0.001$ ). The relative weight of the liver and the absolute and relative weight of the spleen of all the test groups were also significantly higher than those of the healthy animals, but treatment with D/P decreased the relative weight of the liver ( $p < 0.002$ ) in comparison to the control group.

The absolute weight of kidneys in the test groups did not differ from that in the control group and healthy animals, but the relative weight increased markedly in the group of animals treated with D ( $P < 0.01$ ).

Changes in the blood indices, such as the ESR and the leukocyte and erythrocyte counts, were worse compared to the healthy animals (Fig. 2). The highest ESR and leukocyte counts were observed in the control group. Treatment with D/P significantly reduced the leukocyte count ( $p < 0.05$ ) in comparison to this group.

**Histological examination.** Injections of inflammatory substances during 42 days induced a strong amyloidosis in the animals of the control group. Heavy (3+) amyloid depos-

its, identified perifollicularly, were revealed in 100% of the mice (Tables 1, 2; Fig. 3). An inflammatory reaction as well as areas of connective tissue and multinuclear cells in the spleen were found in all the animals of this group (Table 1).

All the control animals had minimal (11.1%), moderate (44.4%), and heavy (44.4%) hepatic amyloid deposits in the blood vessel walls (77.8% of mice) and pericollagenously (100%) (Tables 1, 2). Inflammatory polymorphonuclear and monomorphonuclear infiltration (PMN / MMN) as well as hepatocyte necrosis were seen in 100% of the animals.

Although amyloid was found in the kidneys of 87.5% of the mice, its deposition was lower: 50% of the animals had traces of amyloid and 37.5% had minimal deposits (Table 2). In 50% of cases, amyloid was found in the blood vessel walls and in 62.5% pericollagenously.

Glomerulonephritis and tubular edema developed in 37.5% of the mice, and minimal glomerulonephritis accompanied with glomerular lesions (homogenization, thickening of capillary walls, complete obstruction, dystrophy, an enlarged mesangium, and decreased cellularity) was found in 50% of the control group animals (Table 1).

Although treatment of experimental AA amyloidosis with D and SSL did not reduce the number of animals with



amyloid deposition in the spleen, its manifestation was lower (Tables 1, 2; Fig. 3). Moderate (2+) amyloid deposits in 12.5% and 44.4% of the mice and heavy (3+) ones in 87.5% and 55.6% of the animals were found after treatment with D and SSL, respectively (Table 2).

Combined therapy with D/P decreased the manifestation of amyloid and the number of animals with perifollicular amyloid deposits (Table 1). Amyloid was identified in 66.7% of animals. Moderate and heavy deposits of amyloid were observed in 11.1% and minimal in 44.4% of the mice treated with D/P (Table 2, Fig. 5C). Average amyloid deposition in the spleen was significantly lower than in the control group after treatment with D/P and SSL (Fig. 3, 5 A, C;  $p < 0.001$ ;  $p < 0.03$ ), which was especially obvious in the D/P group (44.3% suppression) (Fig. 3, 5C).

All the test drugs significantly reduced the inflammatory reaction in the spleen ( $p < 0.05$ – $0.01$ ), while D/P and SSL markedly decreased the areas of connective tissue in comparison to the control group ( $p < 0.006$  and  $p < 0.012$ , respectively).

The same inhibition of amyloid deposits after treatment was observed in the kidneys, where D/P suppressed the average formation of amyloid by 82.5% ( $p < 0.006$ ) (Fig. 3). In most cases amyloid was absent (7 of 9 mice) or only traces of amyloid (22.2%) were identified in the blood vessel walls (11.1% of mice) and tubular basement membranes (22.2% of mice). SSL inhibited amyloid formation by 55.5%, such formations being found in 33.3% of mice (11.1% traces and 22.2% minimal deposits) (Table 2, Fig. 3).

D insignificantly reduced amyloid formation in the kidneys. Traces of amyloid and minimal deposits in blood vessel walls and tubular basement membranes were found in 62.5% of mice treated with D.

Glomerulonephritis was absent in animals treated with D/P and D, but minimal glomerulonephritis with a slight enlargement of the mesangium, focal glomerular necrosis, and tubular edema was found respectively in 100% and 12.5% of mice treated with D (Table 1).

Minimal glomerulonephritis with slight glomerular changes in the first case and focal glomerular necrosis in the second was observed respectively in 77.8% and 11.1% of the D/P and SSL treated groups; 11.1% of mice (1 of 9) treated with SSL had glomerulonephritis and 88.9% tubular edema. The latter was found in only 33.3% of animals treated with D/P (Table 1).

The highest suppression (by 86.7%,  $p < 0.001$ ) of amyloid deposits in the liver was observed after treatment with D/P (Fig. 3, 5D). Traces of pericollagenous amyloid were found in 62.5% of the animals (Table 2).

A significant decrease in deposits in the liver was also obtained using D (40.8% suppression;  $p < 0.03$ ), but their manifestation was much stronger than in the D/P group. 87.5% of the animals had amyloid in the blood vessel walls (75%) and pericollagenously (87.5%), minimal, moderate, and heavy deposits being identified in 50%, 25%, and 12.5% of mice, respectively

(Table 1, 2; Fig. 3). Minimal and moderate amyloid deposits in the liver of mice treated with SSL are shown in Fig. 5B.

Treatment with D/P and SSL decreased inflammatory PMN/MMN infiltration (by 33.6% and 44.2%), but significant changes were observed after treatment with SSL ( $p < 0.01$ ) (Fig. 3). Only combined D/P treatment suppressed focal hepatocyte necrosis by 28% in comparison to the control group.

Thus, therapeutic treatment of experimental amyloidosis with a D/P combination showed the most expressed inhibitory effect on amyloid formation in all test organs. D alone significantly decreased amyloid deposits only in the liver. The positive suppressive effect was also observed by using SSL, especially on amyloid formation in the spleen.

## DISCUSSION

The AA amyloidosis associated with chronic inflammatory diseases is relatively rare but important, because the diagnosis is often difficult, the prognosis is poor, and no known specific effective therapy for the disease exists at the present time (5). It can potentially complicate any disorder associated with a sustained acute phase response, but in the developed world chronic rheumatic diseases have been asserted to be the most frequent predisposing conditions for the development of AA amyloidosis (5, 6, 20).

We selected casein and fibrin-induced amyloidosis in C57BL/6 mice on the basis of our earlier studies (17). It is a suitable model for investigating and understanding the pathogenesis of amyloidosis, representing an equivalent to human secondary amyloidosis.

The tests showed that, induced in this way, the pathological process caused a distinct amyloid deposition in the internal organs of control mice. Examination by polarizing microscopy of Congo red-stained section revealed the presence of varying amounts of amyloid deposits in one or more tissues of mice; most affected were the spleen and the liver, and to a lesser extent, the kidneys. The data presented here showed that the inflammatory substances also cause an increase in spleen and liver weight and make the blood indices worse.

In the mouse model, the primary site for amyloid deposition is the spleen is followed by deposits in liver; if the kidneys are engaged this happens at a much later time point (12).

It should be noted that the spleen showed the strongest reaction to the pathological process due to the splenomegaly and heavy amyloid deposits that occurred in all the animals. The spleen is a primary target for AA fibril deposition in animals like mice (21). The largest AA deposits occur around the splenic lymphoid follicles (22), revealed also by our data (17). Amyloidogenic stimulation in casein-induced amyloidogenesis enhances the synthesis of proteoglycans, which is related to splenic murine reactive AA amyloid and precedes amyloid fibril formation.

The liver also distinctly reacted to the pathological process. Its absolute and relative weight was the highest in the control groups, and the amyloid deposits were extensive.

Glomerulonephritis and tubular edema were observed in the kidneys. The inflammatory process damages the glomerulus, resulting in a thickening of the glomerular basement membrane, cellular proliferation within the mesangium, hyalinization, sclerosis, and glomerular death (23).

The abundance of basement membrane glycosaminoglycan in the glomerulus is the main factor in renal AA deposition (24) since this component is important in forming the typical  $\beta$ -sheet when AA fibrils are encountered. However, this does not exclude the possibility that increased apoptosis in renal T cells plays a causative role for renal amyloidosis (24).

Three categories of medications used in RA therapy – nonsteroidal anti-inflammatory drugs (NSAIDs), disease-modifying antirheumatic drugs (DMARDs), and corticosteroids – were studied for the treatment of experimental amyloidosis. The NSAID group was represented by diclofenac (D), corticosteroid preparations by prednisolone (P), and the DMARD group by sulfasalazine (SSL). In our experiments, one group of mice with experimental amyloidosis received a combination of D and P, because in practice many patients with RA are treated with low-dose corticosteroids, often in combination with other antirheumatic drugs.

It is known that the mechanism for NSAID action inhibits cyclooxygenase (COX-1 and COX-2) (25). COX-2 expression is induced, particularly during the inflammatory process (26). Diclofenac, one of the most widely used NSAIDs, is genuinely of a broad spectrum, having a similar inhibitory action on both the enzyme's isoforms (27). Its relative selectivity for COX-2 vs COX-1 for D is 0.45–1.43. Among standard NSAIDs, it has the most favourable profile (28) and produces its analgesic effect by actions at the inflammation locus.

However, in our study, single D therapy was not satisfactory in the treatment of experimental amyloidosis. Administration of D at 1 mg/kg during five weeks produced an increase in pathomorphological changes in the spleen and showed no positive effect on amyloid deposition in all the investigated organs. Shorter D treatment suppressed the splenic inflammatory reaction and significantly decreased only hepatic amyloid formation. But it should be noted that the abnormalities observed macroscopically and histologically in the kidneys and liver were more frequently revealed in the D group than in the other treated groups. Although NSAIDs are generally well tolerated, they are associated with a spectrum of potential clinical toxicities (25). Nephrotoxicity is a clinically important NSAID side effect (29). Some alterations of renal function are COX-2-related mechanism-based effects (30). Besides interstitial nephritis as well as nephrotic and end stage renal disease, which all occur rarely, the most common side effect is a decrease in renal function, which is caused by a reduction in renal blood flow. It was shown that chronic treatment with NSAIDs may result in COX-2 mobilization where COX-2 is either not translocated efficiently into the lumen of the nuclear envelope (endoplasmic reticulum) or loses its high affinity for the membrane (31). COX-2, but

not COX-1, was highly induced by diclofenac (32), and this induction was dose-dependent (31).

Although the administration of D had no effect on the development of experimental amyloidosis, the D/P combination was active in suppressing this process. Both treatment protocols caused the most significant inhibitory effect on splenic amyloid formation. However, the prophylactic treatment showed the greatest reducing effect on spleen weight and was more effective in decreasing amyloid deposits (by 72.9%, whereas therapeutic treatment reduced the deposits by 44.3% compared to the control group). Both treatments decreased the areas of eosinophilic connective tissue and inflammatory reaction in the spleen and improved the blood indices.

The same effect was observed in the kidneys and liver, but a distinct inhibitory effect on amyloid formation was revealed with the therapeutic treatment. Both treatments significantly reduced the relative weight of the liver and suppressed inflammatory PMN infiltration and hepatocyte necrosis. The inhibitory effect on the latter was obvious with the prophylactic treatment. Cases of glomerulonephritis also decreased after the treatment. All these events showed the positive effect of D/P.

It should be noted that steroid treatment was tested on human and animal AA amyloidosis, but the results were contradictory and the success limited. However, Shtrasburg et al. (33) showed that hydrocortisone suppressed the second phase of murine amyloidosis. It could be related to our results in which the combination of P and D suppressed the amyloid deposits in the internal organs of the mice. Corticosteroids are also known to be effective inhibitors of COX-2 (34).

The ability of antirheumatic drugs to lower the levels of acute-phase proteins which are important for the development of amyloidosis were reported. In animal models and in humans, it has been shown that treatment with NSAIDs, corticosteroids, and sulfasalazine are associated with reduced levels of acute-phase proteins (35, 36) and the levels of certain cytokines that stimulate hepatocytes to synthesize C reactive protein (CRP) as well as serum amyloid protein A (SAA) (15), the precursor for protein AA in secondary amyloid fibrils. The production of acute-phase proteins by the liver is regulated by cytokines including IL-6, IL-1, and TNF $\alpha$  (37). The relationship between IL-6 levels and the levels of the acute-phase proteins is of interest since IL-6 is known to regulate the hepatic production of many acute-phase proteins (38). Some cytokines such as IL-1 also increased COX-2 activity (39).

Many antirheumatic drugs are capable of cytokine modulation (40, 41). Cytokine over-production, which is thought to be responsible for the acute-phase response in mice with amyloidosis, can be downregulated by prednisolone and other immunosuppressive drugs. Prednisolone reduced the expression of TNF- $\alpha$ , IL-1 $\beta$ , and IL-6 (42, 43). Both IL-6 and IL-1 $\beta$  upregulate the production of hyperalgesic prostaglandins, the former by mobilising arachidonic acid and the latter by inducing the expression of the cyclo-oxygenase-2 (COX-2) gene (44).

The prophylactic and therapeutic treatment of experimental amyloidosis with SSL had also a positive effect and significantly suppressed amyloid deposits in the spleen, although to a lesser degree than D/P. Prophylactic treatment reduced its deposition by 21.9% and therapeutic treatment by 15% in comparison with the control group. A distinct suppression of amyloid deposits was found in the kidneys (87.4%) and liver (80.4%) under the prophylactic treatment and by 55.6% and 18.9% respectively after the therapeutic treatment.

In respect to SSL, it is a slow-acting antirheumatic drug. Its action is associated with low toxicity, and SSL is commonly used in Europe as the DMARD of choice (45) in an early and mild disease (46). The metabolism of SSL is complex and, to some extent, genetically determined. The drug's action mechanism is not well understood, but it involves a decreased production of cytokines and a decreased proliferative response by the lymphocytes (47). Treatment with SSL was associated with a reduction in IL-1 $\alpha$ , IL-1 $\beta$ , and TNF $\alpha$  (35, 48) but not in sIL-2R (49) or IL-6 (35) concentrations, although the latter was not corroborated in another study (50). SSL also inhibits the binding of TNF $\alpha$  to its receptor (51).

A beneficial effect by salazosulfapyridine (SASP) in a patient with secondary renal amyloidosis was observed by Hidaka et al. (52). SASP was evidently effective for arthritis and improvement of renal function. It might have a beneficial effect on AA amyloidosis by suppressing inflammatory cytokines. AA protein is derived from SAA which is synthesized by the liver as a response to inflammatory cytokine (IL-1, IL-6 and TNF- $\alpha$ ) stimulation (8, 53, 54) where IL-6 is a key cytokine for AA amyloidosis induction (54, 55).

The results of our study indicate that treatment with SSL and D/P can significantly suppress amyloid deposition in a murine amyloidosis model. This therapy has been successful in the prophylactic and therapeutic treatment of murine amyloidosis. We suggest that the treatment causes a reduction in acute-phase proteins, and this reduction is associated with a decrease in plasma levels of proinflammatory cytokines. Thus, one clue to the clinical effect of the study drugs may be their ability to reduce the levels of proinflammatory cytokines, another clue being a reduction in COX-2 expression.

**In conclusion**, our experiments indicated a different development rate for experimental amyloidosis in various treatment groups of mice. The prophylactic and therapeutic combined treatment with D/P resulted in a significant improvement of disease symptoms and markedly reduced amyloid deposits in the spleen, kidneys, and liver. SSL therapy alone was more successful in the prophylactic treatment of experimental amyloidosis where it, more effectively than D/P, suppressed amyloid formation in the kidneys and liver. The information gleaned from such studies may be applied in the prevention and treatment of disorders associated with pathological amyloid deposition such as found in patients with rheumatoid arthritis.

Received 17 February 2010  
Accepted 19 February 2010

## References

1. Lachman HJ, Goodman HJ, Gilbertson JA, Gallimore JR, Sabin CA, Gillmore CA et al. Natural history and outcome in systemic AA amyloidosis. *N Engl J Med.* 2007; 356: 2361–71.
2. Grateou C, Jeru I, Rouaghe S, Cazeneuve C, Ravet N, Duquesnoy P et al. Amyloidosis and auto-inflammatory syndromes. *Curr Drug Targets Inflamm Allergy.* 2005; 4: 57–65.
3. Lundmark K, Westermark GT, Olsen A, Westermark P. Protein fibrils in nature can enhance amyloid protein A amyloidosis in mice: Cross-seeding as a disease mechanism. *PNAS.* 2005; 102(17): 6098–102.
4. Myllykangas-Lousujarvi R, Aho K, Kautiainen H, Hakala M. Amyloidosis in a nationwide series of 1666 subjects with rheumatoid arthritis who died during 1989 in Finland. *Rheumatology.* 1999; 38: 499–503.
5. Hawkins PN. Phenotypes and fibril types in systemic amyloidosis. *Clinicopathology of Amyloidosis. IX International Symposium on Amyloidosis; 2001 July 15–21; Budapest, Hungary.* P. 191.
6. Nakamura T. Clinical strategies for amyloid A amyloidosis secondary to rheumatoid arthritis. *Mod Rheumatol.* 2008; 18: 109–18.
7. Kisilevsky R, Ancsin JB. AA amyloidogenesis a progress report and possible future directions. *IX International Symposium on Amyloidosis; 2001 July 15–21; Budapest, Hungary.* P. 52–4.
8. Omoto M, Yokota T, Cui D, Hoshi Y, Kawano H, Gondo T et al. Inactivation of amyloid-enhancing factor (AEF): study on experimental murine AA amyloidosis. *Med Mol Morphol.* 2007; 40: 88–94.
9. Van der Hilst JCH, Kluge-Beckerman B, Bodar EJ, van de Meer JWM, Drenth JPH, Simon A. Lovastatin inhibits formation of AA amyloid. *J Leukoc Biol.* 2008; 83: 1295–9.
10. Westermark P, Lundmark K, Westermark GT. Fibrils from designed non-amyloid-related synthetic peptides induce AA-amyloidosis during inflammation in an animal model. *PLoS One.* 2009; 4(6): e6041.
11. Kisilevsky R. Anti-amyloid drugs: potential in the treatment of diseases associated with aging. *Drugs Aging.* 1996; 8(2): 75–83.
12. Sponarova J, Nystrom SN, Westermark GT. AA-amyloidosis can be transferred by peripheral blood monocytes. *PLoS One.* 2008; 3(10): e3308.
13. Yamada T, Murai T, Hanyu T, Miida T. Fibrate inhibits reactive AA-amyloidosis in mice. *IX International Symposium on Amyloidosis; 2001 July 15–21; Budapest, Hungary.* P. 163–4.
14. Livneh A, Zemer D, Langevitz P, Laor A, Sohar E, Pras M. Colchicine treatment of AA amyloidosis of familial Mediterranean fever. *Arthritis Rheum.* 1994; 37: 1804–11.
15. Husebekk A, Stenstad T. Experimental AA-Amyloidosis in mice is inhibited by treatment with the anti-rheumatic drug tenidap. *Scand J Immunol.* 1996; 43: 551–5.



16. Shtrasburg S, Pras M, Gal R, Salai M, Livneh A. Inhibition of the second phase of amyloidogenesis in a mouse model by a single-dose colchicine regimen. *J Lab Clin Med.* 2001; 138(2): 107–11.
17. Leonaviciene L, Povilenaite D, Bradunaite R, Vaitkiene D, Venalis A. Influence of dextran sulphate, fibrin, and ubiquitin on the development of casein-induced experimental AA amyloidosis in C57BL/6 mice. *Scand J Lab Anim Sci.* 2005; 32(2): 85–97.
18. Eastwood H, Cole KR. Staining of amyloid by buffered Congo red in 50% ethanol. *Stain Technol.* 1971; 46: 208–9.
19. Shtrasburg S, Gal R, Perl S, Koren R, Pras M, Livneh A. An ancillary tool for the diagnosis of animal AA amyloidosis. IX International Symposium on Amyloidosis; 2001 July 15–21; Budapest, Hungary. P. 71.
20. Wakhlu A, Krisnani N, Hissaria P, Aggarwal A, Misra R. Prevalence of secondary amyloidosis in Asian North Indian patients with rheumatoid arthritis. *J Rheumatol.* 2003; 30(5): 948–51.
21. Wien TN, Sorby R, Omtveldt LA, Landsverk T, Husby G. Kinetics of proteoglycans and glycosaminoglycans in AA amyloidosis. IX International Symposium on Amyloidosis; 2001 July 15–21; Budapest, Hungary. P. 75.
22. Hutchinson WL, Herbert J, Botto M, Walport MJ, Pepys MB. AA amyloid deposition is complement independent. IX International Symposium on Amyloidosis; 2001 July 15–21; Budapest, Hungary. P. 39.
23. Grauer GF. New thoughts on proteinuria and management of glomerulonephritis. *Wild West Veterinary Conference;* 2002 Oct 9–13; Reno, NV. P. 1–6.
24. Mountz JD, Hsu HC. Clinical features associated with correction of T-cell senescence: increased acute-phase response, amyloidosis and arthritis. *Dev Comp Immunol.* 1997; 21(6): 509–23.
25. Bakowsky V, Hanly JG. COX-2 inhibition: not too hot, not too cold – (perhaps) just right? *J Rheumatol.* 2000; 27(12): 2734–7.
26. Pairet M, Engelhardt G. Distinct isoforms (COX-1 and COX-2) of cyclooxygenase: possible physiological and therapeutic implications. *Fundam Clin Pharmacol.* 1996; 10(1): 1–17.
27. McGeer PL. Cyclooxygenase-2 inhibitors: rationale and therapeutic potential for Alzheimer's disease. *Drugs Aging.* 2000; 17(1): 1–11.
28. Pairet M, van Ryn J. Experimental models used to investigate the differential inhibition of cyclooxygenase-1 and cyclooxygenase-2 by non-steroidal anti-inflammatory drugs. *Inflamm Res.* 1998; 47 (Suppl 2): S93–101.
29. Khan KN, Venturini CM, Bunch RT, Brassard JA, Koki AT, Morris DL et al. Interspecies differences in renal localization of cyclooxygenase isoforms: implications in nonsteroidal antiinflammatory drug-related nephrotoxicity. *Toxicol Pathol.* 1998; 26(5): 612–20.
30. Crofford LJ. Clinical experience with specific COX-2 inhibitors in arthritis. *Curr Pharm Des.* 2000; 6(17): 1725–36.
31. Simmons DL, Botting RM, Robertson PM, Madsen ML, Vane JR. Induction of an acetaminophen-sensitive cyclooxygenase with reduced sensitivity to nonsteroid anti-inflammatory drugs. *Proc Natl Acad Sci USA.* 1999; 96(6): 3275–80.
32. Simmons DL, Wagner D, Westover K. Nonsteroidal anti-inflammatory drugs, acetaminophen, cyclooxygenase 2, and fever. *Clin Infect Dis.* 2000; 31 (Suppl 5): S211–8.
33. Shtrasburg S, Pras M, Pariente C, Gal R, Livneh A. Hydrocortisone suppresses the second phase of amyloidogenesis in a mouse model. In: Grateau G, Kyle RA, Skinner M, editors. *Amyloid and amyloidosis.* Boca Raton, London, New York, Washington: CRC Press; 2005. P. 256–7.
34. Masferrer JL, Reddy ST, Zweifel BS, Seibert K, Needleman P, Gilbert RS et al. *In vivo* glucocorticoids regulate cyclooxygenase-2 but not cyclooxygenase-1 in peritoneal macrophages. *J Pharmacol Exp Ther.* 1994; 270(3): 1340–4.
35. Danis VA, Franic GM, Rathjen DA, Laurent RM, Brooks PM. Circulating cytokine levels in patients with rheumatoid arthritis: results of a double blind trial with sulphasalazine. *Ann Rheum Dis.* 1992; 51(8): 946–50.
36. Geiger T, Jagher B, Pignat W, Tscherry B, Wiesenberg I. The influence of anti-rheumatic drugs on hepatic mRNA levels of acute-phase proteins in rats with adjuvant arthritis. *Agents Actions.* 1993; 38: C69–72.
37. Thorn CF, Lu ZY, Whitehead AS. Regulation of the human acute phase serum amyloid A genes by tumor necrosis factor-alpha, interleukin-6 and glucocorticoids in hepatic and epithelial cell lines. *Scand J Immunol.* 2004; 59: 152–8.
38. Kordula T, Rokita H, Koj A, Fiers W, Gaudie J, Baumann H. Effects of interleukin-6 and leukemia inhibitory factor on the acute phase response and DNA synthesis in cultured rat hepatocytes. *Lymphokine Cytokine Res.* 1991; 10(1–2): 23–6.
39. Ristimaki A, Garfinkel S, Wessendorf J, Maciag T, Hla T. Induction of cyclooxygenase-2 by interleukin-1 alpha. Evidence for post-transcriptional regulation. *J Biol Chem.* 1994; 269(16): 11769–75.
40. Franke S, Herrmann D, Hein G, Muller A, Stein G. Interleukin-6, soluble interleukin-2-receptor and soluble interleukin-6-receptor in sera of patients with rheumatoid arthritis: influences of disease activity and drug therapy. *Eur J Med Res.* 1997; 2(9): 401–6.
41. Dessein PH, Joffe BI. Suppression of circulating interleukin-6 concentrations is associated with decreased endothelial activation in rheumatoid arthritis. *Clin Exp Rheumatol.* 2006; 24(2): 161–7.
42. Rioja I, Bush KA, Buckton JB, Dickson MC, Life PF. Joint cytokine quantification in two rodent arthritis models: kinetics of expression, correlation of mRNA and protein levels and response to prednisolone treatment. *Clin Exp Immunol.* 2004; 137(1): 65–73.
43. Patten C, Bush K, Rioja I, Morgan R, Wooley P, Trill J et al. Characterization of pristane-induced arthritis, a murine model of chronic disease: response to antirheumatic agents, expression of joint cytokines, and immunopathology. *Arthritis Rheum.* 2004; 50(10): 3334–45.
44. Botting RM, Botting JH. Pathogenesis and mechanisms of inflammation and pain. *Clin Drug Invest.* 2000; 19(2): 1–7.



45. Boers M, Verhoeven AC, Markuse HM, van de Laar MA, Westhovens R, van Denderen JC et al. Randomised comparison of combined step-down prednisolone, methotrexate and sulphasalazine with sulphasalazine alone in early rheumatoid arthritis. *Lancet*. 1997; 350(9074): 309–18.
46. Jackson CG, Williams HJ. Disease-modifying antirheumatic drugs. Using their clinical pharmacological effects as a guide to their selection. *Drugs*. 1998; 56(3): 337–44.
47. Gardner G, Furst DE. Disease-modifying antirheumatic drugs. Potential effects in older patients. *Drugs Aging*. 1995; 7(6): 420–37.
48. Remvig L, Andersen B. Salicylazosulfapyridine (Salazopyrin) effect on endotoxin-induced production of interleukin-1-like factor from human monocytes in vitro. *Scand J Rheumatol*. 1990; 19(1): 11–6.
49. Crilly A, Madhok R, Watson J, Capell HA. Serum concentrations of soluble interleukin 2 receptor in patients with rheumatoid arthritis: effect of second line drugs. *Ann Rheum Dis*. 1993; 52(1): 58–60.
50. Watson J, Crilly A, Madhok R, Capell H, Sturrock R. IL-6 and soluble IL-2 receptor in rheumatoid arthritis patients treated with second line drugs. *Biochem Soc Trans*. 1992; 20(2): 138S.
51. Shanahan F, Niederlehner A, Carramanzana N, Anton P. Sulfasalazine inhibits the binding of TNF alpha to its receptor. *Immunopharmacology*. 1990; 20(3): 217–24.
52. Hidaka M, Ohsawa I, Endo M, Fujita T, Ohi H, Kanmatsuse K et al. Beneficial effect of salazosulfapyridine (SASP) in a patient with secondary renal amyloidosis. *Nippon Jinzo Gakkai Shi*. 1998; 40(7): 555–9.
53. Gottenberg JE, Merle-Vincent F, Bentaberry F, Allanore Y, Berenbaum F, Fautrel B et al. Anti-tumor necrosis factor alpha therapy in fifteen patients with AA amyloidosis secondary to inflammatory arthritides: a follow up report of tolerability and efficacy. *Arthritis Rheum*. 2003; 48(7): 2019–24.
54. Mihara M, Shiina M, Nishimoto N, Yoshizaki K, Kishimoto T, Akamatsu K. Anti-interleukin 6 receptor antibody inhibits murine AA-amyloidosis. *J Rheumatol*. 2004; 31(6): 1132–8.
55. Cronstein BN. A key mediator of systemic and local symptoms in rheumatoid arthritis. *Bull NYU Hosp Jt Dis*. 2007; 65 (Suppl 1): S11–5.

Laima Leonavičienė, Danutė Povilėnaitė, Rūta Bradūnaitė, Dalia Vaitkienė, Algirdas Venalis

## EKSPERIMENTINĖS AMILOIDOZĖS GYDYMAS PRIEŠREUMATINIAIS VAISTAIS

### *S a n t r a u k a*

**Darbo tikslas.** Kadangi antrinei amiloidozei kol kas dar netaikomas specifinis gydymas, šio tyrimo tikslas buvo įvertinti, ar priešreumatiniai vaistai slopina kazeinu ir fibrinu sukeltą eksperimentinę AA amiloidozę C57BL/6 pelėms.

**Medžiaga ir metodai.** Taikant monoterapiją sulfasalazinu (SSL) ir diklofenaku (D), taip pat kombinuotą gydymą diklofenaku su prednizolonu (D ir P), iširtas jų poveikis amiloido susidarymui, kai vaistai naudojami profilaktiškai ir terapiškai. Vaistai (D – 1 mg/kg, P – 10 mg/kg ir SSL – 100 mg/kg) buvo leidžiami į skrandį metaliu zondų 5 kartus per savaitę. Gydymo trukmė – 5 ir 4 savaitės. Atlikti pelių blužnies, inkstų ir kepenų histologiniai tyrimai. Kongo raudonuojų nudažytos amiloido sankaupos nustatytos poliarizuojančiu mikroskopu „Olympus BX51“.

**Rezultatai.** Tyrimo rezultatai rodo, kad profilaktinis gydymas D neturėjo ryškaus poveikio amiloido sankaupoms tiriamuose organuose, tuo tarpu D ir P kombinacija statistiškai reikšmingai mažino ligos simptomus ir ryškiai slopino amiloido sankaupas blužnyje, inkstuose ir kepenyse ( $p < 0,002$ – $0,001$ ). Profilaktiškai taikomas SSL statistiškai reikšmingai mažino amiloido sankaupas visuose su eksperimentine amiloidoze tirtuose pelių organuose ( $p < 0,004$ – $0,001$ ), tačiau ryškiausias slopinimas stebėtas inkstuose ir kepenyse ( $p < 0,006$ – $0,001$ ). Kombinuotas (D ir P) terapinis eksperimentinės amiloidozės gydymas slopino amiloido sankaupas vidaus organuose ( $p < 0,006$ – $0,001$ ), tačiau didžiausias jų slopinimas (86,7 %;  $p < 0,001$ ) nustatytas kepenyse. Gydant D statistiškai reikšmingai sumažėjo amiloido sankaupos kepenyse ( $p < 0,03$ ), o SSL – blužnyje ( $p < 0,03$ ).

**Išvados.** Tyrimo duomenimis, D ir P bei SSL slopina amiloidogenezę, ir šis slopinimas gali būti susijęs su priešreumatinėms vaistų priešuždegiminiu poveikiu. Nors minėti vaistai negali visiškai nuslopinti pelėms sukeltos ligos, tačiau jie gali padėti gydant reumatinę ligą, kai susidaro amiloidogeniniai dariniai.

**Raktažodžiai:** pelės, eksperimentinė AA amiloidozė, priešreumatiniai vaistai