

# Anti-inflammatory effects of *Aesculus hippocastanum* L. tincture and the pro-/antioxidant bodily state of rats with adjuvant arthritis

Audrius Vasiliauskas<sup>1</sup>,

Laima Leonavičienė<sup>1</sup>,

Dalia Vaitkienė<sup>2</sup>,

Rūta Bradūnaitė<sup>1</sup>,

Aloyza Lukšienė<sup>3</sup>

<sup>1</sup> State Research Institute,  
Centre for Innovative Medicine

<sup>2</sup> Faculty of Medicine,  
Vilnius University

<sup>3</sup> Institute of Oncology,  
Vilnius University,  
Vilnius, Lithuania

**Background.** Conventional therapies show only limited effects on rheumatoid arthritis (RA) and are helpful in controlling the symptoms, but in cases of chronic, prolonged RA they are unsatisfactory and associated with various side effects. So, the use of complementary / alternative medicine, predominantly herbal therapies, by sufferers of rheumatic diseases is highly prevalent and increasing. The aim of the study was to evaluate the anti-inflammatory effects of *Aesculus hippocastanum* L. (AH) tincture on the pro-/antioxidant bodily status in rats with adjuvant arthritis (AA).

**Materials and methods.** Fifty Lewis rats of both sexes were used. AA was induced in 40 animals by a single injection of 0.1 ml of complete Freund's adjuvant into the left hind paw. Body weight and the anti-inflammatory effects of AH, assessed by joint swelling, were determined three times a week in the control and test groups of animals. Daily oral administration of three different doses of AH (2.4, 4.8 and 9.5 mg/kg calculated to the dry weight of the tincture) were performed. At the end of the trial, blood indices, histological changes in the inflamed joints, oxidative products such as malondialdehyde (MDA), anti-oxidative enzyme catalase (CAT), superoxide dismutase (SOD) and total antioxidant activity (AOA) in the serum and gastric mucosa tissue homogenates were evaluated.

**Results.** Female rats treated with a middle dose (4.8 mg/kg) of AH tincture showed the lowest joint swelling, which significantly differed from the control AA group at the end of the experiment. The treatment improved the systemic parameters of the disease, such as blood indices and the weight of internal organs, showed no toxicity on the main organs and was selected for investigating the pro-/antioxidant indices of the blood serum and gastric mucosa homogenates. There were significant differences between sexes in terms of the pro-/antioxidant status of the serum. A lower MDA level and statistically significant AOA in female rats with AA were observed. Although the treatment lowered the MDA level and increased CAT activity in animals of both sexes, a significant difference remained between males and females: the latter showed a lower level of MDA and a higher CAT activity. Development of AA significantly increased the MDA level and decreased CAT activity, but only slightly affected SOD and AOA activity in gastric tissue homogenates. Their incubation with AH tincture had a positive effect, especially in female rats in which a significant decrease of MDA and a higher CAT activity were found in arthritic rats and elevated SOD activity in healthy rats. However, the pro-/antioxidant status of gastric tissue homogenates did not significantly differ between male and female rats.

**Conclusions.** The results of the study clearly indicate that AH may be beneficial due to its anti-inflammatory and anti-oxidant effects. The best effect was shown by the middle dose in female rats with AA. The *in vivo* anti-inflammatory and antioxidant effects of the herbal tincture may be the promising features for its prospective use as supplementary therapy beside the conventional treatment.

**Key words:** rats, adjuvant arthritis, pro-/antioxidant activity, herbal tincture

## INTRODUCTION

Rheumatoid arthritis (RA) is a well-known chronic autoimmune / inflammatory disease of unknown etiology, which affects several parts of the joints, including the cartilage and synovium, and leads to a progressive joint damage and destruction. RA is dependent on multiple interacting environmental and genetic factors, making it difficult to understand its pathogenesis and thereby to find effective therapies (1). In the treatment for this disease, the focus is on the reduction of pain, inflammation and joint damage. Despite the well-developed pharmaceutical industry and high technologies used for the production of various drugs, more and more researchers and clinicians turn their attention to the biologically active substances of herbs and their effectiveness in the treatment of rheumatic diseases, because most therapies have a moderate percentage of efficacy and a high incidence of side effects. Research indicates that in the United States 60–90% of patients suffering from arthritis, including RA, used complementary / alternative medicine (CAM), predominantly herbal therapies (2). The use of CAM by sufferers of rheumatic diseases is highly prevalent and increasing (3).

For centuries, horse chestnut (*Aesculus hippocastanum* L. (AH)) seeds, leaves, bark and flowers have been used for variety of conditions and disease. It is known that flowers and seeds of AH contain high amounts of bioflavonoids such as quercetin, kaempferol and their diglycosyl derivatives, as well as anti-oxidants, such as proanthocyanidin A<sub>2</sub> and the coumarins esculin and fraxin (4), as well as other biologically active compounds possessing an antioxidant effect, and therefore can positively influence the bodily oxidative system. Anti-oedemagenous, anti-exudative and vasoprotective activities of AH extracts are exclusively due to aescin (5) which has been shown to be effective in preventing the formation of oedema in models of inflammation that reproduce the initial exudative phase, but is not effective in preventing oedema in models of inflammation that reproduce the late proliferative phase, and in experimental models of polyarthritis (6). Studies have found that AH extracts have been used against chronic venous insufficiency, haemorrhoids and post-operative oedema, and are available in food supplements as the coumarin glucoside aesculus (7, 8).

Fruits of AH have been employed in the treatment of rheumatism and neuralgia and also in rectal complaints and for haemorrhoids. It is known that AH flowers contain esculamine which inhibits the development of inflammation (9).

In studies aimed to develop preventive agents against RA, the selection of experimental animals is very important. Adjuvant arthritis (AA) induced in rats is an animal model for the study of RA, because changes in the biological characteristics of AA rats correspond to those that occur in human RA (10, 11). Therefore, AA is a good model to evaluate the anti-inflammatory and anti-rheumatic effects of preparations (1, 12). It is known that RA is an autoimmune inflammatory disease where free radicals participate actively in all

kinds of inflammatory conditions and have been implicated in the genesis and perpetuation of damage in the joints of patients (13, 14) and experimental animals with arthritic disease (15, 16).

Our investigations concern the anti-inflammatory effect of herbal tinctures and changes in the pro-/antioxidant status of an organism during the development of autoimmune process in both sexes of Lewis rats with AA, because the relations between these parameters are not well established. It is very important to elucidate the mechanism by which the oral administration of AH appears to be a promising feature for its prospective use as a supplementary therapy of RA.

## MATERIALS AND METHODS

### Animals

Fifty female and male, seven-week old Lewis rats were purchased from the Institute of Immunology. Animals (five per cage) were housed under standard conditions (light–dark cycle of 12 hours, 20–22 °C room temperature, 50% humidity) and fed a commercial diet “Kėdainių grūdai” and water *ad libitum*. A one-week period of adaptation had been allowed before the experiments. The procedures followed the guidelines recommended by the EU for the care and use of laboratory animals. All animals were used with the approval of the Lithuanian Laboratory Animal Use Ethics Committee under the State Food and Veterinary Service.

### Materials and reagents

Complete Freund's adjuvant, 10% formalin, hematoxylin-eosin, picrofuxin, toluidine blue, methyl-green-pyronin-9, safranin O, thiobarbituric acid, orthophosphoric acid, nitrotetrasolium blue chloride, nitric acid, ferrous sulphate, ascorbic acid, ammonium molybdate, hydrogen peroxide, 1% Tween 80<sup>®</sup> were obtained from Sigma-Aldrich Chemie and Fluca Chemie GmbH (Germany), and Apaurin (diazepamum) from KRKA (Slovenia). To determine protein content in the samples, the commercial Kit B040 (Aqua Medica, Poland) was used.

### Arthritis induction and evaluation

Arthritis was induced in the rats by an intradermal injection of 0.1 ml of Freund's adjuvant into the plantar region of the left hind paw (day 0). Inflammation during the development of AA was assessed by measuring paw edema and polyarthritis development. Paw edema was assessed by measuring the paw volume by plethysmometry. Body weight and joint swelling were examined three times a week.

### AH tinctures and experimental groups

Ethanollic tinctures of *Aesculus hippocastanum* L. (AH) flowers were studied. The content of flavonoids in AH tincture was 1.88 g/100 ml. No toxic effects on the rats by using the maximal (1.55 g/kg) and repeated doses (5 mg/kg, 10 mg/kg, 20 mg/kg) on day 21 of the study were revealed (17) in the toxicity studies.

Five groups of animals were analyzed, each consisting of five female and five male rats. Group 1 was the control AA group in which complete Freund's adjuvant was applied for arthritis induction and sodium saline was administered as a placebo; groups 2, 3 and 4, were treated with 2.4 mg/kg/d., 4.8 mg/kg/d., and 9.5 mg/kg/d. of AH tincture, respectively. Group 5 consisted of healthy animals.

AH tinctures were administered orally to rats once a day starting on the day following adjuvant injection. The treatments was continued for 20 days after adjuvant injection.

### Blood and tissue collection

At the end of the experiment, on day 21 after adjuvant injection, rats were killed by decapitation. Trunk blood was collected in tubes, allowed to clot, centrifuged, and the serum was stored at  $-20^{\circ}\text{C}$  until further examination. The count of leukocytes and erythrocytes was determined with a Picoscale (Hungary) blood analyzer. ESR and macroscopic changes of the internal organs and joints were studied. Immediately after decapitation, internal organs such as liver, kidney, spleen, thymus and adrenal glands were weighed. The stomach was removed for histological observation and the biochemical investigation of gastric mucosa. Samples from the antral portion of stomach were frozen at  $-20^{\circ}\text{C}$  and kept for 3–7 days for the estimation of their biochemical parameters. The gastric mucosa was scraped, weighed and homogenized in an appropriate ice-cold phosphate buffer.

### Histological analysis

The ankles of adjuvant-injected paws were collected for histological examination. Ankle joints were fixed in 10% formalin. Following decalcification in 10% nitric acid ( $\text{HNO}_3$ ) and paraffin embedding, joint specimens were cut on a microtome at multiple levels. Histological sections were stained with hematoxylin-eosin (for visualization of cells), picrofuxin (for determination of fibrotic processes), toluidine blue (for visualization of proteoglycan loss and cartilage damage), methylgreen-pyronin-9 (plasmatisation), and safranin O (for evaluation of changes in the cartilage) and reviewed using light microscopy.

The histological assessment of inflammatory infiltration with lymphocytes, plasma cells, macrophages and granulocytes and other inflammatory symptoms in the synovium, soft periarticular tissues as well as evaluation of cartilage damage were performed in a blinded manner. A 4-point score (0–3) was used, where 0 indicates the absence of changes and 3 is the most severe expression of a particular symptom.

### Biochemical methods of investigation

*Measurements of malondialdehyde (MDA), the activity of catalase (CAT), superoxide dismutase (SOD), total antioxidant activity (AOA) and protein content*

The end product of lipid peroxidation (MDA), activity of antioxidant enzymes such as CAT, SOD and total antioxidant activity (AOA) were determined in the blood samples and

homogenates of gastric mucosa of the control and treated groups. To determine the indices of the mucosal oxidative system, gastric mucosal samples were homogenized in a buffered solution (10%,  $\text{pH} = 7.4$ ) with a glass homogenizer and centrifuged at 13 000 rpm for 15 min at  $4^{\circ}\text{C}$ . The dose of the herbal tincture was chosen experimentally. After 1 hour of incubation at  $37^{\circ}\text{C}$ , the homogenate (0.2 ml) was supplemented with the tincture (0.1 ml).

The content of MDA (expressed in nmol/mg of protein) was measured with 0.8% thiobarbituric acid in 2% solution of orthophosphoric acid according to the method described by Gavrilov and co-authors (18). CAT activity (expressed as nmol/L/min) was measured by the subsequent decomposition of 0.03% of hydrogen peroxide ( $\text{H}_2\text{O}_2$ ) in the presence of 4% solution of ammonium molybdate as described by Koro-liuk et al. (19). SOD activity (expressed as the activity units in mg of protein) was measured by using nitrotetrasolium blue chloride as described by Csovari et al. (20), and AOA (expressed as the percentage of reduction rate) was found by applying 1% Tween 80<sup>®</sup> and 0.25% thiobarbituric acid as described by Galaktionova et al. (21). The protein content of the samples was measured with a commercial Kit B040 (Aqua Medica, Poland).

### Statistical analysis

All statistical analyses were performed using a statistical software package, SPSS for Windows v. 13.0. Student's t-tests were used for a statistical comparison of two groups. Non-parametric statistical methods were chosen as the data distribution was found not to comply with the normal distribution. Data from independent groups were compared using the Mann–Whitney U test.

## RESULTS

### Joint swelling, polyarthritis development, and histopathology of joints

Figure 1 (A) illustrates the development of AA in rats treated with various doses of AH. A significant decrease of joint swelling at the end of the experiment was observed only in the female rats that received middle doses of AH.

Swelling of the injected limb began immediately, whereas swelling of the non-injected hind limb was more gradual and began after injection on day 13 in female and male (20% of animals with polyarthritis) non-treated rats; 100% of female and 60% of male rats had polyarthritis at the end of experiment (Fig. 1B). Treatment, especially with a middle dose of AH, decreased the number of animals who developed polyarthritis. In the groups treated with middle and high doses of AH, polyarthritis was observed in 60% of female and in 20% and 40% of male rats, respectively.

Histological examination of soft tissues surrounding the ankle joint in the control arthritic group showed a pronounced inflammatory infiltration with lymphocytes, leukocytes, macrophages, edema and angiomatosis (Table 1).

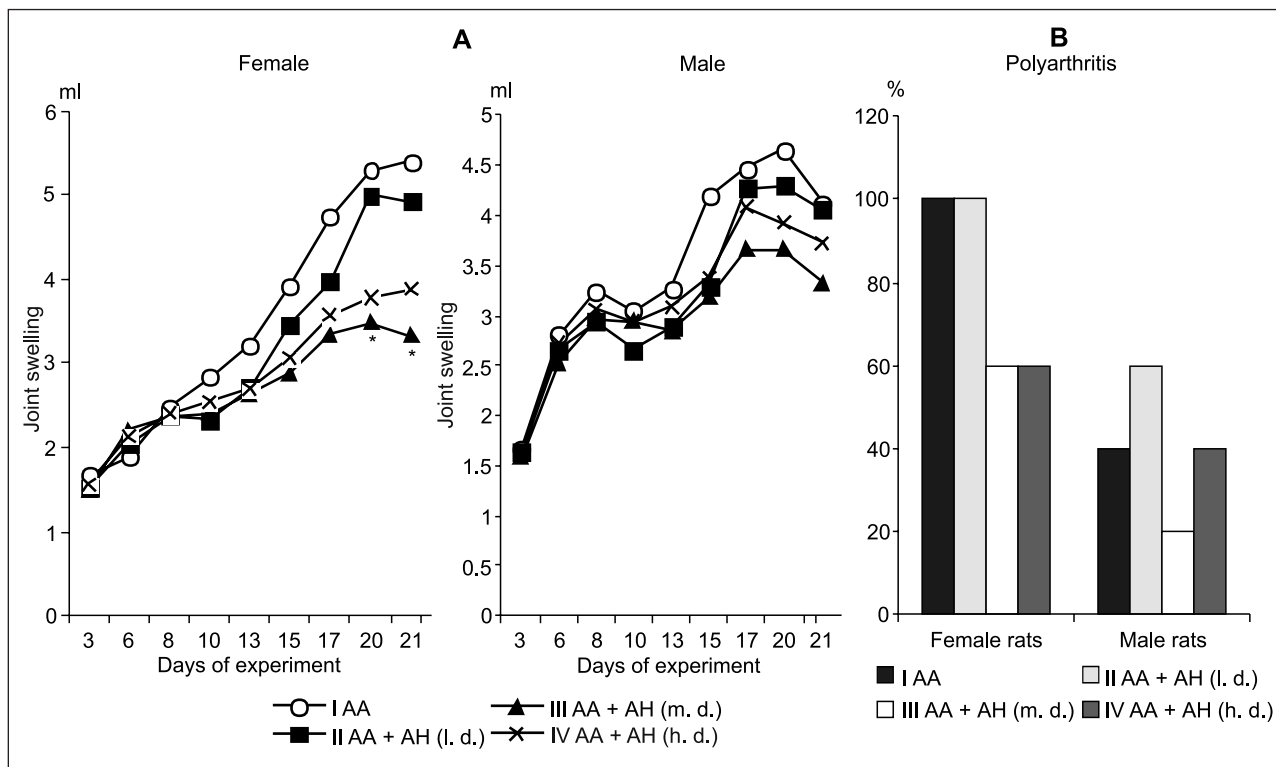


Fig. 1. Joint swelling (A) and development of polyarthritis (B) in Lewis rats with adjuvant arthritis (AA) treated with various doses of *Aesculus hippocastanum* L. (AH) tincture

AA was induced in 40 rats by the foot paw method by injecting 0.1 ml of complete Freund's adjuvant (CFA) into the left hind paw under light anaesthesia. Group 1 (control) – animals with induced AA. Group 2 – rats with AA treated with a low dose (2.4 mg/kg/d) of AH (l. d.). Group 3 – rats with AA treated with a middle dose (4.8 mg/kg/d) of AH (m. d.). Group 4 – rats with AA treated with a high dose (9.5 mg/kg/d) of AH (h. d.). \* The differences are significant in comparison with the control AA group

Table 1. Pathomorphological changes in joints of arthritic rats treated with *Aesculus hippocastanum* L. tincture

Index	Sex	Groups				
		1 (AA control)	2 (AA + AH) (2.4 mg/kg/d)	3 (AA + AH) (4.8 mg/kg/d)	4 (AA + AH) (9.5 mg/kg/d)	
Soft periarticular tissues	Inflammatory infiltration	Female	2.60 ± 0.24	1.90 ± 0.29	1.70 ± 0.12*	2.00 ± 0.22
		Male	2.50 ± 0.22	2.00 ± 0.16	1.70 ± 0.25*	1.90 ± 0.24
	Edema	Female	2.10 ± 0.10	1.20 ± 0.12*	1.20 ± 0.12*	1.30 ± 0.12*
		Male	2.00 ± 0.00	1.00 ± 0.00*	1.20 ± 0.12*	1.40 ± 0.10*
	Angiomatosis	Female	2.40 ± 0.19	1.20 ± 0.20*	1.20 ± 0.12*	1.40 ± 0.10*
		Male	2.10 ± 0.10	1.40 ± 0.10*	1.20 ± 0.12*	1.20 ± 0.20*
Synovium	Villous proliferation	Female	2.20 ± 0.20	1.20 ± 0.12*	0.90 ± 0.10*	0.80 ± 0.20*
		Male	2.00 ± 0.27	1.30 ± 0.12*	1.00 ± 0.00*	0.90 ± 0.10*
	Edema	Female	2.20 ± 0.20	0.80 ± 0.20*	0.80 ± 0.12*	0.70 ± 0.12*
		Male	2.00 ± 0.00	0.90 ± 0.19*	0.70 ± 0.12*	0.70 ± 0.12*
	Inflammatory infiltration	Female	2.40 ± 0.19	1.30 ± 0.30*	1.00 ± 0.16*	1.20 ± 0.25*
		Male	2.20 ± 0.12	1.60 ± 0.10*	1.00 ± 0.22*	1.00 ± 0.22*
Angiomatosis	Female	2.10 ± 0.33	1.20 ± 0.12*	1.00 ± 0.16*	1.10 ± 0.10*	
	Male	2.30 ± 0.25	1.10 ± 0.10*	0.80 ± 0.20*	1.00 ± 0.16*	
Cartilage	Usure	Female	1.60 ± 0.24	0.20 ± 0.20*	0.30 ± 0.20*	0.70 ± 0.34
		Male	1.00 ± 0.45	0.40 ± 0.24	0.40 ± 0.29	0.60 ± 0.40
	Pannus	Female	1.30 ± 0.20	0.70 ± 0.20	0.50 ± 0.31	0.50 ± 0.29
		Male	1.20 ± 0.37	0.60 ± 0.19	0.40 ± 0.24	0.50 ± 0.16

Note. Adjuvant arthritis (AA) was induced in 40 rats by the foot paw method by injecting 0.1 ml of complete Freund's adjuvant (CFA) into the left hind paw under light anaesthesia. Group I (control) – animals with induced AA. The next three groups – rats with AA treated daily with different doses of AH tincture. Group V – healthy animals. \* The difference is significant in comparison with the control AA group.



All doses of AH markedly decreased edema and angiomatosis, but a significantly lower general inflammatory infiltration (by 34.6% and 32%, respectively, in female and male rats) was observed after treatment with a middle dose of AH.

Synovium villous proliferation, edema, general inflammatory infiltration and angiomatosis were also significantly lower in the treated groups of animals, and in female rats the percentage of decrease in comparison with the control AA group was higher than in male rats, except angiomatosis which was lower in female rats.

Significant changes in the cartilage were also found only in female rats; in them, treatment with low and middle doses of AH decreased usures by 87.5% and 81.3%, respectively. Panus formation decreased, although no significant differences between the AA control and treated groups were found.

No signs of histological changes in joints were apparent in healthy animals.

### Organs, blood indices and bodily pro-/antioxidant state

To estimate the impact of the procedures and treatment on systemic inflammation, the weight of each animal's internal organs and blood indices were measured and compared with those of healthy animal indices at the end of the study.

Many of the parameters differed significantly between the test and normal female and male animals. Arthritic rats had a lower total body weight than healthy rats from day 3 till the end of the experiment, but no significant differences were observed (data not shown). In the treated groups, the body weight was highest in the arthritic rats that received the middle dose of AH tincture.

The average relative weight of the organs at day 21 is shown in Table 2. In all treated groups of animals, the relative weight of the liver significantly differed between males and females ( $P < 0.05-0.01$ ) and was higher in the latter. A significant decrease in relative liver weight in comparison with the control AA group was observed only in male rats treated with low and middle doses of AH. The spleen weight decreased in the female rats that received a middle dose of AH, but increased in rats treated with a high dose of AH. Female rats treated with a

high dose of AH tincture had the highest weight of the spleen, which significantly differed from that in males ( $P < 0.001$ ). The relative thymus and adrenal weight was also higher in female rats. Significant differences between the sexes were observed in the control AA group ( $P < 0.02$ ) and the group that received a middle dose of AH ( $P < 0.05$ ) for the thymus weight, and in all test groups for the adrenal weight ( $P < 0.01-0.0001$ ). After the treatment, the thymus weight significantly decreased in females and the adrenal weight in males of all treated groups and in females that received a middle dose of AH compared with the control AA group.

Changes in the blood indices are shown in Fig. 2A. The ESR for all groups of rats with AA was markedly higher than for the healthy animal groups and was somewhat higher among female rats. There were no essential differences among the control and the treated groups. Treatment with a middle dose of AH significantly decreased the leukocyte count in both sexes of animals and with a high dose only in female rats.

According to the obtained results, the middle dose of AH (4.8 mg/kg/d) was selected for the investigation of the pro-/antioxidant bodily state in the blood serum and gastric mucosa homogenates.

Free radical formation resulting in lipid peroxidation, measured as the MDA level, the activity of antioxidant enzymes and the total AOA in rat serum are shown in Fig. 2B. MDA levels were found to be significantly elevated in female rats with AA compared with the healthy animals ( $P < 0.02$ ), and treatment with AH decreased it ( $P < 0.02$ ) to the level of healthy animals. There were no essential changes of MDA in healthy and arthritic non-treated and treated groups of male rats.

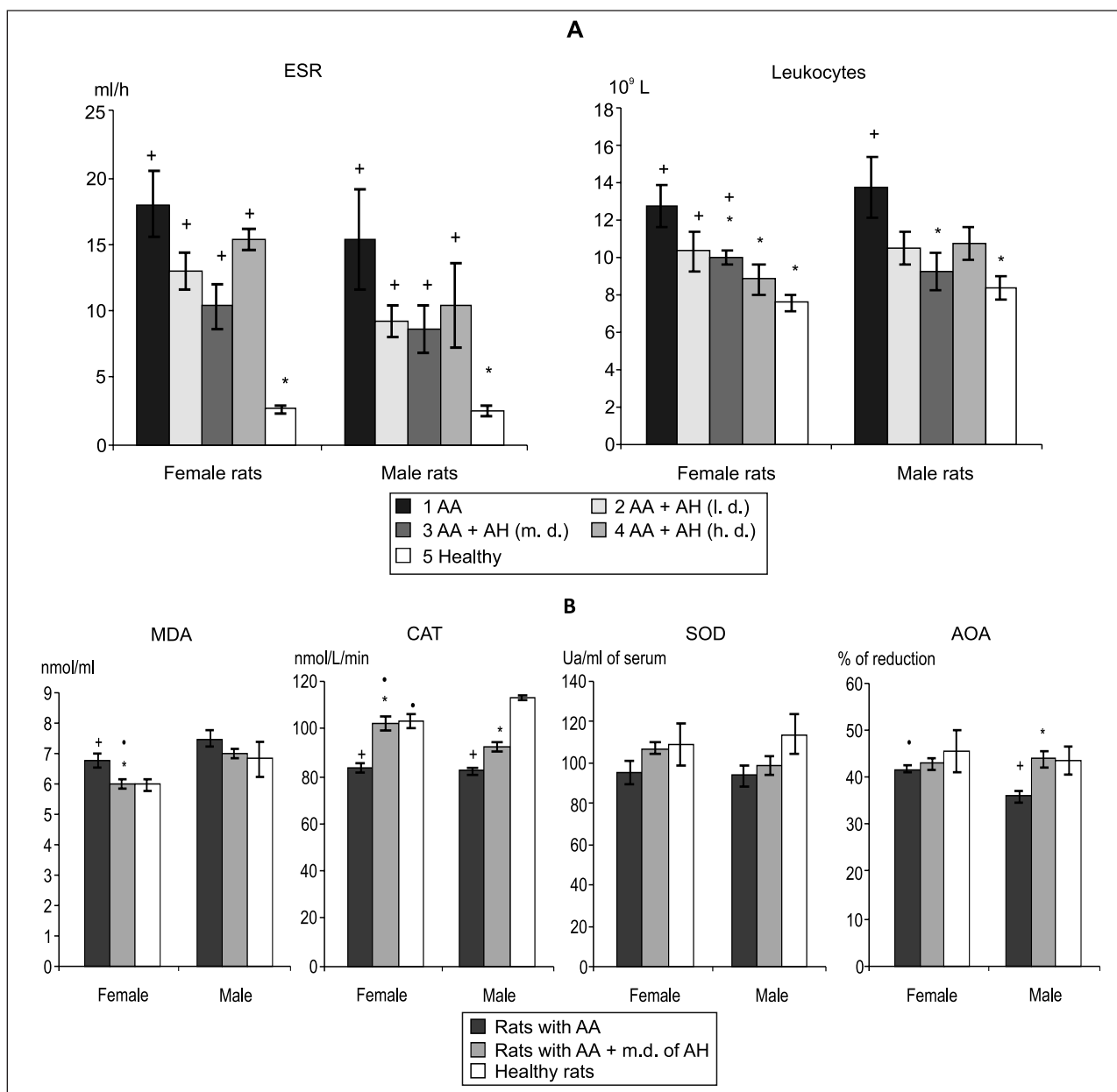
A decrease of CAT activity in the blood serum of both sexes of rats with AA in comparison with healthy animals was observed ( $P < 0.0001$ ). Its significant elevation (by 22.9% and 12.3%) in comparison with the control AA group ( $P < 0.001$ ;  $P < 0.01$ ) was observed after the treatment, and more pronounced changes were found in female rats.

No significant differences in SOD activity were observed in the test groups of animals. A decrease of AOA was revealed

Table 2. Relative weight of organs of Lewis rats with adjuvant arthritis (AA) treated with *Aesculus hippocastanum* L. tincture

Groups	Sex	Liver (g/kg <sup>-1</sup> )	Kidneys (g/kg <sup>-1</sup> )	Spleen (g/kg <sup>-1</sup> )	Thymus (g/kg <sup>-1</sup> )	Adrenals (g/kg <sup>-1</sup> )
1 (AA)	Female	3.97 ± 0.13	+0.85 ± 0.04	+0.40 ± 0.02	0.38 ± 0.02*	+0.052 ± 0.004*
	Male	3.74 ± 0.09	+0.83 ± 0.05	+0.35 ± 0.03	0.22 ± 0.05	+0.032 ± 0.002
2 (AA + AH) (2.4 g/kg/d)	Female	+4.05 ± 0.10*	+0.84 ± 0.03	+0.34 ± 0.02	0.30 ± 0.02*	+0.043 ± 0.002*
	Male	3.30 ± 0.17*	+0.78 ± 0.03	0.30 ± 0.04	0.29 ± 0.02	0.020 ± 0.002*
3 (AA + AH) (4.8 mg/kg/d)	Female	3.75 ± 0.06*	+0.77 ± 0.02	+0.34 ± 0.01*	0.30 ± 0.01**	0.040 ± 0.002**
	Male	3.35 ± 0.10*	0.75 ± 0.04	+0.30 ± 0.04	0.26 ± 0.01	0.020 ± 0.001*
4 (AA + AH) (9.5 mg/kg/d)	Female	+4.00 ± 0.10*	+0.87 ± 0.04	+0.48 ± 0.01**	0.31 ± 0.02*	0.045 ± 0.004*
	Male	3.55 ± 0.12	+0.84 ± 0.03	+0.31 ± 0.03	0.27 ± 0.01	0.024 ± 0.002*
5 (Healthy rats)	Female	3.54 ± 0.14	0.70 ± 0.02*	0.22 ± 0.001*	0.32 ± 0.02	0.036 ± 0.001**
	Male	3.34 ± 0.06	0.66 ± 0.01*	0.20 ± 0.004*	0.27 ± 0.02	0.021 ± 0.001*

Note. Adjuvant arthritis (AA) was induced in 40 rats by the foot paw method by injecting 0.1 ml of complete Freund's adjuvant (CFA) into the left hind paw under light anaesthesia. Group 1 (control) – animals with induced AA. The next three groups – rats with AA treated daily with different doses of AH tincture. Group 5 – healthy animals. \* The differences are significant in comparison with the control AA group. + The differences are significant in comparison with healthy animals. \* – The difference is significant between sexes.



**Fig. 2.** Blood (A) and pro-/antioxidant system (B) indices of rats with adjuvant arthritis (AA) treated with various doses of *Aesculus hippocastanum* L. (AH) tincture.

Group 1 (control) – animals with induced AA. Group 2 – rats with AA treated with low dose (2.4 mg/kg/d) of AH (l. d.). Group 3 – rats with AA treated with middle dose (4.8 mg/kg/d) of AH (m. d.). Group 4 – rats with AA treated with high dose (9.5 mg/kg/d) of AH (h. d.). \* The difference is significant in comparison with the control AA group. † The difference is significant in comparison with healthy animals. • The difference is significant between the sexes

in male rats with AA in comparison with healthy animals ( $P < 0.05$ ), and the treatment elevated it by 22.4% ( $P < 0.01$ ).

Comparison of pro-/antioxidant activity status of blood serum in female and male rats showed a lower MDA level and a statistically significantly higher AOA ( $P < 0.01$ ) in female rats with AA. In healthy animals, male rats showed a higher CAT activity than females ( $P < 0.02$ ). Although the treatment with a middle dose of AH lowered the MDA level and increased CAT activity in animals of both sexes, a significant difference remained between females and males ( $P < 0.01$ ;  $P < 0.05$ ).

It is known that the digestive tract is damaged during the development of the autoimmune process; therefore, the state of the oxidative system in the gastric mucosa tissue homogenates of rats with AA was examined and compared with the indices of healthy animal homogenates non-incubated and incubated with AH tincture.

A significant increase of MDA – by 21.9% ( $P < 0.002$ ) in female and by 35.1% ( $P < 0.01$ ) in male – pure gastric tissue homogenates of arthritic rats in comparison with healthy animals was observed (Table 3). Incubation of homogenates with AH tincture and their comparison in healthy and

Table 3. The influence of *Aesculus hippocastanum* L. tincture on the indices of pro-/antioxidant system in the homogenates of gastric mucosa of rats with AA

Groups		Sex	MDA (nmol/ml)	CAT (nmol/L/min)	SOD (Ua/mg of protein)	AOA (% of reduction)
AA rats	Homogenate	Female	$^{+}5.01 \pm 0.11$	$^{+}70.58 \pm 2.06$	$115.47 \pm 9.27$	$32.02 \pm 3.41$
		Male	$^{+}5.08 \pm 0.23$	$^{+}67.19 \pm 4.18$	$117.21 \pm 15.45$	$34.61 \pm 2.01$
	Homogenate + m.d. of HC	Female	$4.48 \pm 0.17^{*}$	$77.14 \pm 0.97^{*}$	$114.23 \pm 10.41$	$41.57 \pm 3.57$
		Male	$^{+}4.54 \pm 0.21$	$76.76 \pm 3.29$	$115.71 \pm 11.57$	$44.87 \pm 3.71^{*}$
Healthy rats	Homogenate	Female	$4.01 \pm 0.17$	$90.43 \pm 3.15$	$96.47 \pm 6.28$	$30.12 \pm 2.16$
		Male	$4.17 \pm 0.07$	$92.27 \pm 2.67$	$101.52 \pm 5.35$	$29.64 \pm 4.27$
	Homogenate + m.d. of HC	Female	$4.11 \pm 0.13$	$78.17 \pm 2.25^{*}$	$116.46 \pm 5.87^{*}$	$42.50 \pm 4.01$
		Male	$3.76 \pm 0.19$	$80.78 \pm 2.37^{*}$	$121.87 \pm 7.64$	$40.09 \pm 3.96$

Note. The gastric mucosa of rats with adjuvant arthritis (AA) and of healthy animals was scrapped, weighted and homogenized in an appropriate ice-cold phosphate buffer. 10% gastric tissue homogenates were produced with 1 : 9 ratio (one part of tissue and nine parts of buffer). The end product of lipid peroxidation – malondialdehyde (MDA), antioxidant enzymes catalase (CAT), superoxide dismutase (SOD) and total antioxidant activity (AOA) – were determined. \*The differences in respective groups are significant between the pure homogenates and the homogenates incubated with AH tincture (+). The difference is significant between the homogenates of healthy and arthritic animals.

arthritic rats revealed an insignificant increase of MDA in female rats with AA and its elevation by 20.7% in male rats ( $P < 0.05$ ). A decrease of MDA by 10.6% was observed only in homogenates of female arthritic rats after their incubation with AH tincture in comparison with the pure homogenates of these animals ( $P < 0.05$ ).

CAT activity was significantly lower in gastric tissue homogenates obtained from arthritic rats of both sexes ( $P < 0.002-0.001$ ). A significantly higher CAT activity ( $P < 0.05$ ) in female arthritic rats' homogenates incubated with AH tincture versus pure homogenates was found, but in the healthy group of animals the incubation with AH decreased CAT activity ( $P < 0.02$ ).

A statistically significant increase of SOD activity (by 20.7%) was revealed only in homogenates from the healthy female rats incubated with AH tincture ( $P < 0.05$ ). AOA was insignificantly lower in the gastric mucosal homogenates of arthritic rats than in healthy animals. A significant increase of AOA was observed in arthritic male rat's homogenates incubated with AH tincture ( $P < 0.05$ ).

So, the development of AA significantly increased the MDA level, decreased CAT activity and restricted SOD and AOA activity in gastric tissue homogenates. Their incubation with AH tincture had a positive effect, especially in female rat homogenates in which a significant decrease of MDA and a higher CAT activity were found in arthritic rats and elevation of SOD activity in healthy rats.

## DISCUSSION

Examination of the clinical course of the pathological process in our study showed that females developed the disease with a higher incidence than males. The highest level of paw inflammation and the highest development of polyarthritis were observed on day 21 after adjuvant injection in these rats. We demonstrate a certain preventive effect of the oral administration of AH tinctures on the development of inflammation in AA rats. Joint swelling was lowest in the

groups treated with 4.8 mg/kg of AH tincture and significantly differed from the control AA group in female rats at the end of the experiment; the number of animals with polyarthritis decreased.

Although all doses of AH markedly decreased edema and angiomatosis, a significantly lower general inflammatory infiltration in rats was observed only after treatment with a medium dose of AH. A more positive effect of treatment in the synovium and significant changes in the cartilage were also found in female rats treated with low and middle doses of AH.

Numerous studies have shown that in the course of AA not only joints with obvious signs of inflammation, but also visceral organs may be affected by the pathological process. Many changes in various biological systems, such as decreased albumin, increased globulin,  $\alpha_1$ -acid glycoprotein and fibrinogen in serum and in liver, decreased lipid peroxidation, drug metabolizing enzyme activities and the cytochrome P-450 level in the liver are observed (22, 23). These changes in protein metabolism implicate hepatic involvement in adjuvant disease, and the weight of the liver increases. It is also known that the body and the thymus weight is reduced in arthritic rats as compared with non-arthritic animals (24, 25). In our study, three days after adjuvant injection the rats started losing body weight, even before the external signs of polyarthritis had been manifested. The decrease in body weight in arthritic rats had been previously described in models of experimental arthritis (26). In the treated groups, the highest body weight was in arthritic rats that received a middle dose of AH tincture. As documented elsewhere (27, 28) one of the diagnostic characteristics of systemic inflammation in experimental arthritis is a gradual increase of spleen weight, and splenomegaly is used as a pathological index of AA. Although the mechanism underlying splenomegaly has not been investigated in detail, some authors (29) consider immunological abnormalities to be an important factor. Treatment with low and middle doses of AH significantly decreased the relative weight of the liver in

male rats and the spleen weight in female rats that received the middle dose of AH. Low and high doses of AH decreased the thymus weight and middle doses the adrenal weight in female rats. The male rats' adrenals weight was lower in all treated groups.

The treatment improved the blood indices, diminished the ESR and leukocyte count. The latter significantly decreased in both sexes of animals treated with a middle dose of AH and only in female rats treated with a high dose of AH.

The pro-/antioxidant state of the body in the blood serum and gastric mucosa homogenates was investigated using the middle dose of AH. It is known that oxidative stress plays a key role in the inflammation and destruction of RA and animal arthritis joints (30, 31). Our previous studies (15) have shown that AA changes the response of the oxidative system in rats. One of the indices of oxidative damage is the formation of MDA as the end product of lipid peroxidation (32). Free radical formation resulting in lipid peroxidation, measured as the MDA level, was found to be significantly elevated in female rats with AA, and the treatment with AH decreased it to the level of healthy animals. AH significantly increased the diminished AOA in male rats. A decreased blood serum CAT activity of arthritic animals was significantly elevated after the treatment, and more pronounced changes were found in female rats. A comparison of the pro-/antioxidant activity status of the blood serum in female and male rats showed a lower MDA level and a statistically significant AOA in female rats with AA. Healthy males showed a significantly higher CAT activity than females. Although treatment with a middle dose of AH lowered the MDA level and increased CAT activity in animals of both sexes, significant differences remained between males and females as the latter showed a lower level of MDA and a higher CAT activity.

The development of AA significantly increased the MDA level and decreased CAT activity, but only slightly affected SOD and AOA activity in gastric tissue homogenates. Their incubation with AH tincture had a positive effect, especially in female rats in which a significant decrease of MDA and a higher CAT activity were found in arthritic rats and an elevation of SOD activity in healthy rats. The pro-/antioxidant status of gastric tissue homogenates did not significantly differ between male and female rats.

As to the effect of treatment, it should be noted that middle doses of AH showed the most pronounced therapeutic effect, especially in female rats with AA. It is known that AA leads to a chronic activation of the hypothalamus and pituitary gland, with the resultant production of corticotropin-releasing hormone and adrenocorticotropin (33, 34). The different hormonal status of male and female rats with AA can also be important for the pharmacological effect of AH tincture.

In conclusion, our experiments have indicated that AH may decrease oxidative reactions, resulting in the prevention of inflammatory response in AA rats. The underlying mecha-

nisms by which herbal tincture intake influences systemic inflammation remain to be elucidated, although the most likely explanation is a causal link between the anti-inflammatory and antioxidant activity of the tinctures.

Although animal models can contribute valuable information in this area as well, it is clear that human studies are of paramount importance. Future research, both at the fundamental and clinical levels, will certainly facilitate our understanding of how herbal tinctures and the pro-/antioxidative status of an organism contribute to a pathological process and under what circumstances the herbal tincture studied should be used therapeutically.

## ACKNOWLEDGEMENTS

The authors are indebted to Dr. A. Keturkiene for preparing the tinctures.

Received 10 November 2010

Accepted 7 December 2010

## References

1. Nagai N, Fukuhata T, Ito Y, Tai H, Hataguchi Y, Nakagawa K. Preventive effect of water containing magnesium ion on paw edema in adjuvant-induced arthritis rat. *Biol Pharm Bull* 2007; 30(10): 1934–37.
2. Cai X, Zhou H, Wong YF, Xie Y, Liu ZQ, Jiang ZH et al. Suppressive effects of QFGJS, a preparation from an anti-arthritis herbal formula, on rat experimental adjuvant-induced arthritis. *Biochem Biophys Res Commun* 2005; 337(2): 586–94.
3. Long L, Soeken K, Ernst E. Herbal medicines for the treatment of osteoarthritis: a systemic review. *Rheumatology* 2001; 40: 779–93.
4. Bombardelli E, Morazzoni P. *Aesculus hippocastanum* L. *Fitoterapia* 1996; 67: 483–511.
5. Sirtori CR. Aescin: pharmacology, pharmacokinetics and therapeutic profile. *Pharmacol Res* 2001; 44(3): 183–93.
6. Panigati D. Farmacologia dell'escina, saponina dell' *Aesculus hippocastanum* L. Parte II. Farmacodinamica dell'escina. Capitolo II. *Boll Chim Farm* 1992; 131: 284–93.
7. Pittler MH, Ernst E. Horse chestnut seed extract for chronic venous insufficiency. *Chochrane Database Syst Rev* 2004; 2: CD003230.
8. Suter A, Bommer S, Rechner J. Treatment of patients with venous insufficiency with fresh plant horse chestnut seed extract: a review of 5 clinical studies. *Adv Ther* 2006; 23(1): 179–90.
9. Aleksandrov PN, Speranskaia TV, Bobkov IG, Zagorevskii VA, Zykov DA. Effect of rutin and esculamine on models of aseptic inflammation. *Farmacol Toksikol* 1986; 49(1): 84–6.
10. Sakuma S, Nishigaki F, Magari K, Ogawa T, Miyata S, Ohkubo Y et al. FK506 is superior to methotrexate in therapeutic effects on advanced stage of rat adjuvant-induced arthritis. *Inflamm Res* 2001; 50(10): 509–14.



11. Kato S, Takeuchi K. Alteration of gastric ulcerogenic and healing responses in rats with adjuvant-induced arthritis. *Jpn J Pharmacol* 2002; 89(1): 1–6.
12. Nagai N, Fukuhata T, Ito Y, Usui S, Hirano K. Preventive effect of co-administration of water containing magnesium ion on indomethacin-induced lesions of gastric mucosa in adjuvant-induced arthritis rat. *Biol Pharm Bull* 2009; 32(1): 116–20.
13. García-González A, Lotz M, Ochoa JL. Anti-inflammatory activity of superoxide dismutase obtained from *Debaryomyces hansenii* on type II collagen-induced arthritis in rats. *Rev Invest Clin* 2009; 61(3): 212–20.
14. Jachak SM, Gautam R, Selvam C, Madhan H, Srivastava A, Khan T. Anti-inflammatory, cyclooxygenase inhibitory and antioxidant activities of standardized extracts of *Tri-dax procumbens* L. *Fitoterapia* 2010; Sep. 8.
15. Vasiliauskas A, Keturkiene A, Leonaviciene L, Vaitkiene D. Influence of *Aesculus hippocastanum* (L.) tincture *in vitro* on the indices of reactive oxygen species of gastric tissue in rats with indomethacin-induced ulcers in adjuvant arthritis. *Biologija* 2004; 2(2): 62–6.
16. Leonaviciene L, Bradunaite R, Vaitkiene D, Vasiliauskas A, Keturkiene A. Collagen-induced arthritis and pro-/antioxidant status in Wistar and Lewis rats. *Biologija* 2008; 54(4): 290–300.
17. Keturkienė A, Vaitkienė D, Vaiciūnienė J, Leonavičienė L. Pelkinės vingiorykštės ir paprastojo kaštono tinktūrų ūminio toksiškumo tyrimas. *Medicina* 2000; 36(8): 926–31.
18. Gavrilov VB, Gavrilova AR, Mazul LM. Analysis of the procedures for estimation of lipid peroxidation products using thiobarbituric acid test. *Vopr Med Chim* 1987; 1: 118–21.
19. Koroliuk MA, Ivanova LI, Maïorova IG, Tokarev VE. A method of determining catalase activity. *Lab Delo* 1988; 1: 16–9 (in Russian).
20. Csovari S, Andyal T, Strenger J. Blood antioxidant parameters and their diagnostic value in elderly patients. *Lab delo* 1991; 10: 9–13.
21. Galaktionova LP, Molchanov AV, El'chaninova SA, Varshavskii B. Lipid peroxidation in patients with gastric and duodenal peptic ulcers. *Klin Lab Diagn* 1998; 6: 10–4 (in Russian).
22. Fedato JZ, Ishii-Iwamoto EL, Amado CB, Vicentini GE, Panerari AD, Bracht A et al. Gluconeogenesis in the liver of arthritic rats. *Cell Biochem Funct* 1999; 17(4): 271–8.
23. Yamaguchi Y, Tanaka Y, Yamada K, Bando Y, Kunitomo M. Abnormal lipid metabolism in adjuvant arthritic rats. *Jpn J Pharmacol* 1989; 50: 377–86.
24. Brout BC, Clemens JW. Effect of adjuvant-induced arthritis on serum luteinizing hormone and testosterone concentrations in the male rat. *Life Sci* 1987; 41: 1559–65.
25. Hidaka T, Hosoe K, Yamashita T, Watanabe K. Effect of alpha-(3,5-di-tert-butyl-4-hydroxybenzylidene)-gamma-butyrolactone (KME-4), a new anti-inflammatory drug, on the established adjuvant arthritis in rats. *Jpn J Pharmacol* 1986; 42: 181–7.
26. López-Calderón A, Soto L, Martín AI. Chronic inflammation inhibits GH secretion and alters the serum insulin-like growth factor system in rats. *Life Sci* 1999; 65(20): 2049–60.
27. Fletcher DS, Widmer WR, Luell S, Christen A, Orevillo C, Shah S et al. Therapeutic administration of a selective inhibitor of nitric oxide synthase does not ameliorate the chronic inflammation and tissue damage associated with adjuvant-induced arthritis in rats. *J Pharmacol Exp Ther* 1998; 284: 714–21.
28. Paulos CM, Varghese B, Widmer WR, Breur GJ, Vlashi E, Low PS. Folate-targeted immunotherapy effectively treats established adjuvant and collagen-induced arthritis. *Arthritis Res Ther* 2006; 8: 1–10.
29. Tanahashi M, Funaba Y, Itoh M, Kawabe N, Nakadate-Matsushita T. Inhibitory effect of TKR-530 on rat adjuvant arthritis. *Pharmacology* 1998; 56: 242–51.
30. Sarban S, Kocyigit A, Yazar M, Isikan UE. Plasma total antioxidant capacity, lipid peroxidation, and erythrocyte antioxidant enzyme activities in patients with rheumatoid arthritis and osteoarthritis. *Clin Biochem* 2005; 38(11): 981–6.
31. Tsuji G, Koshiha M, Nakamura H, Kosaka H, Hatachi S, Kurimoto C et al. Thioredoxin protects against joint destruction in a murine arthritis model. *Free Radic Biol Med* 2006; 40(10): 1721–31.
32. Ozkan Y, Yardym-Akaydyn S, Sepici A, Keskin E, Sepici V, Simsek B. Oxidative status in rheumatoid arthritis. *Clin Rheumatol* 2007; 26(1): 64–8.
33. Harbuz MS, Rooney C, Jones M, Ingram CD. Hypothalamo-pituitary-adrenal axis responses to lipopolysaccharide in male and female rats with adjuvant-induced arthritis. *Brain Behav Immunity* 1999; 13: 335–47.
34. Sarlis NJ, Chowdrey HS, Stephanou A, Lightman SL. Chronic activation of the hypothalamo-pituitary-adrenal axis and loss of circadian rhythm during adjuvant-induced arthritis in the rat. *Endocrinology* 1992; 130: 1775–9.

Audrius Vasiliauskas, Laima Leonavičienė, Dalia Vaitkienė,  
Rūta Bradūnaitė, Aloyza Lukšienė

### **AESCULUS HIPPOCASTANUM L. TINKTŪROS PRIEŠ- UŽDEGIMINIS POVEIKIS IR ŽIURKIŲ, SERGANČIŲ ADJUVANTINIŲ ARTRITU, PRO-/ANTIOKSIDACINĖ ORGANIZMO BŪKLĖ**

#### *Santrauka*

**Prielaidos ir tikslas.** Reumatoidinio artrito (RA) gydymas įprastomis terapinėmis priemonėmis leidžia kontroliuoti ligos simptomus, tačiau jų poveikis ilgai sergantiems ligoniams gana ribotas ir sukelia įvairias nepageidautinas reakcijas. Šiuo metu plačiai plinta alternatyvios / papildomos medicinos, daugiausia vaistažolių terapijos, taikymas gydant reumatines ligas. Šio darbo tikslas – įvertinti *Aesculus hippocastanum* L. (AH) tinktūros prieš uždegiminį ir pro-/antioksidacinį poveikį žiurkėms, sergančioms adjuvantiniu artritu (AA).

**Medžiaga ir metodai.** Darbui panaudota 50 Levis veislės abiejų lyčių žiurkių: 40 jų buvo sukeltas adjuvantinis artritas (AA) suleidžiant vienkartinę 0,1 ml Froindo adjuvanto dozę į kairę užpakalinės kojos padą. Priešuždegiminis aktyvumas kontrolinėje ir tiriamosiose grupėse nustatytas matuojant sąnario patinimą bei kūno masės pokyčius tris kartus per savaitę. Gydant AA kasdien sugirdytos trys skirtingos AH tinktūros dozės (2,4, 4,8 ir 9,5 mg/kg apskaičiuotos pagal sausos tinktūros svorį). Tyrimo pabaigoje įvertinti kraujo rodikliai, histologiniai pokyčiai uždegiminiame sąnaryje, pro-/antioksidacinės sistemos rodikliai kraujo serume ir skrandžio gleivinės audinio homogenatuose: malondialdehididas (MDA), antioksidaciniai fermentai – katalazė (CAT) ir superoksido dismutazė (SOD), taip pat bendras antioksidantinis aktyvumas (AOA).

**Rezultatai.** Žiurkių patelių, kurioms buvo sukeltas AA, gavusių vidutinę AH tinktūros dozę (4,8 mg/kg), sąnarių patinimas buvo

mažiausias ir ženkliai skyrėsi nuo AA kontrolinės grupės. Gydymas šia AH doze pagerino sisteminius ligos parametrus, tokius kaip kraujo rodikliai, normalizavo vidaus organų masę ir nepasižymėjo toksiniu poveikiu, todėl ji buvo atrinkta pro-/antioksidacinės sistemos rodiklių ištyrimui kraujo serume ir skrandžio gleivinės audinio homogenatuose. Tiriant serumo pro-/antioksidacinės sistemos būklę, tarp lyčių aptikti reikšmingi skirtumai. Mažiausias MDA kiekis ir statistiškai patikimas AOA nustatytas AA sergančioms žiurkių patelėms. Nors gydymas sumažino MDA lygį ir padidino CAT aktyvumą abiejų lyčių gyvūnams, tačiau išliko ženklūs skirtumai tarp patinų ir patelių, kurių organizme MDA kiekis buvo mažesnis, o CAT aktyvumas didesnis. AA sergančių gyvūnų skrandžio gleivinės audinių homogenatuose ženkliai padidėjo MDA kiekis ir sumažėjo CAT aktyvumas, tačiau nedaug pakito AOA ir SOD aktyvumas. Tuo tarpu pro-/antioksidacinė būklė abiejų lyčių gyvūnų skrandžio homogenate skyrėsi nereikšmingai.

Taikant inkubaciją AH tinktūra, gautas teigiamas poveikis, ypač AA sergančių žiurkių patelių skrandžio gleivinės audinio homogenatuose, kuriuose ženkliai sumažėjo MDA, buvo aukštesnis CAT aktyvumas, ir padidėjo sveikų žiurkių SOD aktyvumas. Tiriant pro-/antioksidacinės sistemos rodiklius skrandžio audinio gleivinės homogenatuose, negauta reikšmingų skirtumų tarp patinų ir patelių.

**Išvados.** Šio tyrimo rezultatai rodo, kad AH tinktūra yra naudinga dėl priešuždegiminio ir antioksidacinio aktyvumo. Geriausias poveikis nustatytas AA sergančioms žiurkių patelėms, gavusioms vidutinę AH dozę. *In vivo* pastebėtas AH tinktūros prieš uždegiminis ir antioksidacinis poveikis gali būti perspektyvus naudojant ją kaip papildomą priemonę greta įprasto RA gydymo.

**Raktažodžiai:** žiurkės, adjuvantinis artritas, pro-/antioksidacinis aktyvumas, augalų tinktūra