

# Histopathological and functional changes in the testicles of albino rats experimentally infected with *Arcobacter butzleri*

Yemisi Olukemi Adesiji<sup>1</sup>,

Benjamin Obukowho Emikpe<sup>2</sup>,

Ahmed Bayo Opalekundu<sup>3</sup>

<sup>1</sup>Department of Medical Microbiology and Parasitology, College of Health Sciences, Ladoke Akintola University of Technology, PMB 4000, Ogbomoso, Nigeria

<sup>2</sup>Department of Veterinary Pathology and Diagnostics, Faculty of Veterinary Medicine, University of Ibadan, Nigeria

<sup>3</sup>Department of Medical Laboratory Science, Kwara State Polytechnic, Ilorin, Nigeria

**Background.** *Arcobacter* is an emerging zoonotic enteropathogen associated with spontaneous abortion, diarrhea and mastitis in domestic animals.

**Materials and methods.** Thirty male pathogen-free albino rats were infected with a single challenge of *Arcobacter butzleri* ( $10^8$  cfu/ml) isolated from the stool of healthy pigs with the aim of investigating the effects of *A. butzleri* on rat testicular histology and spermatogenesis.

**Results.** In previously healthy male albino rats, *A. butzleri* caused testicular degeneration associated with reduced sperm count and motility.

**Conclusions.** The result of this study suggests that *A. butzleri* produces testicular degeneration and the associated disruption of spermatogenesis in albino rats; hence, its infertility potential in livestock industry and its economic importance should be further investigated.

**Key words:** *Arcobacter butzleri*, testicular degeneration, infertility, pathogenicity, sperm count, albino rats

## INTRODUCTION

*Arcobacter* is an emerging enteropathogen with an increasing evidence of the zoonotic potential associated with prolonged diarrhoea and occasional systemic infections such as bacteraemia and peritonitis in humans (1). An evidence-based semi-quantitative method for prioritization of food-borne zoonoses ranked *A. butzleri* as a microbe of “significant importance” (2). *Arcobacter* was first isolated from

aborted bovine and porcine fetuses (3), especially *A. butzleri* and *A. skirrowii* which were isolated from aborted fetuses and placenta of bovine, porcine and ovine origin (4). Although no remarkable pathological changes were identified, the clinical signs associated with *Arcobacter* infection include infertility, chronic discharge during oestrus, still-birth and late-term abortions (5).

The pathogenicity and virulence mechanisms of *Arcobacter* species are still poorly understood, despite its increasing incidence and isolation from clinical and food products (6). The virulence of *A. cryaerophilus* was also first described when it was observed that the strains tested induced the accumulation of fluid and electrolytes in the rat ileal loop assay and showed an *in vitro* invasion of Hep-2

Correspondence to: Yemisi Olukemi Adesiji, Department of Medical Microbiology and Parasitology, College of Health Sciences, Ladoke Akintola University of Technology, PMB 4000 Ogbomoso, Nigeria.  
E-mail: drmradesiji@yahoo.com

cells (7). Several studies were reported on their adhesion capacity (8–10), invasiveness (9, 11), and cytotoxicity (12–14) in several cell lines. Collectively, in these studies, the strains tested showed adhesion, invasion, and cytotoxicity, toxicity and adherence being the most commonly observed effects. The differences observed among different studies may be due to the origin of the strains (environmental versus clinical) as well as to different cell lines used in the studies, *A. butzleri* being the most invasive species in experimental animal infections (15). Other animal models and *in vivo* experiments have been reviewed in another recent publication (16). The presence of adhesion molecules in *A. butzleri* have been proven by the capacity of the strains tested to agglutinate human, rabbit, and sheep erythrocytes, and hemagglutinin of about 20 kDa has been characterized by Western immunoblotting (17, 18).

A few animal studies on the pathogenicity of *Arcobacter* species include experimental oral infection of caesarean-derived 1-day-old piglets in whom all strains colonized and multiplied in the gut of the tested groups, but only *A. butzleri* strains (from human faeces and swine) were able to invade the internal organs of infected animals (19).

In another study, 3- to 5-day-old chickens and turkeys were infected orally with the human *A. butzleri* strain. The results demonstrated the invasive and virulence capacity of the *A. butzleri* strains, which was suggested to be host-dependent with respect to species and breed (20). Experimental infection in udder also produced clinical mastitis with fever and a reduced milk yield (21). In another study, venereal transmission was suggested as *A. butzleri* and *A. cryaerophilus* were isolated from the preputial fluid of boars and fattening pigs (22). *Arcobacter* species were also detected in clinically healthy sows and live newborn piglets (23). Furthermore, different *Arcobacter* species were detected in a single aborted fetus and in different fetuses from the same litter; these findings have indicated that the *Arcobacter* strain plays the primary role in abortion and reproductive disorders while others are opportunistic pathogens (4). The role of *Arcobacter* in chronic reproductive disorders in farm animals has not been previously investigated. Therefore, this study aimed to study the effects of *Arcobacter* on the testes of albino rats with a view to provide an insight into the pathogenicity of *Arcobacter* in male animals.

## MATERIALS AND METHODS

### Experimental animals

Thirty male five-month-old healthy albino rats (*Rattus norvegicus*) weighing 200–250 g were acquired from the animal house unit of the college of Health Sciences, Ladoko Akintola University of Technology (LAUTECH), Osogbo, Nigeria. They were housed in transparent plastic cages

33 × 20.5 × 19 cm. The animals were fed on an antibiotics-free ration and given water *ad libitum*. They were housed five rats per cage and tagged before inoculation. The care and handling of the animals complied with the guidelines of the Ladoko Akintola University of Technology and of the National Institute of Health for the care of laboratory animals.

### Preparation of *Arcobacter* inoculums and procedure

The *Arcobacter butzleri* strain isolated from pigs in Nigeria, earlier confirmed by PCR and maintained in stock cultures at –25 °C glycerol *Arcobacter* broths, was resuscitated in brain heart infusion agar supplemented with 5% of yeast and 7% of sheep blood and incubated at 35–37 °C in a microaerophilic atmosphere (1). Bacteria were collected at the exponential growth stage and diluted in 0.95 % normal saline. The suspension was later standardized by McFarlands Nephelometry to 10<sup>8</sup> CFU (colony-forming units) per ml. After the rats had been anaesthetized with inspired ether, 0.5 ml of *A. butzleri* suspension containing 10<sup>8</sup> CFU was injected into the proximal right ductus deferens of the rats' testes, and 0.5 ml of sterile normal saline solution was given to other sets of rats to serve as the control for the experiment. Five animals from each group were sacrificed on days 5, 10, 15, 20 and 30 of the experiment after bacterial inoculation, and organ specimens from the testes and epididymis sections of the rats were fixed by immersing in the Bouins fluid for 24 hours and later preserved in 10% formalin for 48 hours, embedded in paraffin (2–3 mm thick), stained with haematoxylin and eosin (H & E) and examined microscopically for histopathological changes. For sperm count and motility evaluation, several cuts on the testes were made, teased out into bits and thereafter suspended in 2 ml of Ham F solution. The latter was incubated for 10 minutes at 37 °C. Later, 50 µl were transferred with the aid of a sterile pipette into a haemocytometer chamber for phase contrast microscopy.

## RESULTS

There were no visible gross lesions on the surface of the testes and epididymis. The germinal epithelium and basement membrane of testes in the control group were intact, showing tubules with active spermatogenesis (Fig. 1). The test group that received 10<sup>8</sup> CFU bacterial inoculums after day 5 to 30 had a varying degree of sperm count and motility post inoculation. After a single challenge, as the days passed by, there was a slight but not significant increase in the size of testes and the epididymis, but a significant reduction in spermatozoa count and motility ( $P < 0.05$ ) in the test group was observed (Table). Degenerative changes in the test group consisted of a thickening of the basement membrane and absence of spermatozoa within the tubules (Fig. 2).

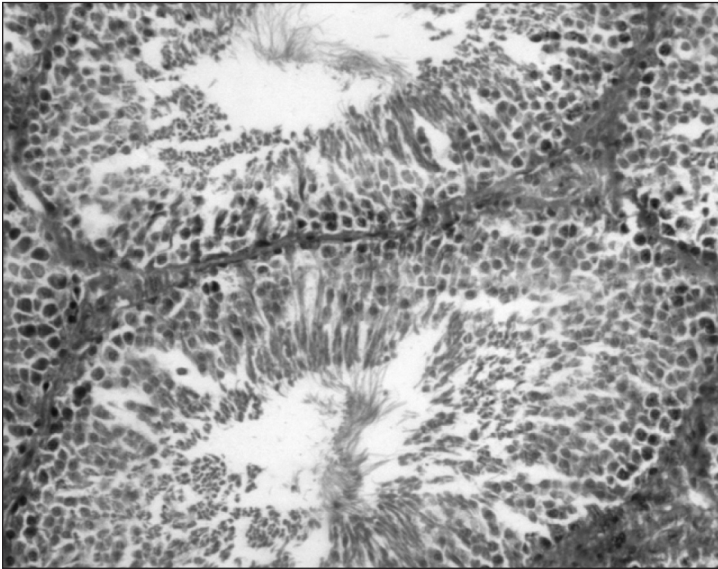


Fig. 1. Normal testis shows tubules with active spermatogenesis. Control: (H & E  $\times$  100)

Table. Changes of fertility indices in male albino rats with *Arcobacter* experimental infection

Groups	Inoculum 0.5 ml	Sperm count	Sperm motility	Organ weight, g Testes epididymis
Control	Sterile saline solution	154 $\pm$ 1.14	>70%	0.57 $\pm$ 0.03 0.17 $\pm$ 0.01
Test group (day 5)	10 <sup>8</sup> cfu	144 $\pm$ 1.10	>50%	0.59 $\pm$ 0.01 0.18 $\pm$ 0.01
Test group (day 10)	10 <sup>8</sup> cfu	110 $\pm$ 1.11	>40%	0.60 $\pm$ 0.03 0.20 $\pm$ 0.01
Test group (day 15)	10 <sup>8</sup> cfu	100 $\pm$ 1.00	>40%	0.61 $\pm$ 0.03 0.18 $\pm$ 0.00
Test group (day 20)	10 <sup>8</sup> cfu	110 $\pm$ 1.11	>50%	0.58 $\pm$ 0.03 0.17 $\pm$ 0.01
Test group (day 30)	10 <sup>8</sup> cfu	120 $\pm$ 1.00	>60%	0.58 $\pm$ 0.02 0.18 $\pm$ 0.00

The data are a mean of 5 replicates  $\pm$  standard deviation.

P < 0.05 significant.

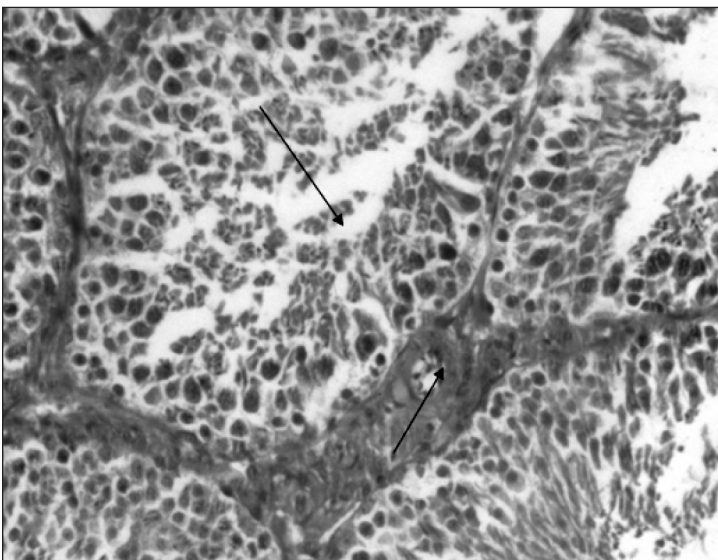


Fig. 2. Absence of spermatozoa in the tubules, marked degeneration and thickening of the basement membrane (H & E  $\times$  100)

## DISCUSSION

Various pathologic concepts have evolved from experimental and clinical studies to elucidate the effects of bacteria on the testicular structure and function (24). *Ar-*

*cobacter* has been implicated in cases of infertility in domestic animals (25). Results obtained in our study showed that *Arcobacter* produced testicular degeneration, a significant reduction in sperm count and motility. Testicular degeneration accompanied by a reduced sperm count and

motility in the test group supports the concept that the inflammation which accompanies the concomitant damage of the seminiferous tubules could result in infertility. A slight insignificant post-infection increase in the size of the testes and epididymis could be due to the infiltration of inflammatory cells and fluid which accompanies a normal response to bacterial infection (26). Although the behavioral sexual potential was not investigated in this study, it is noteworthy that without therapeutic intervention, sperm count, motility and organ size appeared to undergo resolution. It could be suggested from this study that the degenerative changes produced by *Arcobacter* appear to be self-limiting. In conclusion, *Arcobacters* appears to possess the capacity to induce testicular degeneration and hence male infertility which could lead to herd infertility in farm animals.

### ACKNOWLEDGEMENTS

The PCR confirmation in the isolate was carried out at the Laboratoire de Bacteriologie, Hôpital Pellegrin, Place Amelle Raba Leon, 33076 Bordeaux, France with the support of Prof. Francis Megraud. Also, part of histological interpretations were carried out at the Department of Veterinary Pathology, Gent University, Belgium with the assistance of Lieve.

Received 23 August 2011

Accepted 28 September 2011

### References

- Vandamme PM, Vancanneyt B, Pot L, Mels B, Hoste D, Dewettinck L et al. Polyphasic taxonomic study of the emended genus *Arcobacter* with *Arcobacter Arcobacter* comb. nov. and *Arcobacter skirrowii* sp. nov., an aerotolerant bacterium isolated from veterinary specimens. *Int J Syst Bacteriol.* 1992; (42): 344–56.
- Kim HM, Hwang CY, Cho, BC. *Arcobacter Marinum* sp. nov. *Int J Syst Evol Microbiol.* 2010; (60): 531–6.
- Ellis WA, Neill SD, O'Brien JJ, Ferguson HW, Hanna J. Isolation of *Spirillum* / *Vibrio*-like organisms from bovine fetuses. *Vet Rec.* 1977; (100): 451–2.
- On SL, Jensen TK, Bille-Hansen V, Jorsal SE, Vandamme P. Prevalence and diversity of *Arcobacter* spp. isolated from the internal organs of spontaneous porcine abortions in Denmark. *Vet Microbiol.* 2002; (85): 159–67.
- Schroeder-Tucker L, Wesley IV, Kiehlbauch JA, Larson DJ, Thomas LA, Erickson GA. Phenotypic and ribosomal RNA characterisation of *Arcobacter* species isolated from porcine aborted fetuses. *J Vet Diagn Invest.* 1996; (8): 186–95.
- Patyal A, Rathore RS, Mohan HV, Dhama K, Kumar A. Prevalence of *Arcobacter* spp. in humans, animals and foods of animal origin including sea food from India. *Transboundary and Emerging Diseases.* 2011; (58): 402–10.
- Fernandez H, Eller G, Paillacar J, Gajardo T, Riquelme A. Toxigenic and invasive capacities: possible pathogenic mechanisms in *Arcobacter cryaerophilus*. *Mem Inst Oswaldo Cruz.* 1995; (90): 633–4.
- Ho HTK, Lipman LJA, Hendriks GCJ, Tooten PCJ, Ultee T, Gaastra W. Interaction of *Arcobacter* spp. with human and porcine intestinal epithelial cells. *FEMS Immunol Med Microbiol.* 2007; (50): 51–8.
- Musmanno RA, Russi M, Lior H, Figura N. *In vitro* virulence factors of *Arcobacter butzleri* strains isolated from superficial water samples. *New Microbiol.* 1997; (20): 63–8.
- Gugliandolo C, Irrera GP, Lentini V, Maugeri TL. Pathogenic *Vibrio*, *Aeromonas* and *Arcobacter* spp. associated with copepods in the Straits of Messina (Italy). *Mar Pollut Bull.* 2008; (56): 600–6.
- Johnson LG, Murano EA. Lack of a cytolethal distending toxin among *Arcobacter* isolates from various sources. *J Food Prot.* 2002; (65): 1789–95.
- Houf K, Stephan R. Isolation and characterization of the emerging foodborne pathogen *Arcobacter* from human stool. *J Microbiol Methods.* 2007; (68): 408–13.
- Adesiji YO, Oloke JK, Amisu KO, Coker AO. *Arcobacter* adherence, invasion and cytotoxic effect on human carcinoma cell. *Tropical Journal of Health Sciences.* 2011; 18(11): 55–9.
- Wesley IV, Miller GW. *Arcobacter*: an opportunistic human food-borne pathogen? W. M. Scheld, M. L. Grayson, J. M. Hughes (eds.), *Emerging Infections* 9. ASM Press, Washington, DC. 2010: 185–211.
- Collado L, Figueras MJ. Taxonomy, epidemiology, and clinical relevance of the genus *Arcobacter*. *Clin Microbiol Rev.* 2011; (24): 1: 74–192.
- Tsang RS, Luk JM, Woodward DL, Johnson WM. Immunochemical characterization of a haemagglutinating antigen of *Arcobacter* spp. *FEMS Microbiol Lett.* 1996; (136): 209–13.
- Adesiji YO, Oseni BSA, Oloke JK, Coker AO. Haemagglutination assay of some human and animal *Arcobacter* species. *Tropical Journal of Health Science.* 2010; (17): 25–31.
- Wesley IV, Baetz AL, Larson D. Infection of cesarean-derived colostrum-deprived 1-day-old piglets with *Arcobacter arcobacter*, *Arcobacter cryaerophilus*, and *Arcobacter skirrowii*. *Infect Immun.* 1996; (64): 2295–9.
- Wesley IV, Baetz AL. Natural and experimental infections of *Arcobacter* in poultry. *Poult Sci.* 1999; (78): 536–45.

20. Logan EF, Neill SD, Mackie DP. Mastitis in dairy cows associated with an aerotolerant *Campylobacter*. *Vet Rec.* 1982; (110): 229–30.
21. de Oliveria SJ, Wesley IV, Baetz AL, Harmon KM, Kader II, de Uzeda M. *Arcobacter cryaerophilus* and *Arcobacter arcobacter* isolated from preputial fluid of boars and fattening pigs in Brazil. *J Vet Diagn Invest.* 1999; (11): 462–4.
22. Ho TKH, Lipman LJA, Van der Graaf-van Bloois, van Bergen M, Gaastra W. Potential routes of acquisition of *Arcobacter* species by piglets. *Vet Microbiol.* 2006; (114): 123–33.
23. Diemer T, Ludiwig M, Huwe P, Buchanan H, Dale W, Wolggary B. Influence of Urogenital on sperm function. *Current Opinion in Urology.* 2000; (10): 39–44.
24. Ho TKH, Lipman LJA, Gaastra W. *Arcobacter*: what is known about a potential food-borne zoonotic agent. *Vet Microbiol.* 2006; (115): 1–13.
25. Obeley RE, Goss KL, Quintar AA, Maldonado CA, Snyder JM. Regulation of surfactant protein D in the rodent prostate. *Repr Biol Endocrinol.* 2007; (5): 42–5.

Yemisi Olukemi Adesiji, Benjamin Obukowho Emikpe,  
Ahmed Bayo Opalekunde

#### **ARCOBACTER BUTZLERI INFEKUOTŲ ALBINOSIŲ ŽIURKIŲ HISTOPATOLOGINIAI IR FUNKCINIAI SĖKLIDŽIŲ POKYČIAI**

##### *Santrauka*

**Įvadas.** *Arcobacter butzleri* infekcija yra plintanti enteropatogeninė zoonozė, susijusi su naminių gyvulių spontaniniais abortais, viduriavimu ir mastitais.

**Medžiaga ir metodai.** Trisdešimt sveikų albinosų patinų žiurkių buvo apkrėsti *Arcobacter butzleri* ( $10^8$  cfu/ml) infekcija, išskirta iš sveikų kiaulių išmatų, siekiant nustatyti *A. butzleri* infekcijos poveikį žiurkių sėklidžių histologijai ir spermatogenezei.

**Rezultatai.** *A. butzleri* sveikoms žiurkėms sukėlė sėklidžių degeneraciją, susijusią su spermatozoidų kiekiu ir judrumu.

**Išvados.** Šio tyrimo rezultatai leidžia teigti, kad *A. butzleri* sukelia sėklidžių degeneraciją, stabdo spermatogenezę albinosėms žiurkėms, tačiau šios infekcijos poveikis nevaisingumui gyvulių pramonėje ir ekonominė nauda dar turi būti tiriama.

**Raktažodžiai:** *Arcobacter butzleri*, sėklidžių degeneracija, nevaisingumas, patogeniškumas, spermatozoidų kiekis, albinosės žiurkės