

Differentiated chondrosarcoma, originated in thyroid cartilage of larynx: evaluation and treatment. Clinical case presentation

Linās Pocius,

Vytautas Čepulis

*ENT, Head and Neck Surgery
and Oncology Division,
Institute of Oncology,
Vilnius University*

Background. The goal of our clinical case presentation is to introduce evaluation and treatment of rare head and neck tumor, the laryngeal chondrosarcoma (CS). Despite disease origin being properly suspected at the early management of our patient, the final outcomes tend to be just satisfactory because too many cofactors have had a strong influence on the course of disease.

Materials and methods. In this case, we described applied investigations and chosen tactics of treatment to our patient in a chronological manner, some immediate results, but also remote consequences of the management of this disease.

Results. In our opinion, outcome in this patient's case was predicted not just by the biology of malignancy itself, but also by some specific qualities of the tumor and even misinterpretations of instrumental examination at the moment of making decisions regarding the initial treatment; moreover, some solutions, corrected by the patient himself, maybe played an important role in the clinical course further. We want to point out how achieved results and outcomes could be unpredictable, under influence of near coincidence of fate, and different, in comparison with the cases described in the majority of the literature.

Conclusions. 1. Relatively simple diagnostic with contemporary features, plenty of modern surgical treatment possibilities or even combined therapy in complicated cases – it makes no difficulties for management of typical chondrosarcoma of the larynx, yet sometimes tricky findings when evaluating the disease and an unpredictable or surprising course of treatment and continuation make this rare kind of head and neck malignancies really special. 2. RT neither chemotherapy are recommended therapeutic options, except some rare individual cases. 3. Conservative surgery tends to be adequate if made properly and in time, it obviously ensures long-term remission or cancer-free life.

Key words: larynx, head and neck, thyroid cartilage, chondrosarcoma, hoarseness, radiotherapy, laryngectomy

INTRODUCTION

Only 2–5% of all chondrosarcomas arise in the head and neck, where the majority of them develops in the maxilla, but other typical localisations include the nasal septum, voice box, and another parts of the skull. CS of the larynx is a rare pathology, approximately from 0.07% and up to 0.2% (or up to 1% by others) of all head and neck malignancies, although it is the most common mesenchymal origin neoplasm of the larynx. More frequent location is the posterior lamina's internal surface of the cricoid, almost 80% of the cases of laryngeal CS; the thyroid cartilage, especially the inferolateral wall, is affected in about 20% of cases respectively, followed by the arytenoid cartilage. Vocal cords, hyoid bone and the epiglottis go last by frequency. Mixed mode, when more than one cartilage are involved, has a place too (1, 2, 10, 11). In our case, patient's tumor was located in the thyroid cartilage and it suggested thoughts about thyroid gland cancer, and maybe this fact was crucial for all following course of the disease.

CASE REPORT

73 y. o. male, smoker in the past, with bulky mass on the left side of the neck, which increases during the last two months. At palpation it felt like a rigid lump up to 4 cm in Ø in the thyroid's left lobe. The tumor was firmly attached to the trachea and they moved as one together. Palpation was painless. FNA from the tumor on the left side neck: cystic degeneration conclusion was made. Repeated cyto-

logical investigation: sample matches chondrosarcoma morphology. The patient underwent a detailed examination and treatment in the hospital. Clinical diagnosis as stated: *Chondrosarcoma laryngis in suspitio. Ca glandulae thyroideae in suspitio*. Computed tomography (CT) scan findings: the right lobe of the thyroid with heterogenic density nodes. The left lobe presents 23 × 26 × 32 mm, node with indistinct contours within. Destructive invasion to cartilages and penetration to 18 mm length segment of the trachea. Concluded: tumor of the thyroid gland. It invades the left part of the thyroid cartilage and trachea (Fig. 1).

Thyroidectomy and anterolateral resection of the larynx were performed under general anesthesia. Histology findings: chondrosarcoma, G1, non classified otherwise. Final diagnosis of chondrosarcoma of laryngis was stated. *Struma diffusa et nodosa lobi dextri III°* – as accompanying disease. After primary healing of the wound, the patient was redirected to internist for hypothyreosis correction, also directly to radiotherapist in order to conclude tactics regarding adjuvant 3D gamatherapy. MRI study was performed for the purpose of updating imaging of pathological changes. Found: tumor 21 × 10 mm in size, infiltrating *m. infrahyoideus sin.* (Fig. 2), the left part of the thyroid cartilage and the left vocal cord. Due to patient's disagreement for more radical surgery, radiotherapeutic treatment was planned, meant 70 Gy to the larynx as 2 Gy per day, and 50 Gy to the regional lymphonodes. Again, due to patient's individual characteristics, when 16 Gy was reached, he refused to continue irradiation, referring to

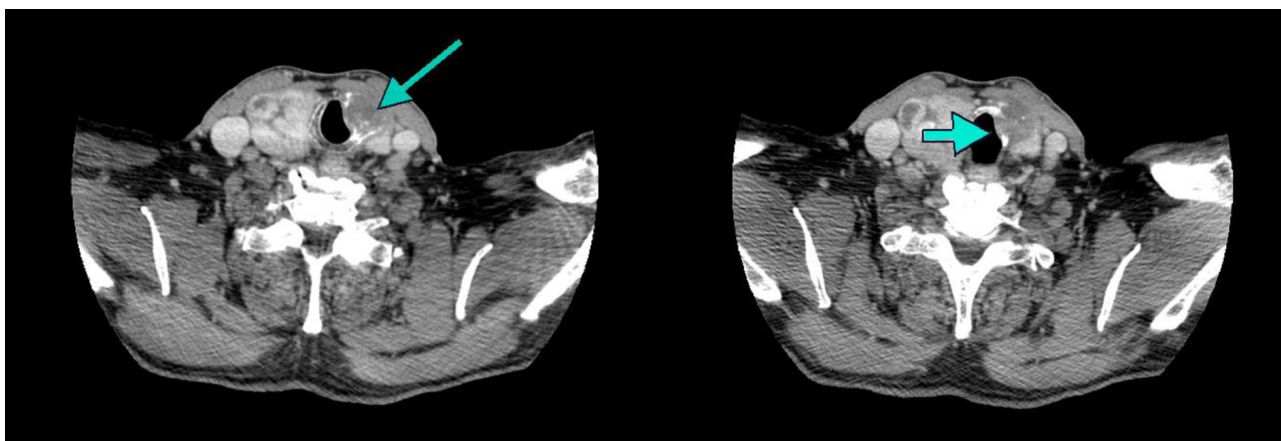


Fig. 1. CT scan slices (left – near infracricoid level, right – trachea level, deformation of trachea's opening is seen)

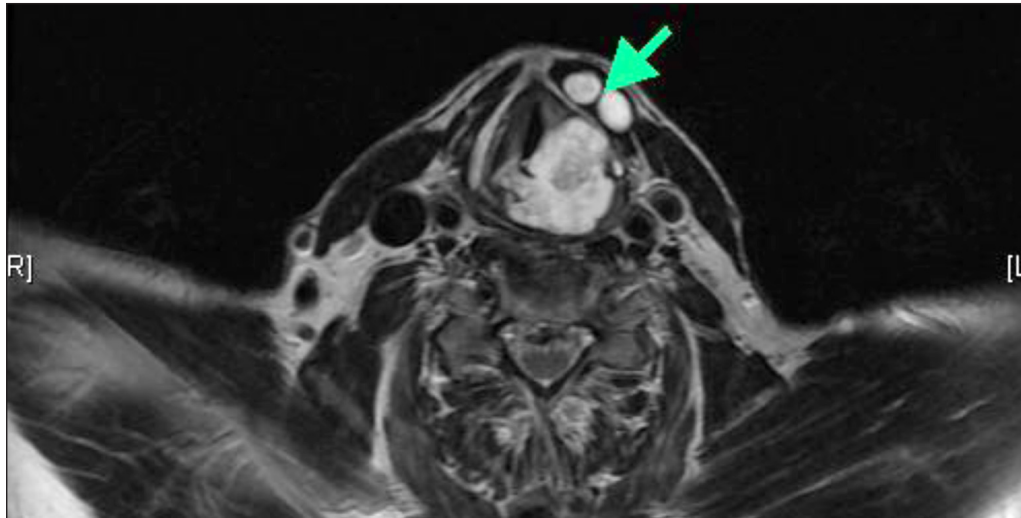


Fig. 2. CS in the left side of the thyroid cartilage as it appears in MRI. Two round shaped neoplasms shown by an arrow are metastases inside the muscle

individual intolerance. Follow-up was recommended, and laryngectomy in case the patient will change his mind. Almost 4 months after primary operation, the patient appears with complaints for hoarseness of voice and some difficulty of breathing, also recurrent lump in the neck. MRI investigation was performed. Description: tumor mass in the left true vocal cord $27 \times 36 \times 53$ mm in size, with signs of necrosis, infiltration tends to the thyroid cartilage, deformed and narrow glottic space. Two metastases in the region of the left infrahyoid muscle, 11 and 12 mm in size, respectively. Masses reach the cervical vertebrae. They reach *a. carotis communis sinister* at the middle portion, although without signs of involvement. Two me-

tastases up to 1.5 cm in \varnothing with the same structure as in the case of vocal cord appear laterally to the Adam's apple. US investigation indicates a tumor 4.0×1.9 cm in size, instead of the thyroid in the left and calcification within (Fig. 3).

Total laryngectomy was performed (Fig. 4). Morphology: well differentiated (G1) laryngeal chondrosarcoma PT1. Close margin of resection. According to histological findings, as additional option for possible prolongation of recurrence-free course of illness, adjuvant irradiation was offered for the patient. He decided by himself not to proceed. To date no further progress has ever been marked in the person's record at the outpatient clinic.

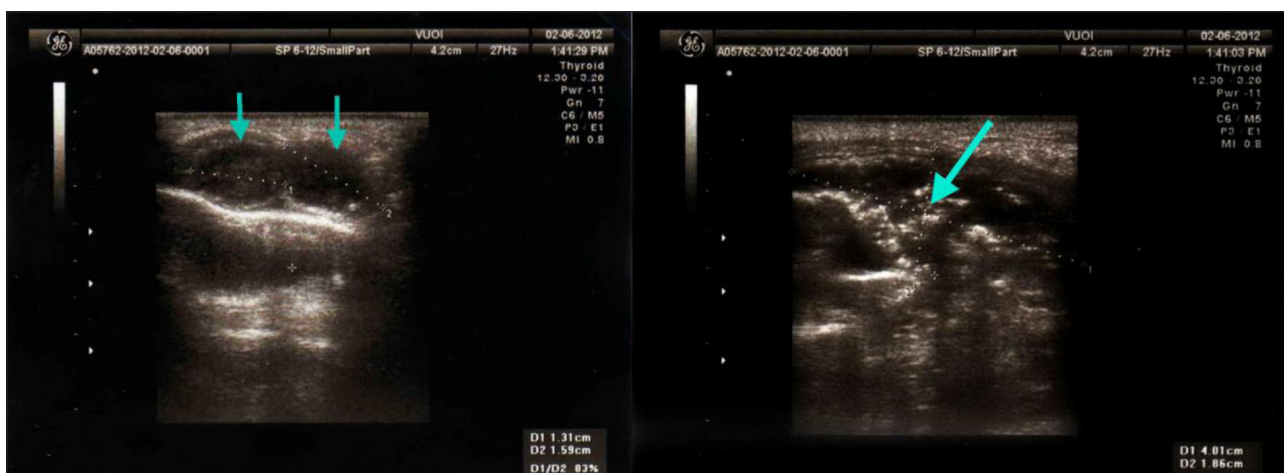

Fig. 3. Ultrasound assesment images: metastases in the region of the left infrahyoid muscle (left) and tumor of the larynx (right)

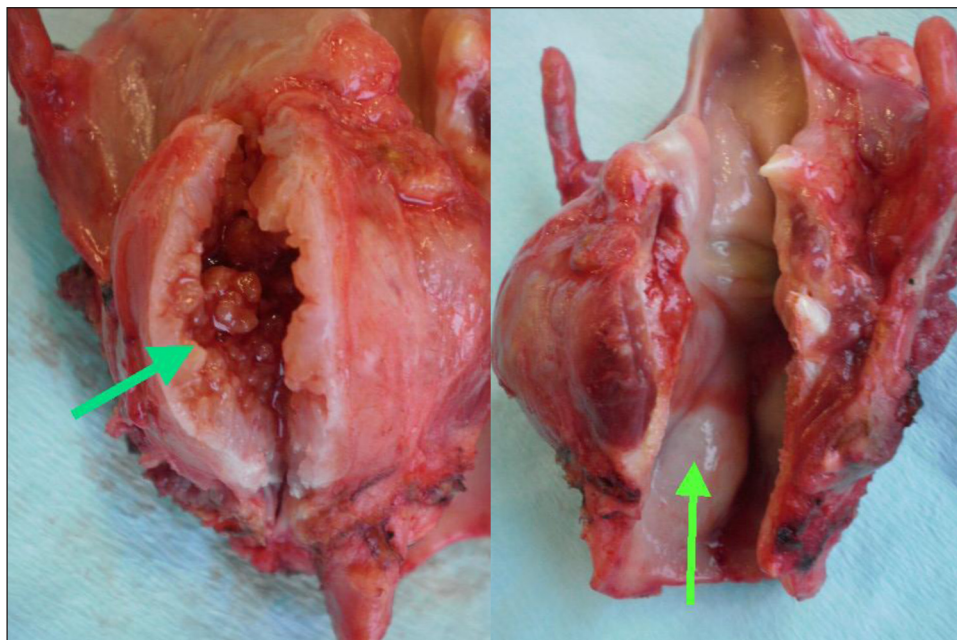


Fig. 4. Dissected tumor mass in the right side of the thyroid cartilage of the larynx (left) and prominence of the tumor mass in the laryngeal space (right)

DISCUSSION

Patients with laryngeal CS present with a variety of symptoms as a result of tumor growth, including dyspnea, dysphagia, hoarseness, airway obstruction, even stridor, or pain, but mostly – hoarseness and difficulty in breathing; these are the principal symptoms, as usually, lasting for about 2 years. Vocal cord stiffness is observed due to impact of the cricoarytenoid articulation, but not because of lesion of the recurrent nerve (2).

Men are affected more frequently than women, usually during middle to later decades of life. The male to female ratio is from 3 : 1 to as high as 10 : 1. Chondrosarcomas mostly occur between 40–80 years of age with a peak in the seventh decade of life. The mean age at diagnosis is between 64 and 66 years usually, thus coinciding with the maximum cartilage ossification. The ossification of the laryngeal cartilage starts at the insertion sites of the laryngeal muscles, that is why middle line, or axial, location is so common (1, 2, 3).

No definitive etiology for laryngeal CS is known, although the most commonly accepted version is an initial disordered ossification of the laryngeal cartilages. In many cases, ossification was found in the hyaline cartilages, which usually ossify in adult persons. The peak age at initial presentation of la-

ryngeal CS coincides with the time when cartilage ossification is most likely to be present.

Among etiologic factors, ionizing radiation takes a significant part. Many authors describe evolution of the tumor on background of multiple trauma and operations (11).

Probably the tobacco abuse has influence on development of CS, even if two thirds of patients do not have this habit in anamnesis. Eventually, there was no smoking dependence or alcohol abuse revealed. It may come in association with other neoplasm (spindle cell sarcomatoid carcinoma). Cases of transformation of chondroma to CS during a long period of time has a place in history, too. Ischemic changes in chondroma subjected to mechanical trauma may be a precursor to malignisation or a more aggressive biologic behavior. Frequent association of chondroma and chondrosarcoma supports this theory. Studies revealed that it may reach 60.4% coincidence rate (2).

Teflon injections and irradiation are yet another observed reason amongst others, if no attention is paid on the fact that no previous radiation was identified in the majority of cases reported in the literature (2).

The differential diagnosis for CS of the larynx in practice is limited to chondroma, chondrometaplasia, and tracheopathia osteoplastica. In general,

laryngeal chondromas are considered exceedingly rare, even it is postulated that all laryngeal chondromas can be erroneous descriptions of low-grade CS. It is assumed that it is due to 'bad' or 'poor' sampling of the tumor. Rare examples of other sarcomas have been described in the larynx and hypopharynx, such as liposarcoma, osteosarcoma, angiosarcoma, synovial sarcoma, malignant fibrous histiocytoma, Kaposi's sarcoma, leiomyosarcoma (5, 9).

CS are characterised by a low tendency to spread further to regional lymph nodes. But rarely additional aggressive mesenchymal components may develop in the lesion. High-grade tumours tend to be more associated with higher recurrence rate. Larger studies report an overall recurrence rate of 16% to 18% (18–40 percents by others). The recurrence development is more expectable if the primary neoplasm was excised partially or so-called "close margin" surgical situation happens; recurrent laryngeal CS does not affect the overall patient outcome. The curative potential of total laryngectomy after recurrent laryngeal CS is comparable to that of initial radical surgery. Interesting, but partial laryngectomy, if properly made, equates to total without any advantages of the last. Tumour-related fatal outcomes are occasional and happen when relapses with unpredictable growth or involvement of nearby greater vessels and aggressive spreading proceed. Metastases, most common in the lung, bone and liver, are described in about 2% to 10% of the reported cases of laryngeal CS (4). The 5-year survival rate is 90%, while the 10-year survival rate decreases to 80.9%. In contrast to the good prognosis of laryngeal CS, a rapid clinical course with tumour-related death within 2 years was reported in the literature (2, 11).

Diagnosis is based on morphological findings, and histopathology takes an exclusive role in diagnosing CS (4, 12). Histologically, chondrosarcoma can be classified as grade 1, grade 2, or grade 3. The major part of them will be equated to low grade or intermediate grade tumors.

CT scanning of the neck with contrast is the standard method of evaluating CS of the larynx, simultaneously allowing preoperative planning – and that is yet another advantage of CT. A calcified mass extensively involving one or more cartilages of the larynx or trachea that moderately

enhances after the application of contrast medium, "popcorn-like" calcification within the tumour are typical changes in case of laryngeal CS. Often seen is the displacement of surrounding structures rather than invasion, due to the slow growing manner of this tumor (2).

Ultrasound investigation can be useful if doubtful abnormalities in the neck regions are suspected, for example, magnification of groups of lymph nodes is visible in MRI or CT scan series during examination.

Modern treatment guidelines assume surgery as treatment of choice. Adequate conservative surgery must allow eradication of the cancer within safe margins. Wide surgical excision is the principal goal. Seeking acceptable functional results always is the aim, especially when lesion exceeds not more than half of cricoid's perimeter, and if histological grade is low. At least, the extent of resection to ensure control depends on the site, size and wideness of the lesion – debulking alone, hemi- or partial laryngectomy – they all can be certainly adequate. Attention should be given to resection of the external perichondrium. Salvage laryngectomy becomes necessary if the cancer is larger, comes with infiltration to surrounding tissues and cannot be organ-sparing surgery applied anymore, or when recurrence occurs, as RT fails, and whenever the grade of malignancy is high. In that way, cure rates reach more than 90% (1, 5).

The role of radiotherapy (RT) is uncertain, even controversial, because these CS rarely respond to radiation treatment (6); most of postulates address to negligible sensitivity to rays. The mechanisms still remain enigmatic. An interesting experiment was described by a group of researchers, the point was to examine hypothesis that p16(ink4a) plays a role in the mechanism of radiation resistance. Restoring p16 expression should improve the radiation sensitivity of human CS (7). There was a study involving 12 cases that showed long-term remission following irradiation in only two of the patients. Anyway, the lack of RT application limited the options for eradication of these tumors. Thus, RT as a primary treatment should be performed exclusively on undifferentiated CS, or as post-operative adjuvant treatment. It should be offered in cases of well differentiated chondrosarcoma of the larynx, when radical surgery is impossible or for residual disease. On the other hand, even positive results with

single radiation treatment 60–70 Gy is documented. Some authors obtained good local control by that way, counting 3 years, with a combination of neutrons and photons. Dailiana T. and others describe a case where RT was used because radical surgery was limited due to unavoidable severe cosmetic and functional impairment to the larynx. CT and direct laryngoscopy were used for early detection of recurrence or metastases. RT alone resulted in long-term remission of the tumour for more than 3 years (8, 10).

Laryngeal CS does not respond to chemotherapeutic agents. Doxorubicin, cyclophosphamide, dacarbazine, and vincristine have demonstrated no efficacy. Much fewer data exist regarding CTX for sarcoma of the larynx (2). That is why we have not ever made any offer for conservative drug treatment to our patient.

CONCLUSIONS

Relatively simple diagnostic with contemporary features, plenty of modern surgical treatment possibilities or even combined therapy in complicated cases – it makes no difficulties for management of typical chondrosarcoma of the larynx, yet sometimes tricky findings when evaluating the disease and an unpredictable or surprising course of treatment and continuation make this rare kind of head and neck malignancies really special.

RT as well as chemotherapy are not recommended for therapeutic options, except some rare individual cases.

Conservative surgery tends to be adequate if made properly and in time, it obviously ensures long-term remission or cancer-free life.

Received 2 November 2012

Accepted 23 November 2012

References

1. Policarpo M, Taranto F, Aina E, Valletti PA, Pia F. Condrosarcoma della laringe: caso clinico. *Acta Otorhinolaryngo*. 2008; 28: 38–41.
2. Sauter A, Bersch C, Lambert KL, Hómann K, Naim R. Chondrosarcoma of the larynx and review of the literature. *Anticancer Res*. 2007; 27: 2925–30.

3. Osamu S, Curtin HD, Faquin WC, Fabian RL. Case report: Dedifferentiated chondrosarcoma of the larynx. *AJNR Am J Neuroradiol*. 2000; 21: 584–6.
4. Thompson L, Gannon F. H. Chondrosarcoma of the larynx: a clinicopathologic study of 111 cases with a review of the literature. *Am J Surg Pathol*. 2002; 26(7): 836–51.
5. Kardesa A, Slootweg PJ. *Pathology of the head and neck*. Germany: Springer-Verlag; 2006. 338 p.
6. Berry S, Addams-Williams J, Khalil H, Armstrong S, Denton K, Baldwin D. Chondrosarcoma of the larynx. *Internet J Otorhinolaryngol*. 2003; 2(2): 28.
7. Moussavi-Harami F, Mollano A, Martin JA, Ayoob A, Domann FE, Gitelis S, Buckwalter JA. Intrinsic radiation resistance in human chondrosarcoma cells. *Biochem Biophys Res Commun*. 2006; 346(2): 379–85.
8. Dailiana T, Nomikos P, Kapranos N, Thanos L, Papathanasiou M, Alexopoulou E, et al. Chondrosarcoma of the larynx: treatment with radiotherapy. *Skeletal Radiol*. 2002; 31(9): 547–9.
9. Lalwani AK. *Current Diagnosis and Treatment in Otolaryngology – Head and Neck Surgery*. 3rd ed. New York: McGraw Hill Medical; 2012. 1013 p.
10. Mokhtari S, Mirafsharieh A. Clear cell chondrosarcoma of the head and neck. *Head Neck Oncol*. 2012; 4: 13.
11. Bulanov DV, Sergeev SA, Kuzmin IW, Semenov LA, Mahson AN, Bulycheva IW. Clinical and morphological features of laryngeal chondrosarcoma. *Arch Pathol*. 2007; 6(69): 50–2.

Linus Pocius, Vytautas Čepulis

GERKLŲ SKYDINĖS KREMZLĖS CHONDROSARKOMA: DIAGNOSTIKA IR GYDYMAS

Santrauka

Įvadas. Pristatydami šį klinikinį atvejį apžvelgiame reto gerklų naviko – skydinės kremzlės chondrosarkomos – diagnostikos ir gydymo aspektus. Nors buvo anksti nustatyta naviko morfologinė kilmė, tolesnę ligos gydymo eigą ir tik patenkinamą galutinį rezultatą lėmė ir kitos svarbios aplinkybės, tiesiogiai nesusijusios su gydymu.

Medžiaga ir metodai. Straipsnyje nuosekliai aprašomi ligoniui, sergančiam gerklų CS, taikyti tyrimai, pasi-

rinkta gydymo taktika ir jo eiga, taip pat iš karto gauti ir vėlesni gydymo rezultatai.

Rezultatai. Mūsų manymu, šiuo atveju ligos baigtį lėmė ne tik naviko biologija, bet ir esminį poveikį jos eigai turėjusi parinkta gydymo taktika, kuriai gydytojai iš dalies neturėjo įtakos. Norime pažymėti, jog vienokie ar kitokie kartais sunkiai prognozuojami rezultatai ar išeitys, kai kada išsiskiriantys iš literatūroje aprašomų atvejų statistinės daugumos, gali būti dėl atsitiktinumų ar sutapimų, pasitaikančių diagnostikos ir gydymo metu.

Išvados. 1. Santykinai paprasta, šiuolaikinėmis galimybėmis paremta diagnostika, šiuolaikinės chirurgijos laimėjimų pritaikymas, esant sudėtingiems atvejams – kartu su chemoterapija, nesudaro sunkumų gydant tipinę gerklų chondrosarkomą. Kartais dėl neaiškių radinių betiriant ligą, stebinančios gydymo ir ligos vystymosi eigos šie reti galvos ir kaklo navikai yra ypatingi. 2. Radioterapija ir chemoterapija nerekomenduojama, išskyrus atskirus individualius atvejus. 3. Konservatyvi chirurgija, tinkamai ir laiku atlikta, yra adekvačiausias gydymo metodas, užtikrinantis ilgalaikę remisiją ar visišką išgyjimą nuo vėžio.

Raktažodžiai: gerklos, galva ir kaklas, skydinė kremzlė, chondrosarkoma, užkimimas, radioterapija, chemoterapija, laringektomija