

Intraparotid facial nerve schwannoma: a case report

Jolita Gibavičienė,

Vytautas Čepulis

*ENT, Head and Neck Surgery
and Oncology Division,
1st Department of
Oncological Surgery,
Centre of Oncological Surgery,
Vilnius University
Oncology Institute,
Vilnius, Lithuania*

Background. Our objective is to present a very rare clinical case of intraparotid facial nerve schwannoma that clinically presented as an asymptomatic parotid tumor, mimicking pleomorphic adenoma, and was diagnosed only intraoperatively. Another purpose is to discuss diagnostic possibilities, appropriate planning for the management and predictive outcomes of surgical management.

Materials and methods. A clinical case of a patient with an asymptomatic parotid mass diagnosed as a facial nerve schwannoma intraoperatively is presented. The patient's presentation and the diagnostic procedures, surgery and the follow up procedures are discussed. A review of literature is presented.

Conclusions. Intraparotid facial nerve schwannoma is an extremely rare entity and rarely diagnosed preoperatively. Management of intraparotid facial nerve schwannomas (IFNS) is very challenging because the diagnosis is often made intraoperatively and in most cases resection can lead to severe facial nerve (FN) paralysis with significant aesthetic consequences. Imaging studies and fine-needle aspiration cytology are not always helpful in preoperative diagnosis.

Key words: parotid tumor, facial nerve schwannoma, facial paralysis

INTRODUCTION

Schwannoma is an ectodermal benign encapsulated tumor arising from Schwann cells. Neurogenic neoplasms of the facial nerve are uncommon (2). Schwannomas of the acoustic or VIII nerve are

well described. Very few originate from the facial nerve and in majority of these cases the tumor involves the intratemporal part of the facial nerve (3). The involvement of the intraparotid part of the facial nerve is extremely rare, representing approximately 10% of all cases of facial nerve schwannomas (8, 15). Its malignant degeneration is not frequent (16).

It is very difficult to diagnose intraparotid facial nerve schwannoma (FNS) preoperatively because its incidence is rare accounting for only 0.2–1.5%

Correspondence to: Jolita Gibavičienė, ENT, Head and Neck Surgery and Oncology Div., 1st Dept. of Oncological Surgery, Centre of Oncological Surgery, Vilnius University Oncology Institute, Santariškių 1, LT-08660 Vilnius, Lithuania.
E-mail: jolita.gibaviciene@vuoi.lt

of all parotid tumors and rarely produces any signs and symptoms (3). The first description of an intraparotid facial nerve schwannoma was by Ibrazi (1) in 1927, since then there have been approximately 60 reported cases of intraparotid facial nerve schwannoma in the medical literature (6).

Moreover, there is no diagnostic modality that can diagnose it with certainty. Therefore the diagnosis is generally made during operation, when the surgeon finds difficulty in locating the facial nerve and then is required to make an unexpected decision.

There is a great potential for misdiagnosis and mismanagement of these lesions with a horrible consequence of facial paralysis. It is thus critical to have a diagnostic and management algorithm when a suspected facial nerve tumor is encountered during parotidectomy.

The following case is presented because it appeared as a non-symptomatic parotid tumor with normal n. facialis function and a solid tumor, involving the facial nerve trunk, was found intraoperatively. Ultrasonography and fine needle aspiration cytology were performed. Based on investigations, a provisional diagnosis of a benign salivary gland tumor was made.

CASE REPORT

A 59-year-old lady presented with a four-year history of a gradually enlarging left parotid mass. She denied any facial weakness, twitching or pain. Tu-

mor in the parotid region was asymptomatic for 3 years. During the last year more active tumor growth was noticed.

Examination revealed 3 × 4 cm solid, non-tender, mobile mass in the middle part of the parotid gland.

Facial nerve function as the remainder of head and neck examination was normal.

Ultrasonogram (USG) showed a hypoechogenic solid tumor with small calcinates in the left parotid gland. Loco-regional lymph nodes were without pathology findings.

Fine needle aspiration cytology showed benign findings, some acinic salivary gland structures, blood elements. Based on investigations, a provisional diagnosis of a benign salivary gland tumor was made.

The case was preoperatively discussed with the patient and possible facial nerve complications were explained.

Intraoperatively after superficial parotidectomy the tumor was exposed. The tumor was well encapsulated 4 × 3.7 × 2.4 cm arising from the facial nerve trunk. (Figs. 1, 2). The tumor was dissected from the nerve. It seemed that the tumor enucleating with complete nerve preservation will be feasible. However, unsuccessfully, the facial nerve split. The tumor was removed, but the facial nerve was sacrificed. During the operation decision of immediate repair of the transected nerve was made. The problem was the loss of the nerve tissue and damage of the nerve. The facial nerve was “repaired” using

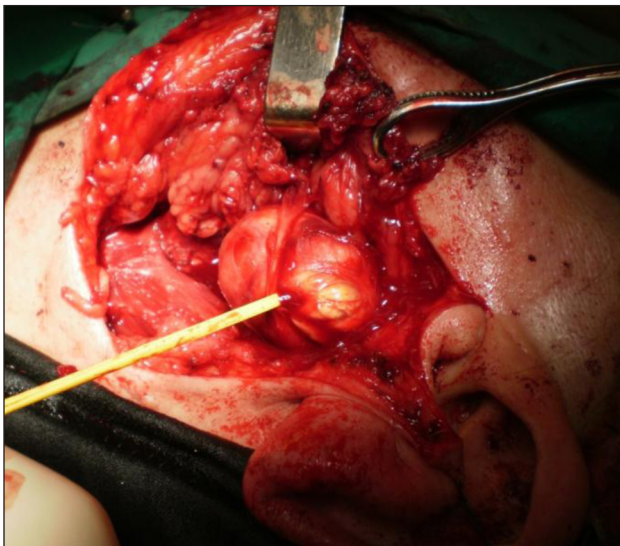


Fig. 1. Tumor in the facial nerve

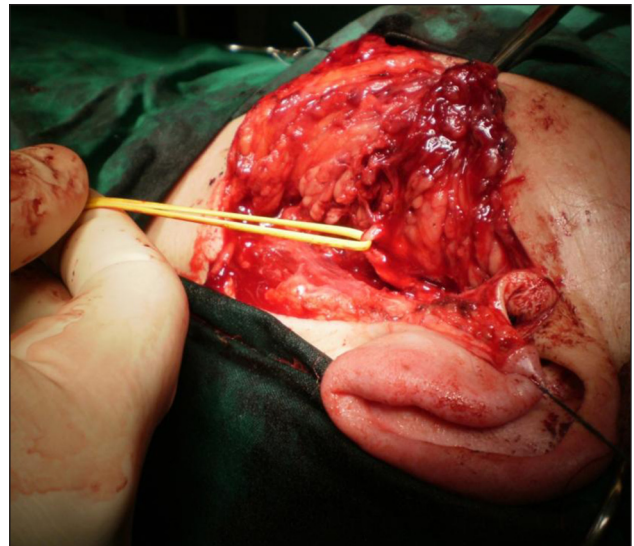


Fig. 2. Facial nerve after reconstruction

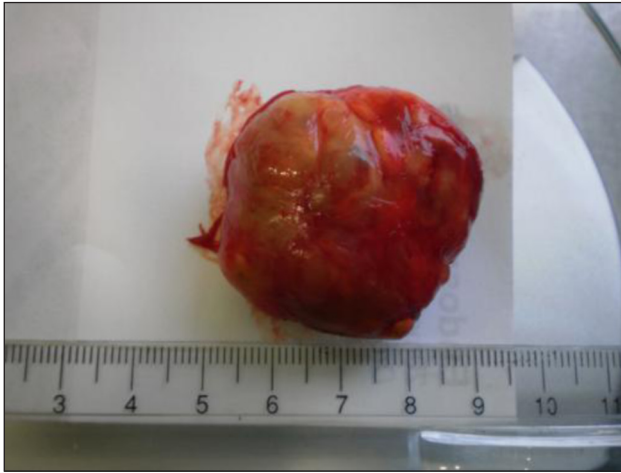


Fig. 3. Tumor – facial nerve schwannoma

end-to-end suture and tubulisation with autologous vein. Postoperatively the patient developed facial nerve palsy.

In 4 months after operation the miography test was made and showed some nerve response that means a very slow but hopeful improvement.

The histological examination revealed a benign schwannoma (Fig. 3).

DISCUSSION

N. facialis schwannomas can occur at any point of the facial nerve along its complicated anatomical course from the cerebellopontine angle to its multiple peripheral branches in the face. These benign tumors arise from Schwann cells, which envelop the facial nerve. These lesions have a predilection for the intratemporal course of the facial nerve, in particular, labyrinthine and tympanic segments (2). Neurogenic tumors of the extratemporal part of the facial nerve are less common. Extratemporally, they typically present as an asymptomatic parotid mass (3–7).

The differential diagnosis for a neurogenic tumour of the extratemporal facial nerve includes schwannoma and, less commonly, neurofibroma. Schwannomas are typically solitary and encapsulated. They tend to push axons of the nerve of the origin away and thus can potentially be resected with nerve preservation (8).

Neurofibromas, however, are typically non-encapsulated and are classified as diffuse or plexiform. Unlike schwannomas, usually they are intimately associated with the nerve, making resection

with nerve preservation difficult. Malignant degeneration has been reported in neurofibromas but is exceedingly rare with schwannomas (4).

The critical step in the management of neurogenic tumors of the extratemporal facial nerve is the diagnosis. Most of these lesions present as an asymptomatic parotid mass with or without facial weakness. Bretlau et al. (9–11) reviewed 53 cases of intraparotid facial nerve schwannomas (FNS) in the literature and found facial nerve dysfunction in 20% of patients.

Although facial nerve paralysis associated with parotid tumor suggests malignancy, the neural dysfunction due to schwannoma is attributed to a gradual compressive effect of the tumor (12).

The parotid mass is always painless and slowly increases in size, although painful lesions have been reported (8). The course could be due to distention of the parotid fascia or obstruction of the parotid duct.

It appears, therefore, that the clinical presentation is helpful only if there is a history of a slow gradual facial paresis associated with a slow-growing parotid mass.

Magnetic resonance imaging with gadolinium is the study of choice for imaging the parotid bed for suspected facial nerve lesions.

Fine-needle aspiration cytology has been widely used and accepted as a useful diagnostic procedure in head and neck lesions. The accuracy of distinction between benign and malignant tumors in salivary glands is good and exceeds 90% in most series (12). But there has been reluctance to use it for parotid gland lesions due to lack of characteristic cytological findings and exact cell type, and the fact that it is unlikely to change or facilitate treatment (13). So we can conclude that preoperative fine-needle aspiration is not always informative and diagnostic as in our case.

The diagnosis is thus typically made at the time of surgery. Given the potential for injury of the facial nerve, the surgeon must have a clear management algorithm if the facial nerve is encountered.

For those patients going for surgery, surgeon has to counsel adequately the patients and prepare them for the possibility of facial nerve sacrifice, and to discuss other rehabilitation options, such as a nerve graft. Having a preoperative diagnosis is useful in case of schwannoma because some patients, having known that it is a benign tumor, may

want to avoid surgery and its accompanying risk of facial nerve palsy. In reviewed literature almost all reported cases, including ours, had the diagnosis of schwannoma made intraoperatively. There are some recommendations concerning this controversial situation: fine needle aspiration biopsy during the operation in conjunction with pathology service or judicious biopsy during the operation (1). Retrograde dissection of facial nerve branches can be helpful if the tumor involves the main trunk of the facial nerve. Almost half of extratemporal facial nerve tumors involve the main trunk of the nerve (5).

It is interesting to note that several authors have reported the occurrence of facial paralysis when an intraparotid facial nerve tumor was simply biopsied or carefully resected with apparent preservation of the facial nerve (3, 5).

Preoperative facial nerve function is thus central to the management of these tumors.

In summary, we want to emphasize that a surgical approach of these tumors is full of controversies. There are some authors who believe that surgical resection with nerve grafting provides better results with normal preoperative facial function (5, 10). However, other authors agree that exchanging an asymptomatic parotid mass for facial paralysis is not in the patient's best interest (4, 6, 11). When conservative management is undertaken, patients with benign extratemporal FNS or neurofibromas should be followed clinically as well as radiographically with MRI.

CONCLUSIONS

Intraparotid facial nerve tumours are rarely diagnosed preoperatively. The experience of Guzzo et al. shows that 75% of the intraparotid FNS remain undiagnosed preoperatively (14).

The best plan of management is still a matter of debate but the decision should be based on the patient preference and the best facial nerve functional outcome.

A minority of the intraparotid schwannomas can be removed by resection while preserving the facial nerve. But indolent behavior and moderate results in facial nerve reconstruction (especially in elderly patients) justify a wait-and-see policy in the presence of a benign parotid facial nerve schwannoma.

Conservative management with preservation of facial nerve function should be undertaken in an asymptomatic patient with normal facial nerve function.

Received 25 October 2012

Accepted 23 November 2012

References

1. Ibrazi PL. Formas exceptionales de tumors parotideos. *An Fac Med Montev.* 1927; 12: 546.
2. Sherman JD, Dagnew E, Pensak ML. Facial nerve neuromas: report of 10 cases and review of the literature. *Neurosurg.* 2002; 50: 450–6.
3. Oncel S, Onal K, Ernete M. Schwannoma (neurilemoma) of the facial nerve as a parotid mass. *J Laryngol Otol.* 2002; 116: 642–3.
4. McGuirt WF, Johnson PE, McGuirt WT. Intraparotid facial nerve neurofibromas. *Laryngoscope.* 2003; 113: 82–4.
5. Sullivan MJ, Babyak JW, Kartush JM. Intraparotid facial nerve neurofibroma. *Laryngoscope.* 1987; 97: 219–23.
6. Mehta RP, Deschler DG. Intraoperative diagnosis of facial nerve schwannoma at parotidectomy. *Am J Otolaryng.* 2008; 29: 126–9.
7. Pasad S, Mayr EN, Kamerer DB. Neurilemoma (schwannoma) of the facial nerve presenting as a parotid mass. *Otolaryngol Head Neck Surg.* 1993; 108: 76–9.
8. Kumar BN, Walsh RM, Walter NM. Intraparotid facial schwannoma in child. *J Laryngol Otol.* 1996; 110: 1169–70.
9. Conley J, Janecka IP. Neurilemoma of the facial nerve. *Plast Reconstr Surg.* 1973; 52: 55–60.
10. Bretlau P, Melchior H, Krgdahl A. Intraparotid neurilemoma. *Acta Otolaryngol.* 1983; 95: 382.
11. Horn KL, Crumley RL, Schindler RA. Facial neurilemmomas. *Laryngoscope.* 1981; 91: 1326–31.
12. Shaha AR, Weber C, DiMaio T, Jaffe BM. Needle aspiration biopsy in salivary gland lesions. *Am J Surg.* 1990; 160: 373–6.
13. Spiro RH. Diagnosis and pitfalls in the treatment of parotid tumours. *Semin Surg Oncol.* 1991; 7: 204.
14. Guzzo M, Ferraro L, Quarttrone P. Schwannoma in the parotid gland. Experience of our institute and review of the literature. *Tumori.* 2009; 95(6): 846–51.

15. Kreft A, Schellkens PPA, Leverstein H. Intraparotid facial nerve schwannoma. What to do? Clin Otolaryngol. 2007; 32: 125–9.
16. Marchioni D, Alicandri-Ciufelli MA, Presutti L. Intraparotid facial nerve schwannoma: literature review and classification proposal. J Laryngl Otol. 2007; 121: 707–12.

Jolita Gibavičienė, Vytautas Čepulis

INTRAPAROTIDINĖ VEIDINIO NERVO ŠVANOMA: KLINIKINIS ATVEJIS

Santrauka

Darbo tikslas yra pristatyti retą klinikinį atvejį – intraparotidinę veidinio nervo švanomą. Navikas paausio seilių liaukoje priminė banalų pleomorfinės adenomos atvejį, tačiau operacijos metu buvo aptiktas ir iš dalies sėkmingai pašalintas veidinio nervo kamieno navikas. Straipsnyje apžvelgta literatūra, aptartos ir įvertintos šio reto naviko priešoperacinės diagnostikos galimybės, operacijos rizika ir numatyta operacijos baigtis.

Mūsų klinikoje buvo operuota 59 metų pacientė dėl sparčiai didėjančio paausio seilių liaukos naviko. Operacijos metu paaiškėjo, kad navikas išaugo iš veidinio nervo kamieno. Ikioperaciniai tyrimai buvo neinformatyvūs. Kadangi buvo pažeistas veidinio nervo kamienas, operacijos metu, panaudojant autoveną, buvo atlikta nervo plastika.

Literatūros duomenimis, veidinio nervo kamieno švanoma labai retai diagnozuojama iki operacijos, nes diagnostikai naudojami tyrimai nėra specifiniai. Dėl galimo negrįžtamo veidinio nervo pažeidimo šio naviko šalini- mo operacija yra iššūkis chirurgui.

Raktažodžiai: paausio liaukos navikas, veidinio nervo kamieno švanoma, veidinio nervo parėzė