

Diffuse descending necrotizing mediastinitis: surgical treatment and outcomes in a single-centre series

Ričardas Janilionis¹,

Žymantas Jagelavičius¹,

Pavel Petrik¹,

Gintaras Kiškis¹,

Vytautas Jovaišas¹,

Algis Kybartas¹,

Arūnas Žilinskas¹,

Irena Liubertienė¹,

Giedrius Navickas²,

Ramūnas Valančius³

¹Centre of General Thoracic Surgery,
Vilnius University Hospital,
Vilnius, Lithuania

²Centre of Anaesthesiology, Intensive
Therapy and Pain Management,
Vilnius University Hospital,
Vilnius, Lithuania

³Centre of Radiology and
Nuclear Medicine,
Vilnius University Hospital,
Vilnius, Lithuania

Objectives. Descending necrotizing mediastinitis is a severe infection spreading from the cervical region to the mediastinum. Since this pathology is uncommon, only a few reports of large series of patients with descending necrotizing mediastinitis have been published. The present aim was to evaluate our treatment strategy and survival for this disease by a retrospective chart review.

Methods. Retrospective analysis of 45 cases with descending necrotizing mediastinitis was performed between 2002 and 2011. The mean age was 55.3 ± 15.4 years. The primary oropharyngeal infection was found in 16 (35.6%), an odontogenic abscess in 17 (37.7%) and other causes in 12 (26.7%) patients. Endo type I mediastinitis was assessed in 25 (56%) patients, Endo type IIA in 10 (22%) and Endo type IIB in 10 (22%) patients. Broad spectrum antibiotics were administered empirically and surgical treatment consisting of cervical drainage, thoracotomy with radical surgical debridement of the mediastinum and placement of permanent mediastinal irrigation were performed in all the cases.

Results. Collar incision and drainage only were performed in 16 (35.6%) patients, whereas only transthoracic approach was used in five cases (11%). In the remaining 24 (53.4%) patients cervical drainage and thoracic operation were performed. Fifteen patients had severe complications: septic shock, multiple organ failure and haemorrhage from mediastinal vessels. The median hospital stay was 21 days. The outcome was favourable in 35 patients. Ten patients died (overall mortality 22.2%).

There was a negative correlation between the time from the onset of symptoms till the first admittance to hospital and hospitalization time (Pearson correlation coefficient 0.357, $p = 0.016$). That allows us to suggest that time of illness spent at home without appropriate treatment plays a crucial role on the survival. It was found that younger age, Endo type I, negative bacterial culture and longer hospital stay are true precursors of favourable outcome.

Conclusions. For descending necrotizing mediastinitis limited to the upper part of the mediastinum a transcervical approach and drainage may be sufficient. However, in advanced cases an immediate and more aggressive surgical approach is required to combat a much higher morbidity and mortality in this subset of patients.

Key words: descending necrotizing mediastinitis, cervicotomy, thoracotomy, mediastinotomy, mediastinal irrigation

INTRODUCTION

Acute suppurative mediastinitis is a severe infectious condition. The term *descending necrotizing mediastinitis* (DNM) refers to an infection that begins in the oropharyngeal region and spreads through the fascial planes into the mediastinum or even into the pleural cavity. The predominant underlying oropharyngeal infection is of odontogenic origin. This is a particularly virulent form of infection. The description of anatomical routes was performed by Pearse as early as in 1938 (1). He was the first to identify a group of patients whom he called "secondary to cervical suppuration".

The criteria for diagnosing DNM were formulated by Estrera and associates in 1983 (2). These include: (1) clinical evidence of severe infection; (2) demonstration of characteristic X-ray findings; (3) verification of the necrotising mediastinal infection intraoperatively or postmortem, or both; (4) the establishment of a cause-effect between oropharyngeal infection and mediastinitis.

The incidence of DNM in patients with deep neck infections according to P. Boscolo-Rizzo (3) is 4.4%.

Delay of diagnosis and inappropriate drainage of the mediastinum are the main causes of mortality in this life threatening condition. DNM requires multidisciplinary approach based on ICU support, relevant antibiotic therapy and the surgical debridement of the initial infection site and mediastinum. Pearse (1) reported 110 infections having descended from the neck: 68 were operated upon with 24 fatal outcomes (a mortality of 35%), in contrast to an 85% mortality when operation was not performed. The poor prognosis could be due in part to the difficulty in establishing and maintaining adequate surgical drainage as DNM spreads among the fascial compartments of the neck and chest (1–4).

The aim of our study was to evaluate the incidence of DNM in our centre, discuss the surgical management and to evaluate the prognostic factors of survival.

MATERIALS AND METHODS

This research is based on a retrospective review of 45 patients (28 male and 17 female) with DNM in the period between 2002 and 2011. The mean age

was 55.3 ± 15.4 (range 18–83) years. Diagnosis was made by clinical findings, ultrasound and cervicothoracic radiologic investigation (X-ray and computed tomography (CT) data) in all the patients. The criteria of Estrera (2) were fulfilled in all patients. The primary oropharyngeal infection (peritonsillar, parapharyngeal and retropharyngeal abscess) was found in 16 (35.6%) patients, an odontogenic abscess in 17 (37.7%) patients, and other reasons in 12 (26.7%) patients. Broad-spectrum antibiotics were initiated in all cases empirically as soon as DNM was suspected. We identified the extent of DNM according to the classification by Endo et al. (5). Localised descending mediastinitis – type I – was localized in the upper mediastinum space above the carina; diffuse descending mediastinitis – type IIA – infection extended to the lower anterior mediastinum; diffuse descending mediastinitis – type IIB – extension of infection to both anterior and posterior lower mediastinum. Signs of mediastinal infection demonstrated by CT included: (1) mediastinal soft-tissue infiltration with gas bubbles (Fig. 1A); (2) mediastinal uncapsulated fluid collections (Fig. 1B); and (3) mediastinal abscess with fluid in the pleural cavity (Fig. 1C).

Cervical drainage was performed for all but 5 patients. In each case surgical treatment consisted of one or more collar drainages. This was followed by drainage and irrigation of the mediastinum through a thoracic approach in 24 patients. The thoracotomy with mediastinal drainage without cervical incision was performed in 5 cases.

The neck is usually approached through an incision anterior to the sternocleidomastoid muscle from one or both sides. Cervical spaces were opened, debrided of the necrotic tissue, drained, and the cervical wound was left opened (Fig. 2). In odontogenic cases submandibular and submental spaces were also opened, debridement and drainage were performed. Thoracic procedure usually included radical debridement of the mediastinum with excision of the necrotic tissue as widely as possible. Pulmonary decortication and pericardial drainage were additionally performed in some cases. The thoracic procedure was finished by placement of chest tubes. We retained 2–6 silicone tubes during the operation. Usually at least 2 tubes were placed in the mediastinum. Drainage and permanent irrigation of the mediastinum was

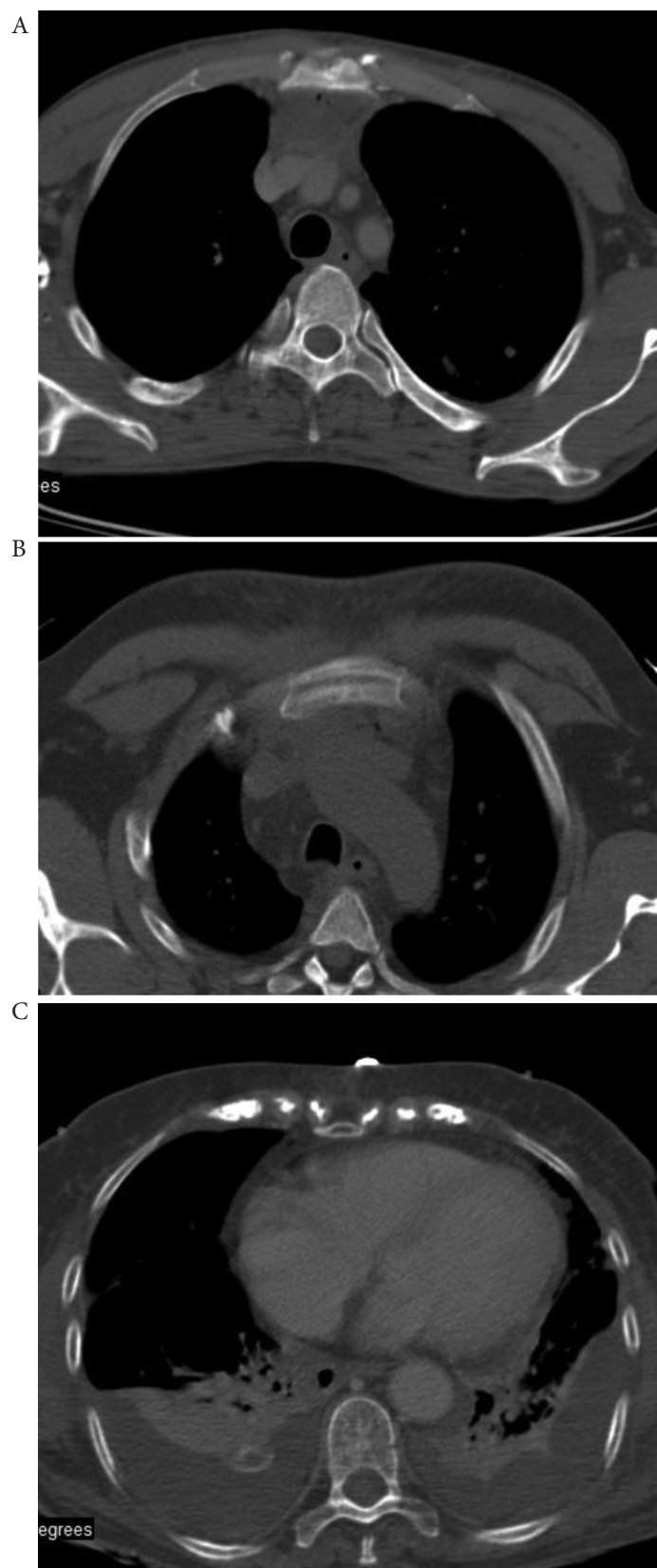


Fig. 1. Chest CT scan: A – appearance of anterior mediastinitis with retrosternal fluid collection and gas bubbles (case 32); B – mediastinal abscess in the right paratracheal area and posteriorly (case 18); C – paraaortic mediastinal abscess with fluid collections in both pleural cavities (case 25)

performed with large-bore double lumen silicone tubes using active aspiration of the contents postoperatively. In all cases negative pressure of 25 cm H₂O was used. We irrigated the distal tip of the double lumen tube and mediastinum with warm saline. Approximately 1,500–2,000 ml of saline were sufficient for 24-hour irrigation. The purpose of this manoeuvre was to prevent mediastinal tubes from occlusion by the fibrin and other debris and keep the tubes patent as long as possible. The duration of mediastinal irrigation was dependent on the clinical status and chest CT findings.

Statistical analysis was made using SPSS 17.0 for Windows (SPSS Inc. Chicago, Illinois, USA) software. If there was an abnormal distribution of variables identified, the data is presented as a median and quartile range (QR), in other cases it is presented as the mean and standard deviation (SD). The Pearson correlation coefficient was used to assess the dependence between the time from the onset of the symptoms till admittance to hospital and the overall hospital stay. The impact of different factors on survival and the need of additional surgery was calculated using logistic regression as it is shown by odds ratio (OR) and their 95% confidence interval (CI). A $p < 0.05$ has been considered to be significant.

RESULTS

Patient characteristics are shown in Table 1. Symptoms at hospitalization included: pyrexia – 45 patients (100%), neck swelling – 33 (73%), sore throat – 19 (42%), dyspnoea – 14 (31%), dysphagia – 11 (24.4%), chest or back pain – 7 (15.5%). The white blood cell count and C-reactive protein levels showed no clear correlation to the course or outcome of disease.

The foci of the inciting infections were as follows: cervical infections (retropharyngeal, peritonsillar or parapharyngeal abscesses) were in 16 patients (35.6%); odontogenic in 17 (37.7%); other reasons (incl. abscess of sternoclavicular joint in 3, unknown in 9) in 12 (26.7%). The interval between the onset

Table 1. Patients characteristics

Case	Age / Sex	Etiology	Time from onset to hospitalization, days	Time between cervicotomy and thoracotomy, days
1	69/M	Retropharyngeal abscess	4	– (C)
2	51/M	Unknown	7	2 (C+T)
3	39/M	Unknown	2	– (C)
4	34/F	Odontogenic	4	0 (C+T)
5	55/F	Parapharyngeal abscess	7	4 (C+T)
6	18/M	Odontogenic	10	– (T)
7	67/F	Retropharyngeal abscess	7	0 (C+T)
8	43/M	Peritonsillar abscess	4	0 (C+T)
9	63/F	Abscess of the sternoclavicular joint	5	– (T)
10	65/M	Parapharyngeal abscess	7	0 (C+T)
11	68/M	Odontogenic	10	8 (C+T)
12	36/M	Odontogenic	7	3 (C+T)
13	54/M	Odontogenic	9	0 (C+T)
14	45/M	Odontogenic	8	1 (C+T)
15	38/M	Odontogenic	13	– (C)
16	47/F	Abscess of the sternoclavicular joint	3	11 (T)
17	83/M	Odontogenic	14	– (C)
18	45/M	Unknown	7	– (T)
19	74/F	Odontogenic	7	3 (C+T)
20	69/F	Parapharyngeal abscess	7	0 (C+T)
21	71/M	Odontogenic	8	0 (C+T)
22	62/M	Unknown	3	– (C)
23	46/M	Odontogenic	5	– (C)
24	73/F	Parapharyngeal abscess	7	– (C)
25	56/F	Peritonsillar and parapharyngeal abscesses	7	4 (C+T)
26	53/M	Odontogenic	2	6 (C+T)
27	81/F	Unknown	8	7 (C+T)
28	36/M	Odontogenic	0	0 (C+T)
29	63/M	Parapharyngeal abscess	3	– (C)
30	71/M	Odontogenic	8	– (C)
31	54/M	Odontogenic	10	– (C)
32	39/M	Parapharyngeal abscess	14	– (C)
33	79/F	Parapharyngeal abscess	7	– (C)
34	56/F	Parapharyngeal abscess	7	16 (C+T)
35	38/F	Abscess of the sternoclavicular joint	6	– (C)
36	55/F	Parapharyngeal abscess	0	0 (C+T)
37	70/M	Unknown	5	– (C)
38	61/F	Parapharyngeal abscess	4	0 (C+T)
39	25/M	Odontogenic	5	– (C)
40	61/M	Parapharyngeal abscess	2	0 (C+T)
41	67/F	Peritonsillar abscess	2	2 (C+T)
42	71/F	Unknown	7	0 (C+T)
43	51/M	Unknown	14	– (T)
44	34/M	Odontogenic	5	– (C)
45	53/M	Unknown	3	3 (C+T)

M – male, F – female, (C) – cervicotomy, (T) – thoracotomy, (C+T) – cervicotomy plus thoracotomy.

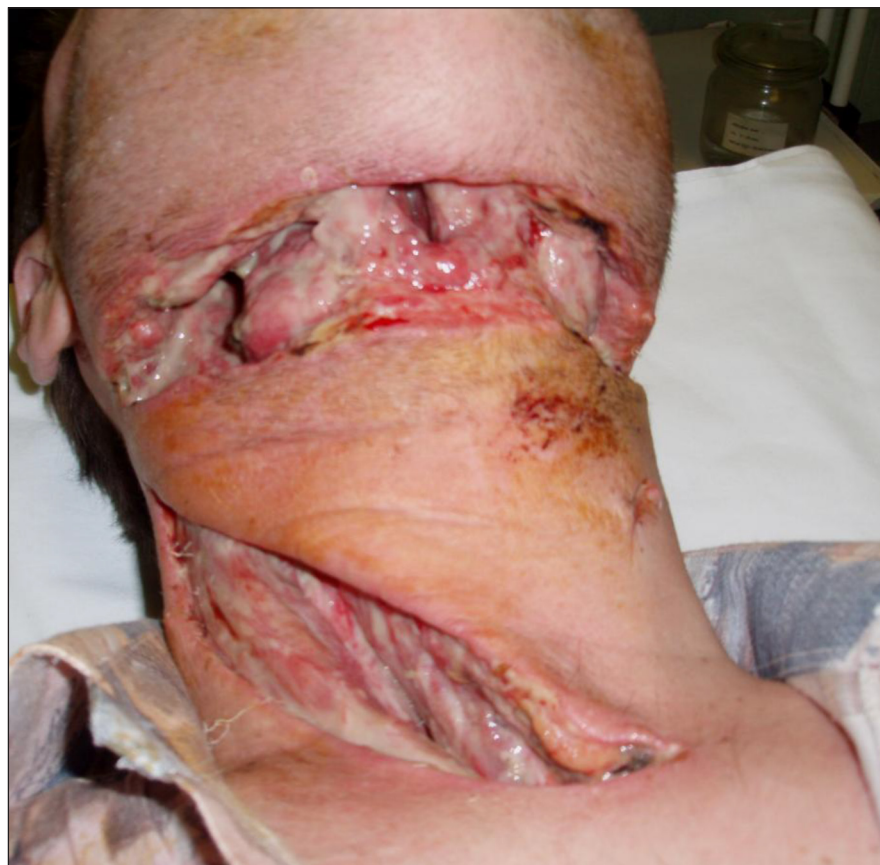

Fig. 2. Postoperative view of the cervical and submandibular area (7 days after incisions) in the patient with DNM (case 44)

of symptoms and the first admittance to hospital varied from 0 to 14 days, the median was 7 days (QR: 4–8).

In each case, the CT scan confirmed the diagnosis of descending necrotizing mediastinitis. There were 25 (56%) cases of Endo type I, ten (22%) cases of type IIA, and ten (22%) of type IIB. Collar incision and drainage only were performed in 16 (35.6%) patients, while in five cases (11%) only transthoracic approach was used. In the remaining 24 (53.4%) patients, cervical drainage and thoracic operation were performed. In 12 cases both procedures were performed at the same time. The interval between cervical drainage and thoracotomy varied from 0 to 16 days, the median was 1 day (QR: 0–4). Tracheostomy was performed in 13 (28.9%) patients, usually for the need of prolonged ventilation.

The treatment and outcomes are shown in Table 2. Broad-spectrum antibiotics were used initially and changed according to response and sensitivity tests. We often used two types of antibiotics simultaneously in order to cover aero-

bic and anaerobic bacteria. Bacterial infection was determined by fluid culture from the cervical incision or mediastinum in 33 cases. No bacterial growth was found in 12 (26.7%) cases. The growth of bacterial monoflora was identified in 16 (35.6%) cases (the original organisms were Streptococci in six cases, Enterococci in seven cases, and Pseudomonas in three cases). In 17 (37.8%) cases, aerobic and anaerobic organisms were mixed (mainly Streptococci plus Prevotella, and Staphylococci plus Bacteroides species).

Fifteen (33.3%) patients suffered from severe complications. Septic shock occurred in 11 patients, multiple organ failure in 8 cases. Haemorrhage from mediastinal vessels occurred in 3 cases.

The median duration of mediastinal tube retention was 10 days (QR: 6–17), and the median hospital stay was 21 days (QR: 11.5–30).

The outcome was favourable in 35 patients. Ten patients died (overall mortality was 22.2%). Three patients of this series who had mediastinal drainage through a thoracotomy (2) and collar approach (1) (cases 2, 30, 43) died from

Table 2. Treatment and outcomes

Case	Antibiotics	Thora- cotomy	Number of chest tubes	Duration of drainage, days	Trache- ostomy	Post-operative complication	Outcome
1	PC, AG, CP, M	None	–	–	N	None	10 POD, discharge
2	PC, M, T	Left	4	25	N	Haemorrhage	26 POD, died
3	PC, AG, CP, M	None	–	–	N	None	12 POD, discharge
4	PC, AG, CP, M, T	Left	5	17	Y	None	37 POD, discharge
5	AG, CP, M	Right	3	14	N	Septic shock, MOF	14 POD, died
6	AG, CP, M	Right	4	4	N	None	11 POD, discharge
7	AG, CP, M	Right	2	5	N	None	16 POD, discharge
8	AG, M, T	Right	3	4	N	Septic shock	30 POD, discharge
9	AG, M, T	Left	2	14	N	None	23 POD, discharge
10	PC, CP, M	Left	2	6	N	None	21 POD, discharge
11	CP, M	Left	2	6	Y	None	23 POD, discharge
12	AG, CP, M	Right	4	17	N	None	26 POD, discharge
13	PC, AG, CP, M	Right	2	12	Y	None	17 POD, discharge
14	PC, AG, CP, M, V, Q	Right	3	18	Y	Septic shock, MOF	47 POD, died
15	PC, AG, M	None	–	–	N	None	20 POD, discharge
16	PC, M	None	3	7	N	None	30 POD, discharge
17	PC, AG, CP, M	None	–	–	N	MOF	6 POD, died
18	AG, T	Right	3	24	Y	Septic shock, MOF	48 POD, discharge
19	PC, AG, CP, M	Right	2	7	Y	Septic shock, MOF	43 POD, died
20	AG, CP, M	Right	4	5	N	None	14 POD, discharge
21	AG, CP, M	Left	2	3	N	MOF	3 POD, died
22	AG, CP, M	None	–	–	N	None	16 POD, discharge
23	AG, CP, M	None	–	–	N	None	25 POD, discharge
24	AG, CP, M, Q	None	–	–	Y	None	35 POD, discharge
25	AG, CP, M	Right	3	7	N	None	21 POD, discharge
26	AG, CP, M, Q	Left	4	10	N	Septic shock, MOF	47 POD, discharge
27	PC, CP, M	Right	3	4	N	Septic shock, MOF	11 POD, died
28	AG, CP, M, V, T, Q	Right	3	19	Y	Septic shock, MOF	46 POD, discharge
29	AG, CP, M	None	–	–	Y	Septic shock, brain ischemia	21 POD, discharge
30	PC, AG, CP, M, Q	None	–	–	N	MOF, haemorrhage	21 POD, died
31	AG, CP, M	None	–	–	N	None	11 POD, discharge
32	CP, M, ML	None	–	–	N	None	14 POD, discharge
33	AG, CP, M	None	–	–	N	None	11 POD, discharge
34	AG, CP, M	Right	3	7	N	None	25 POD, discharge
35	AG, CP, M	None	–	–	N	None	14 POD, discharge
36	AG, CP, M, V, CB	Left	6	13	Y	None	77 POD, discharge
37	AG, CP, M	None	–	–	Y	Septic shock, MOF	6 POD, died
38	AG, CP, M	Right	4	11	N	None	18 POD, discharge
39	CP, M	None	–	–	N	None	24 POD, discharge
40	CP, M	Right	3	7	N	None	9 POD, discharge
41	CP	Left	2	14	N	None	16 POD, discharge
42	AG, M, V, T	Right	3	60	Y	None	74 POD, discharge
43	V, CB	Right	3	10	N	Septic shock, haemorrhage	10 POD, died
44	CP, M	None	–	–	N	None	8 POD, discharge
45	M, V, T, Q	Right	3	50	Y	None	60 POD, discharge

PC – penicillins, AG – aminoglicozides, CP – cepheids, M – metronidazol, T – tianam, V – vancomycin, Q – quinolones, ML – macrolids, CB – carbapenems. POD – postoperative day. MOF – multiple organ failure.

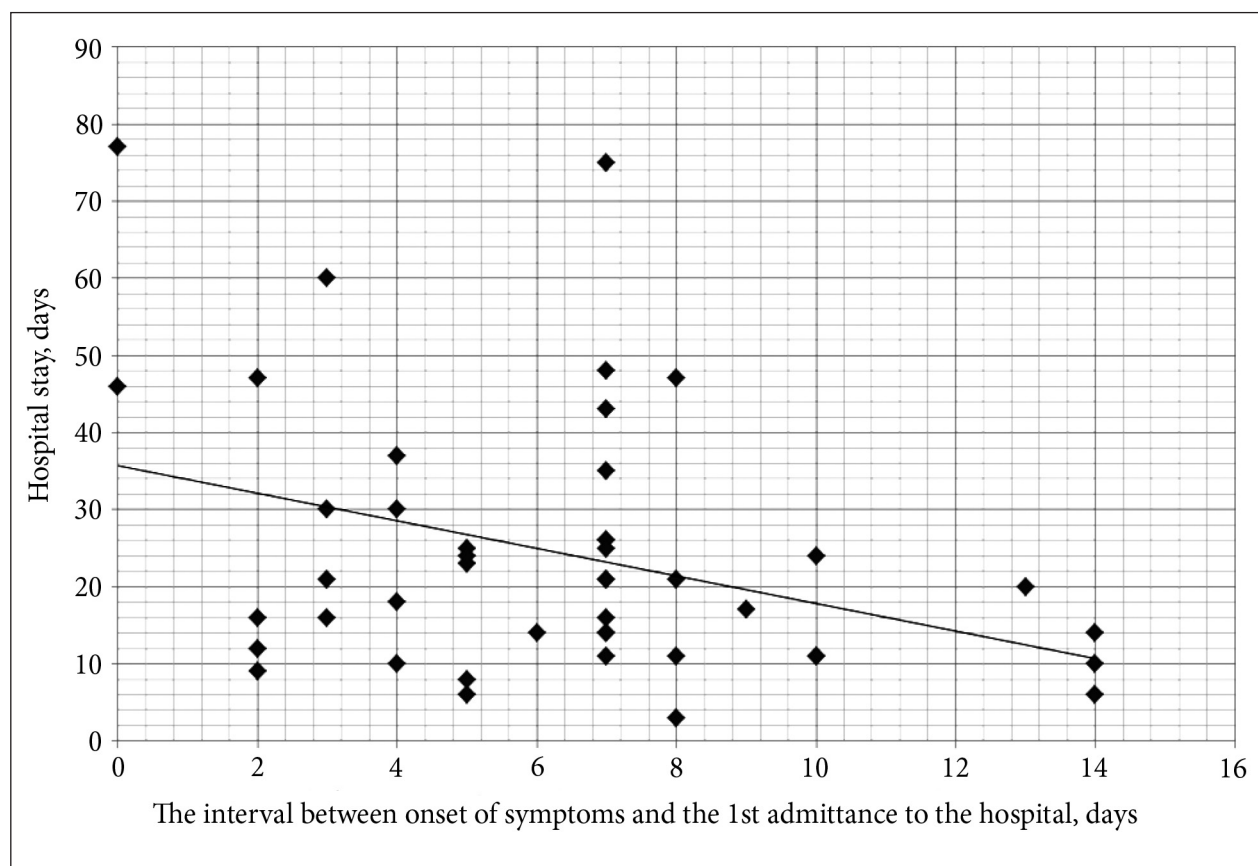


Fig. 3. Correlation between the time from onset of illness till admittance and overall hospital stay

haemorrhage due to eroded vessels (aorta – 1; v. cava superior – 2).

We found that there was a negative correlation between the time from the onset of symptoms till the first admittance to hospital and overall hospitalization time (Fig. 3). The Pearson correlation coefficient was found to be 0.357, $p = 0.016$ providing background for suggestion that the time of illness spent at home without appropriate treatment has a crucial role in the overall survival. Any delay after the onset of the symptoms of

oropharyngeal or odontogenic pathology poses a high risk of DNM occurrence.

Having evaluated the influence of different factors on survival, we determined that younger age, Endo type I, negative bacterial culture and shorter hospital stay are true precursors of the favourable outcome (Table 3), while shorter time from the onset of the symptoms till admittance to hospital and longer hospital stay significantly predetermine the need of additional surgical manoeuvres (Table 4).

Table 3. Predictors of survival

Factor	Survival (n = 35)	Death (n = 10)	OR (95% CI)	P
Duration between onset of symptoms to hospitalization, days (median)	5	8	0.765 (0.605–0.968)*	0.025
Age, years (mean)	52.49	65.2	0.891 (0.81–0.979)^	0.017
Extent of infection: Endo Type I	21 (60%)	4 (40%)	75.944 (2.787–2 069.702)^	0.01
Negative bacterial culture	11 (31.43%)	1 (10%)	143.829 (2.948–7 017.526)^	0.012
Hospital stay, days (median)	21	12.5	1.098 (1.009–1.195)^	0.029

* Univariate logistic regression analysis, ^ Multivariate logistic regression analysis.

Table 4. Predictors of additional surgery

Factor	No additional surgery (n = 27)	Additional surgery (n = 18)	Odds ratio (95% confidence interval)	<i>p</i>
Duration between onset of symptoms to hospitalization, days (median)	7	4.5	0.802 (0.646–0.995)*	0.044
Hospital stay, days (median)	16	30	1.081 (1.022–1.142)*	0.006

* Univariate logistic regression analysis.

DISCUSSION

Nowadays, acute DNM resulting from primary oropharyngeal or odontogenic infection is relatively rare in Western countries; however, this pathology is still common in the developing countries owing to the poor economic conditions and lack of medical resources for prevention and treatment of dental and oropharyngeal infections. Our institution treated 45 patients in a period of 10 years, which indicates the fact that the incidence is not rare. During the past 50 years, efforts to reduce the mortality rate associated with DNM have been only moderately successful. In 1938, Pearse (1) presented 110 patients with DNM and reported a 55% mortality rate (86% mortality in non-operative patients and 35% in surgically treated patients). Even after induction of antibiotics, the lethal outcome was still about 40%, as reported by Estrera et al. (2). In Table 5 we compare previous reports to our study (6–9). The mortality rates vary from 0 to 23% (in our series – 22.2%).

Infections originating in the fascial planes of the head and neck spread downwards into the mediastinum along the cervical fascias, facilitated by gravity, breathing, and negative intrathoracic pressure. The most common pathway is the lateral pharyngeal space through the retrovisceral space, inferiorly into the mediastinum (10–12).

The most common primary oropharyngeal infection earlier was odontogenic [11, 12], however, in our series it was found in 17 of 45 cases. Recent meta-analyses of case series have suggested that the etiology of DNM is predominantly arising from pharyngeal infections as opposed to odontogenic infections (13, 14, 15); in our series 16 out of 45 cases. Other potential causes of DNM, besides dental infections and common oropharyngeal infections such as tonsillitis, include pharyngitis, primary neck infections (including posttraumatic

ones), cervical lymphadenitis, suppurative thyroiditis, traumatic endotracheal intubation (with DNM usually manifested in the early postoperative period) and intravenous drug use (3, 16). None of the articles reviewed presented more than 3 cases of DNM of osteoarticular origin, as with our series (cases 9, 16, 35).

The diagnosis of cervical infection is clinically obvious, but early diagnosis of mediastinitis is often difficult. Radiographic examination of the neck and chest can reveal several features: widening of the retrovisceral space, anterior displacement of the tracheal air column, mediastinal emphysema, and widening of the mediastinal shadow. However, these signs often appear too late in the course of the disease (6, 14). A liberal use of a contrast-enhanced cervicothoracic CT scan is essential for the early detection of DNM and for follow-up (15, 16). In all cases CT scan immediately confirmed the diagnosis with high accuracy, showing soft tissue infiltration or collection of fluid density with or without the presence of gas bubbles. Cervicothoracic scan demonstrated the continuity of the infectious process between the neck and chest, evaluating the relationship between neck infection and mediastinitis.

As for isolated microbial flora, the cultures were positive in 73.3% of the cases. This data coincides with the Makeieff et al. series which noted 17% negative cultures (17). This is possibly due to early administration of antibiotics at the time of suspected diagnosis. Our previous work found 52.9% positive cultures in odontogenic mediastinitis (12). The organisms obtained most frequently were Streptococci and Enterococci. The cultures were polymicrobial and aerobic / anaerobic in 37.8% of the cases. Our data differs from the data presented in the literature (17, 18) where polymicrobial cultures were found in nearly 75% of the cases. The majority of infections are polymicrobial with aerobic and anaerobic bacterial species. Ridder et al.

Table 5. Comparison with recent studies

Author	Marty-Ane (1999)	Freeman (2000)	Papalia (2001)	Iwata (2005)	Our data (2012)
Number of pts	12	10	13	10	45
Age, years					
Mean	42	37.7	39.2	53.8	55.3
Range	19–67	15–62	16–67	16–82	18–79
Male, %	91.6	90	69.2	70	62.2
Initial site of infection, %					
Odontogenic	41.7	40	46.2	30	37.7
Cervical abscess	58.3	60	38.5	50	35.6
Other	0	0	15.4	20	26.7
Thoracotomy, %	91.6	100	76.9	100	64.4
Mortality, %	16.5	0	23	20	22.2

(13) identified *Streptococcus* species (*pyogenes*, *intermedius*, *constellatus*) as the most prevalent aerobic species in their series, with *bacteroides* species as the most prevalent anaerobic species.

Administration of intravenous broad-spectrum antibiotics with coverage for aerobic and anaerobic bacteria as soon as possible is mandatory regarding the high mortality rates of up to 85% in the preantibiotic era (1). Subsequently therapy was adapted according to the sensitivity of microorganisms. However, antibiotic therapy is not efficient without adequate surgical drainage of the cervical and thoracomedial collections. Airway compromise due to inflammatory oedema is a common finding in DNM. One should expect a difficult intubation which could be facilitated using fiberoptic bronchoscopy. If it fails, airway compromise should be treated with early tracheostomy, which can serve the dual role of opening fascial planes and securing the airway.

According to most authors, the optimal surgical approach for mediastinal drainage in patients with DNM is dependent on the level of diffusion of the necrotizing process (2, 6, 13, 15, 17, 19). If infection reaches only the superior mediastinum above the carina, standard transcervical approach may be adequate. The more extensive process requires thoracic incision.

Until the 1980s, transcervical mediastinal drainage was the main treatment strategy and open thoracotomy was not usual (1, 2, 19).

Cervical mediastinotomy was described by von Hacker (20). We suggest that in those cases, which are operated upon quite early after the beginning of the infection and are located high in

the mediastinum or low in the neck, the cervical approach is obviously the better option. But those that have localized as far down as the fifth thoracic vertebra, particularly when the case is a relatively old one, a thoracotomy and mediastinotomy are the best deal. A prolonged cervical drainage through tubes which lie close to the cervical vessel sheath may possibly cause an erosion of the carotid artery or jugular vein resulting in fatal haemorrhage. While performing cervical incision, carotid artery should be left alone with its fascial envelope intact.

In the case of mediastinitis spreading below the tracheal bifurcation anteriorly or the fourth thoracic vertebra posteriorly, Estrera et al. (2) recommend mediastinal drainage through a transthoracic approach. Corsten et al. (21) reported a significant difference in mortality of patients who received only transcervical mediastinal drainage (47%) compared with neck and thoracic debridement (19%) ($p < 0.05$).

In terms of the thoracotomy approach, Freeman et al. (7) and Marty-Ane et al. (6) insisted on standard posterolateral thoracotomy to be the best approach because it allows a comprehensive access to the hemithorax including the ipsilateral mediastinum and pericardium.

In our experience, adequate mediastinal drainage in DNM required an aggressive surgical approach. Thoracotomy provides better access to all mediastinal compartments allowing radical surgical debridement, drainage of pleural and pericardial cavities, and adequate placement of multiple large-bore double lumen chest tubes with irrigation.

Successful management through median sternotomy (22, 23) or clamshell incisions (24) has been reported. However, risk of subsequent osteomyelitis and dehiscence of the sternum is high, as well as the access to the posterobasal compartments of the chest cavity is difficult, especially on the left side (14, 21).

Cho et al. (25) reported their experience with 17 patients treated with video-assisted thoracoscopic surgery. However, only 8 of them suffered from DNM, whereas the remaining 9 had mediastinitis due to esophageal perforation. Consequently, their reported mortality rate for diffuse DNM was 25% (2 of 8 patients died. These two patients suffered from uncontrolled sepsis and both had MRSA in clinical specimens).

Obviously, each of these techniques offers potential advantages and disadvantages, and probably the surgical approach has to be carefully chosen according to the patient's condition, the extent of disease and the surgeon's experience in order to maintain a low rate of complications, reoperations and mortality.

As demonstrated by our analysis, currently mortality rates are as follows: approximately 10% in localized (Endo type I) and 32% in diffuse forms (Endo types IIA and IIB). Mortality rate in our previous report was 35.2% (12).

CONCLUSIONS

For descending necrotizing mediastinitis limited to the upper part of the mediastinum a transcervical approach and drainage may be sufficient. However, in advanced cases an immediate and more aggressive surgical approach is required trying to reduce a much higher morbidity and mortality in this subset of patients. Younger age, Endo type I, negative bacterial culture and shorter hospital stay are true precursors of survival. Shorter time from the onset of the symptoms till admittance to hospital and longer hospital stay significantly predetermine the need of additional surgical manoeuvres.

Received 21 July 2013
Accepted 2 October 2013

References

1. Pearse HE Jr. Mediastinitis following cervical suppuration. *Ann Surg.* 1938; 108: 588–611.
2. Estrera AS, Lanay MJ, Grisham JM, Sinn DP, Platt MR. Descending necrotizing mediastinitis. *Surg Gynecol Obstet.* 1983; 157: 545–52.
3. Boscolo-Rizzo P, Stellin M, Muzzi E, Mantovani M, Fuson R, Lupato V, et al. Deep neck infections: a study of 365 cases highlighting recommendations for management and treatment. *Eur Arch Otorhinolaryngol.* 2012; 269(4): 1241–9.
4. Erkmén CP, Wang H, Czum J, Paydarfar JA. Use of cervicothoracic anatomy as a guide for direct drainage of descending necrotizing mediastinitis. *Ann Thorac Surg.* 2012; 93: 1293–4.
5. Endo S, Murayama F, Hasegawa T, Yamamoto S, Yamaguchi T, Sohara Y, et al. Guideline of surgical management based on diffusion of descending necrotizing mediastinitis. *Jpn J Thorac Cardiovasc Surg.* 1999; 47: 14–19.
6. Marty-Ane CH, Berthet JP, Alric P, Pegis JD, Rouviere P, Mary H. Management of descending necrotizing mediastinitis: an aggressive treatment for an aggressive disease. *Ann Thorac Surg.* 1999; 68: 212–7.
7. Freeman RK, Vallieres E, Verrier ED, Karmy-Jones R, Wood DE. Descending necrotizing mediastinitis: an analysis of the effects of serial surgical debridement on patient mortality. *J Thorac Cardiovasc Surg.* 2000; 119: 260–7.
8. Papalia E, Rena O, Oliaro A, Cavallo A, Giobbe R, Casadio C, et al. Descending necrotizing mediastinitis: surgical management. *Eur J Cardiothorac Surg.* 2001; 20: 739–42.
9. Iwata T, Sekine Y, Shibuya K, Yasufuku K, Iyoda A, Iizasa T, et al. Early open thoracotomy and mediastinopleural irrigation for severe descending necrotizing mediastinitis. *Eur J Cardiothorac Surg.* 2005; 28: 384–8.
10. Weaver E, Nguyen X, Brooks MA. Descending necrotizing mediastinitis: two case reports and review of the literature. *Eur Respir Rev.* 2010; 19: 141–9.
11. Wheatley MJ, Stirling MC, Kirsh MM. Descending necrotizing mediastinitis. *Ann Thorac Surg.* 1990; 49: 780–4.
12. Kiskis G, Gruslys V, Jovaišas V, Kybartas A, Liubertiene I, Narbutas J, et al. Odontogenic me-

- diastinitis. Diagnostics and treatment. *Medicina*. 2002; 38(S2): 88–90.
13. Ridder GJ, Maier V, Kinzer S, Teszler CB, Boedeker CC, Pfeiffer J. Descending necrotizing mediastinitis: contemporary trends in etiology, diagnosis, management, and outcome. *Ann Surg*. 2010; 251: 528–34.
 14. Kocher GJ, Hokschi B, Caversaccio M, Wiegand J, Schmid RA. Diffuse descending necrotizing mediastinitis: surgical therapy and outcomes in a single-centre series. *Eur J Cardiothorac Surg*. 2012; 42(4): e66–72. doi: 10.1093/ejcts/ezs385. Epub 2012 Jul 3.
 15. Rubikas R, Gradauskas P, Vilčinskis A, Petrauskas V, Samiatina D, Krasauskas A. Descending necrotizing mediastinitis. *Medicina*. 2002; 38(S2): 91–3.
 16. Scaglione M, Pezzullo MG, Pinto A, Sica G, Bocchini G, Rotondo A. Usefulness of multidetector row computed tomography in the assessment of the pathways of spreading of neck infections to the mediastinum. *Semin Ultrasound CT MR*. 2009; 30: 221–30.
 17. Makeieff M, Gresillon N, Berthet JP, Crampette L, Marty-Ane C. Management of descending necrotizing mediastinitis. *Laryngoscope*. 2004; 114: 772–5.
 18. Deu-Martin M, Saez-Barba M, Sanz IL, Pennarocha RA, Vielva LR, Monserrat JS. Mortality risk factors in descending necrotizing mediastinitis. *Arch Bronconeumol*. 2010; 46: 182–7.
 19. Howell HS, Prinz RA, Pickleman JR. Anaerobic mediastinitis. *Surg Gynecol Obstet*. 1976; 143: 353–9.
 20. Von Hacker V. Zur operativen Behandlung der Perioesophagealen und Mediastinalen Phlegmone nebst Bewerbungen zur Technik der Collaren und Dorsalen Mediastinotomie. *Arch F Klin Chir*. 1901; 64: 478.
 21. Corsten MJ, Shamji FM, Odell PF, Frederico JA, Laframboise GG, Reid KR, et al. Optimal treatment of descending necrotizing mediastinitis. *Thorax*. 1997; 52: 702–8.
 22. Izumoto H, Komada K, Okada O, Kamata J, Kawazoe K. Successful utilization of the median sternotomy approach in the management of descending necrotizing mediastinitis: report of case. *Surg Today*. 1996; 26: 286–8.
 23. Casanova J, Bastos P, Barreiros F. Descending necrotizing mediastinitis. Successful treatment using radical approach. *Eur J Cardiothorac Surg*. 1997; 12: 494–6.
 24. Ris HB, Banik A, Furier M, Caversaccio M, Cerny A, Zetabaren P. Descending necrotizing mediastinitis: surgical treatment via clamshell approach. *Ann Thorac Surg*. 1996; 62: 1650–4.
 25. Cho JS, Kim YD, Lee SK, Jeong YJ. Treatment of mediastinitis using video-assisted thoracoscopic surgery. *Eur J Cardiothorac Surg*. 2008; 34: 520–4.
- Ričardas Janilionis, Žymantas Jagelavičius, Pavel Petrik, Gintaras Kiškis, Vytautas Jovaišas, Algis Kybartas, Arūnas Žilinskas, Irena Liubertienė, Giedrius Navickas, Ramūnas Valančius**
- NUSILEIDŽIANTIS NEKROTINIS
MEDIASINITAS: CHIRURGINIS GYDYMAS IR
IŠEITYS: VIENO CENTRO PATIRTIS**
- Santrauka*
- Tikslai.** Nusileidžiantis nekrotinis mediastinitas yra sunkus infekcinis procesas, plintantis iš kaklo audinių į tarpuplautį. Kadangi ši patologija nėra dažna, medicininėje literatūroje yra tik keletas studijų, analizuojančių didesnę tokių ligonių skaičių. Mūsų tikslas yra išanalizuoti ir įvertinti nusileidžiančio mediastinito chirurginio gydymo patirtį Vilniaus universiteto ligoninės Krūtinės chirurgijos centre.
- Metodai.** Atlikome retrospektyvią ligonių, sirgusių nekrotiniu nusileidžiančiu mediastinitu nuo 2002 iki 2011 metų, duomenų analizę. Per šį laikotarpį gydytame 45 šia patologija sirgusius asmenis. Vidutinis amžius buvo $55,3 \pm 15,4$ metai. Pirminė orofaringinė infekcija buvo nustatyta 16 (35,6 %), odontogeninė infekcija – 17 (37,7 %) ligonių. Dvylikai (26,7 %) ligonių buvo nustatytos kitos infekcijos priežastys. Pagal išplitimą Endo I tipo mediastinitas nustatytas 25 (56 %), Endo IIA tipas – 10 (22 %), Endo IIB tipas – 10 (22 %) ligonių. Visi ligoniai gydyti plataus veikimo spektro antibiotikais (pradžioje empiriškai, vėliau pagal pasėlių) ir visi buvo operuoti: atvertos pūlių sankaupos kakle, per torakotomiją atvertas ir drenuotas tarpuplautis nuolat jį praplaunant.
- Rezultatai.** Šešiolikai (35,6 %) ligonių pūliai buvo drenuoti tik padarius inciziją kakle, o penki (11 %) gydyti tik po torakotomijos ir mediastinotomijos. Likusiems 24 (53,4 %) ligoniams pūliai buvo atverti tiek pro

kaklą, tiek ir pro krūtinę. Sunkias komplikacijas, tokias kaip sepsinis šokas, dauginis organų nepakankamumas, kraujavimas iš stambiųjų tarpuplaučio kraujagyslių, patyrė 15 ligonių. Vidutinė gydymo trukmė ligoninėje buvo 21 diena. Sėkmingai išgydyti 35, o 10 ligonių mirė. Bendras mirštamumas siekė 22,2 %.

Nustatėme, jog yra neigiama koreliacija tarp sirgimo laiko iki ligoninės ir hospitalizacijos trukmės (Pearsono koreliacijos koeficientas 0,357, $p = 0,016$). Tai leidžia manyti, kad sirgimo laikas iki ligoninės, kai nėra reikiamo gydymo, turi didelę reikšmę išgyvenamumui. Išsiaiškinome, kad jaunesnis amžius, Endo

I tipas, neigiamas bakteriologinis pasėlis ir ilgesnis hospitalizacijos laikas turi įtakos geresnei ligos baigčiai.

Išvados. Infekcijos atvėrimas ir drenavimas pro kaklą gali būti pakankamas, jei nusileidžiantis nekrotinis mediastinitas apsiriboja tik viršutiniu tarpuplaučiu. Sunkesniais atvejais (infekcijai nusileidus žemiau į tarpuplautį) skubus ir agresyvesnis chirurginis gydymas yra būtinas norint sumažinti gana didelį šių ligonių sergamumą ir mirštamumą.

Raktažodžiai: nusileidžiantis nekrotinis mediastinitas, torakotomija, mediastinotomija, kaklo flegmonos atvėrimas, tarpuplaučio plovimas