

Patellofemoral joint biomechanics in the females with anterior knee pain applying full weight bearing kinematic MRI

Andrius Brazaitis¹,

Algirdas Tamošiūnas¹,

Janina Tutkuvienė²

¹ Department of Radiology,
Vilnius University Faculty of Medicine

² Department of Anatomy,
Histology and Anthropology,
Vilnius University Faculty of Medicine

Purpose. The aim of the study was to evaluate biomechanics of the patellofemoral joint using full weight bearing kinematic MRI. We postulated that females with unilateral PFP might have greater medial femoral rotation in comparison to the contralateral knee, also greater lateral patella tilt and displacement.

Methods. Forty four females aged 20–40 years with unilateral PFP were included in the study. The kinematic MRI examination was performed with a 1.5 T MRI unit. Full-weight bearing was used. Sagittal and axial images of the patellofemoral joint were acquired with a transmit-receive surface body coil. The study parameters, i. e. bisect offset, patella tilt angle, medial femoral rotation, patellar rotation at 0, 10, 20, 30, 40, 50° of flexion, were measured for both knees.

Results. Statistically significant changes were confirmed for greater bisect offset at all angles of flexion. The patella tilt angle increased steadily throughout full extension, but there was no significant difference in the tilt angle at 50° flexion. Greater medial femoral rotation was observed at all degrees of flexion, while patellar rotation showed no difference.

Conclusions. Our study has confirmed the growing body of literature, theorizing that the primary cause of PFP pain is altered femur dynamics under relatively stable patella.

Key words: patellofemoral pain (PFP), weight bearing kinematic MRI, knee

Patellofemoral pain (PFP) is one of the most common musculoskeletal disorders (1). It is of high socioeconomic relevance because it most frequently affects young and active people. The incidence is around 15–33% in active adults and 21–45% in adolescents (2). Females face a two times greater risk for PFP (3). Despite the high incidence and multitude of

symptoms, pathogenesis of PFP is still not well understood. There are many possible causes for PFP: hip muscle weakness, vastus medialis and vastus lateralis imbalance, increased hamstring tightness, iliotibial tract tightness, patellar maltracking, foot eversion. Despite many possible mechanisms disputed in literature, one mostly accepted is that PFP may be related to patellofemoral maltracking (4). Individuals with patellofemoral pain exhibit greater patellofemoral joint stress over the cartilage and subchondral bone (5). Excessive loads associated with patellar maltracking may lead to PFP and

Correspondence to: Andrius Brazaitis, Department of Radiology, Nuclear Medicine and Medical Physics, Vilnius University Faculty of Medicine, Santariškių St. 2, LT-08661 Vilnius, Lithuania. E-mail: andrius.brazaitis@santa.lt

lateral patellofemoral osteoarthritis. It is widely accepted that unstable patella slides over the stable femur (6). The altered patellofemoral joint kinematics during weight bearing may be rather associated with abnormal femur motion than patella motion. Greater lateral patella tilt and displacement, as well as greater degree of medial femoral rotation were associated with PFP (7, 8). There are several studies which compared individuals with PFP to healthy subjects. However, to our knowledge, there are no studies regarding intra-subject comparisons of affected and pain-free sides (7, 9). The aim of the present study was to evaluate the patellofemoral joint biomechanics with full weight bearing kinematic MRI. We postulated that females with unilateral PFP might have greater medial femoral rotation compared to contralateral pain-free knee, as well as greater lateral patella tilt and displacement.

MATERIALS AND METHODS

Forty four females with unilateral PFP were included in the study with similar age, height and body mass. Prior to the MRI study, all procedures were explained and each subject signed a human subject's consent form as approved by the Vilnius Regional Biomedical Research Ethics Committee. Individuals with unilateral PFP between the ages of 20 and 40 years were included in the study. Individuals over the age of 40 were excluded from the study to avoid possible degenerative joint changes. Inclusion criteria were for at least two symptoms associated with PFP: painful stair ascent or descent, painful squatting, painful kneeling, painful prolonged sitting. Exclusion criteria were previous knee surgery, traumatic patellar dislocation, any implanted pacemakers, cochlear implants, clips. The kinematic MRI examination was done with a 1.5 T MRI unit (Siemens Symphony, Erlangen, Germany) using the body coil to allow flexion and extension of both knees. We used a Dynawell L-spine device to load patients with full weight and MRI machine table movement to let knees extend from 50° to 0°. Patients were in the supine position and were asked to press equally hard with both legs upon the Dynawell L-spine device. The table was moved automatically to extend knees by 10°. Sagittal and axial images of the patellofemoral joint were acquired with a transmit-receive surface body coil and

a fast gradient-echo pulse sequence. Sagittal images were acquired to double check the knee flexion angle. Scanning parameters: repetition time (TR) 2.84 ms, echo time (TE), 1.05 ms; flip angle 8°, field of view 30 × 30 cm, matrix 256 × 128, slice thickness 3 mm; number of slices 30, excitations 1.

Images with the maximum patellar width were selected for evaluation of medial femoral rotation, patella rotation, lateral patella tilt and lateral patella displacement. Medial/lateral femoral rotation (transverse plane) was measured as the angle formed by the line joining the posterior femoral condyles and the line parallel to the horizontal orientation of the field of view (Fig. 1a). Patella rotation (transverse plane) was measured as the angle formed by the line defining the maximum patella width and the line parallel to the horizontal orientation of the field of view (Fig. 1b). Medial/lateral patella tilt was measured as the angle formed by the line joining the maximum width of the patella and the line joining the posterior femoral condyles (Fig. 1c). Positive values for femoral rotation indicate medial rotation, negative ones show external rotation. As with femoral rotation, medial patella rotation was defined as positive and lateral patella rotation as negative. Medial/lateral patellar displacement was measured using the bisect offset index as described by Brossman et al. (10) (Fig. 1d). A line was drawn parallel to the posterior femoral condyles, while another perpendicular line was drawn through the deepest trochlear point. This line intersects the line connecting the widest patellar points. Measurements were made with the Leonardo workstation (Siemens, Erlangen, Germany). The femoral and patella rotation angle, patella tilt angle and the bisect offset measurements were collected from the images acquired with full weight bearing from 50° to full extension. Femoral rotation, patella rotation and lateral patella tilt measurements were reported in degrees, lateral patella displacement (bisect offset) was measured in percent.

Statistical analysis

To test the hypothesis whether patella displacement, patella tilt, femoral rotation, and patella rotation differed between the groups across knee flexion angles the t-test was used. Significance levels were set at $p < 0.05$. Statistical software Stata13

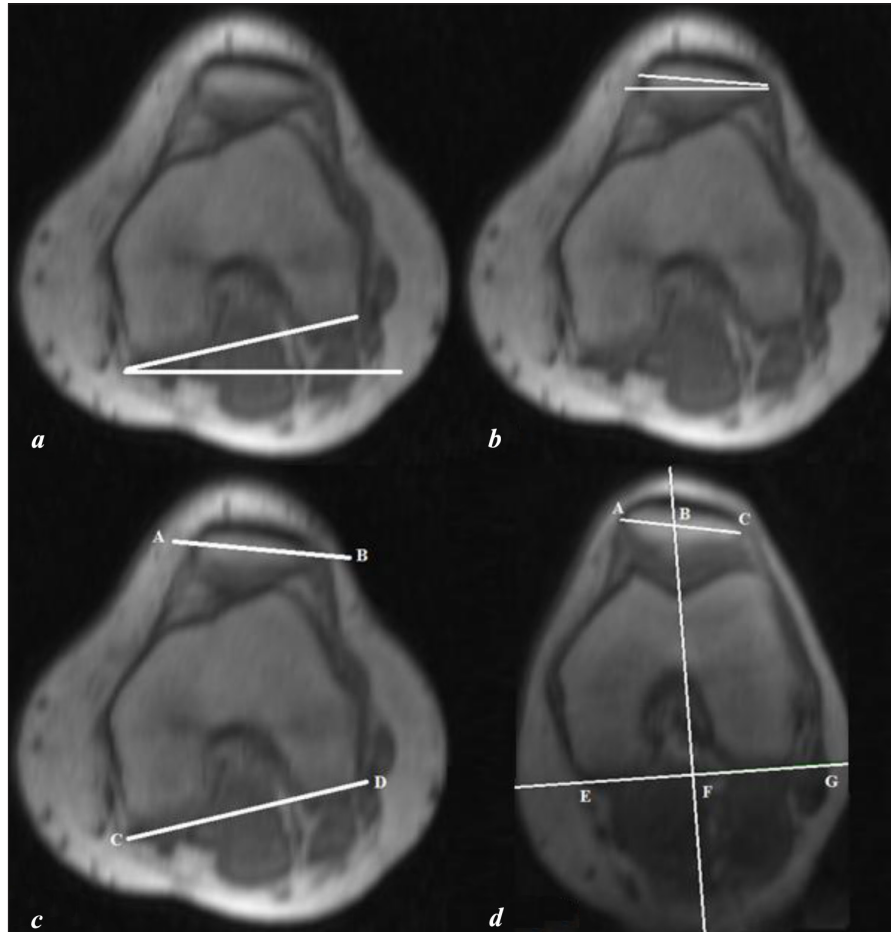


Fig. 1. Descriptions of the analyzed patellofemoral kinematic parameters. *a* – medial femoral rotation angle between the posterior femoral condyles and the external field of view; *b* – patellar rotation angle formed by a line connecting the widest patellar points and the external field of view; *c* – patella tilt angle formed between lines connecting the widest patellar points and posterior femoral condyles; *d* – EG line parallel to the posterior femoral condyles, BF line perpendicular to the EG line bisects, AC line connecting the widest patellar points A and C. Bisect offset ratio is $BC/AC \times 100$

was used for all analyses. All results are presented as means and standard deviations.

RESULTS

Statistically significant differences were observed in the medial femoral rotation of healthy and painful knees at all flexion angles (Fig. 2). The greatest difference of 7° was observed at full extension (mean \pm SD, 19.2 ± 6.8 versus 12.2 ± 6.6 ; $p < 0.001$).

As depicted in Fig. 3, statistically significant differences were observed in the patella tilt of healthy and painful knees, in all positions except at 50° of flexion (mean \pm SD, 6.59 ± 5.58 versus 6.98 ± 3.7 ; $p = 0.27$).

The greatest difference (7%) comparing the data of bisect offset was revealed at full extension as presented in Fig. 4 (mean \pm SD, 70.2 ± 10.29 versus 63.4 ± 7.17 ; $p < 0.001$).

We found no statistically significant differences in patella rotation. Both patellae rotated identically (mean \pm SD, -2.73 ± 4.25 versus 3.4 ± 5.65 , $p > 0.05$).

DISCUSSION

Our study has revealed statistically significant differences between the medial femoral rotation, lateral patella tilt and bisect offset in painful vs pain-free knees for females with unilateral knee pain. No differences in the patella rotation were observed. However, to our knowledge, there are no studies

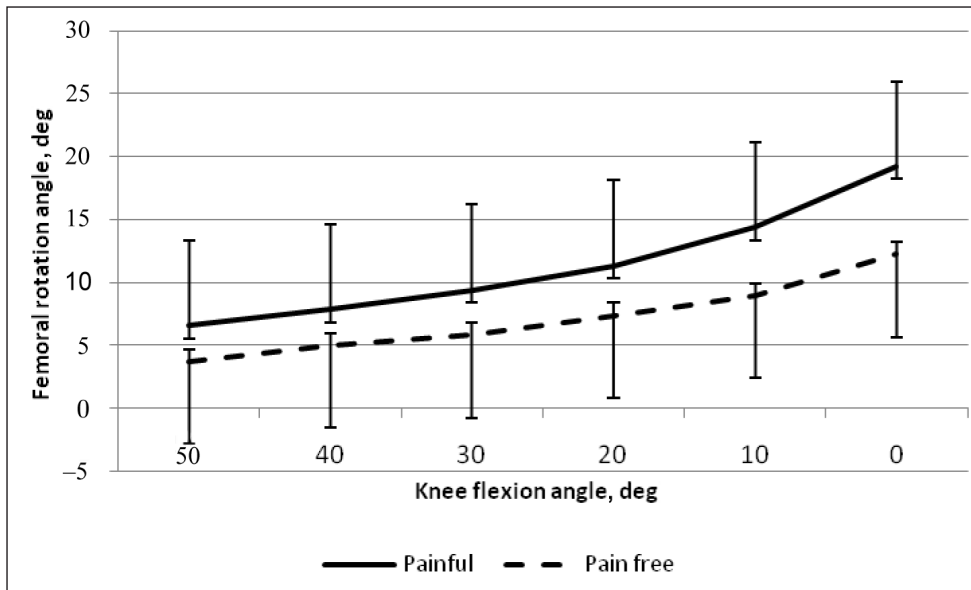


Fig. 2. Comparative dynamics of medial femoral rotation depending on the knee flexion angle. Data presented are mean \pm standard error

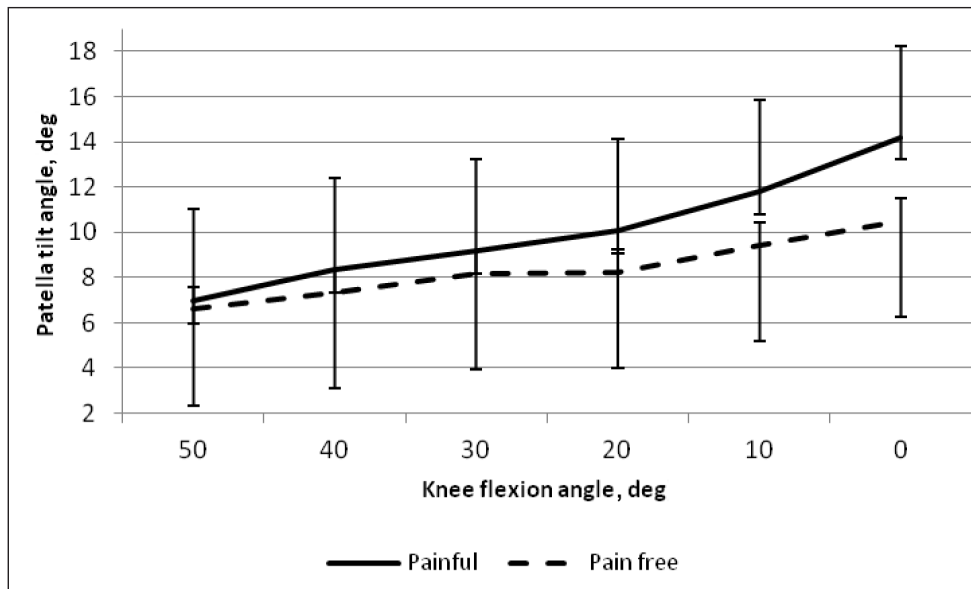


Fig. 3. Comparative dynamics of the patella tilt angle depending on the knee flexion angle. Data presented are mean \pm SD

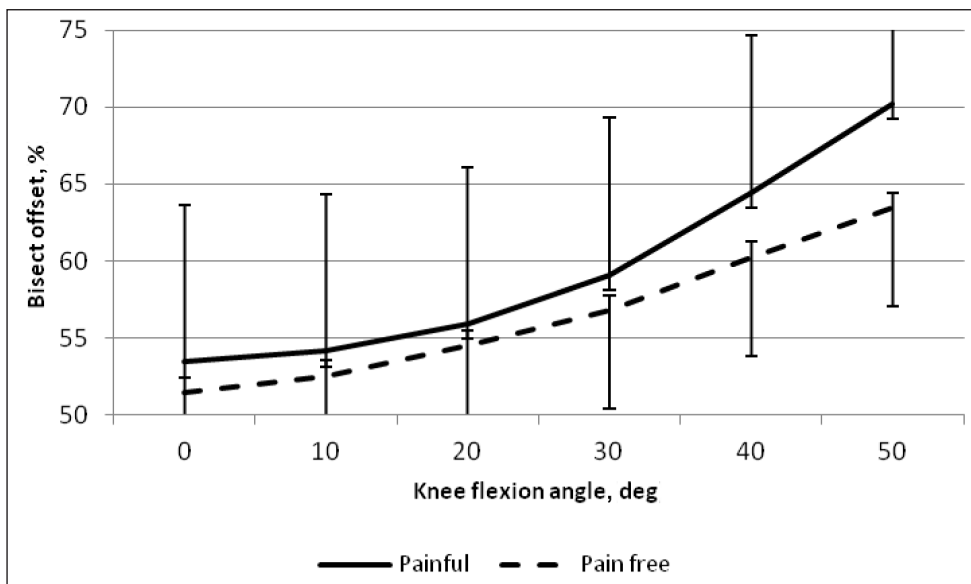


Fig. 4. Comparative dynamics of the Bisect offset depending on the knee flexion angle. Data presented are mean \pm SD

regarding intra-subject comparisons of affected and pain-free sides. The greatest distinction was observed in the bisect offset and medial femoral rotation at full extension. The patellar rotation was minimal compared to femoral rotation.

Our results confirmed the data of other investigators who have reported greater bisect offset index for the affected knee as compared to the pain-free knee in kinematic weight-bearing MRI examinations in different individuals (11, 12). Both knees have demonstrated a similar increasing bisect offset from 50° to 30° of flexion, while diverging at low angles of flexion, especially at full extension. The affected knee demonstrated greater patellar displacement at low flexion angles. The average bisect offset index in the painful knee was 7% at full extension, which is in agreement with the other authors, who investigated affected and pain free knees in different individuals (12, 13). The greatest bisect offset index in the painful knee at full extension was 92%, which might be influenced by weak passive medial stabilizers, namely the medial patellar retinaculum.

The patella tilt angle increased throughout all extension with small differences between 50° to 30° and was greater between 30° and full extension. The maximum lateral patella tilt angle in the painful knee was 22°, those data coincided with the previously reported data for different individuals (12, 13). The patellar tilt was previously considered a direct consequence of vastus medialis atrophy and dysplasia. More recently, it has been shown that there is a high statistical correlation between the type of femoral groove dysplasia and the patellar tilt: the greater the trochlear dysplasia the higher the patellar tilt (14).

Both knees have demonstrated a similar increasing medial femoral rotation from 50° to full extension, with a greater degree at full extension in the affected knee. Average difference in full extension was 7°. Investigators, who investigated different individuals with anterior knee pain and pain free ones, reported difference in medial femoral rotation to be 12.2–13° (15, 16). Changes in femoral rotation might be caused by quadriceps muscle atrophy (17) or increased femoral anteversion (18). Another possible explanation for medial femoral rotation is a “screw home” mechanism. It is a locking mechanism that occurs to ensure stability at the knee when fully extended. Femur moves on a fixed tibia in the closed kinetic chain and has to medially rotate relative to the tibia to achieve full knee exten-

sion. The influence of the “screw home” mechanism on the patellofemoral joint should be investigated in detail because it also has effect on the tibial tubercle trochlear groove distance (TTTG), which is widely used for patellofemoral alignment (19). Patellofemoral maltracking is considered to be secondary to an abnormal femoral rotation in the transverse plane with regard to the patella (1). In other words, the femur rotates under a relatively stable patella. The possible dysfunction of the gluteal and quadriceps muscle was not evaluated in our study.

Patella rotation was relatively small with respect to the femur during weight bearing knee extension. Our results are in agreement with those obtained by other studies which have reported that subjects with PFP demonstrate mild medial patella rotation as the knee extends (7, 20).

In summary, patellar motion was relatively small with respect to the femur when described using medial femoral rotation, patella rotation, lateral patella tilt, bisect offset indices.

A further study is needed to investigate the differences in patellofemoral joint motion between genders. Limitation of the present study was that images were evaluated by one radiologist, but measures were made on the identification of specific bony landmarks.

As a result, this study has provided an assessment of patellofemoral motion during weight-bearing movement which might help clinicians diagnose and treat patellofemoral pain.

CONCLUSIONS

Under full weight kinematic MRI examination, it was possible to detect significant differences in patellofemoral joint kinematics between painful and pain-free knees in the patients with unilateral knee pain. Our study has revealed that the increased medial femoral rotation, bisect offset and patella tilt may be important in PFP development. Our study is in agreement with other investigators who suggest that the primary cause of PFP pain is altered femur dynamics under a relatively stable patella. Our data may be helpful for choosing a correct treatment strategy of femur stabilization, especially at low angles of extension.

References

1. Sanchis-Alfonso V. Holistic approach to understanding anterior knee pain. Clinical implications. *Knee Surg Sports Traumatol Arthrosc.* 2014; 22(10): 2275–85.
2. Witvrouw E, Crossley K, Davis I, McConnell J, Powers CM. The 3rd International Patellofemoral Research Retreat: an international expert consensus meeting to improve the scientific understanding and clinical management of patellofemoral pain. *Br J Sports Med.* 2014; 48(6): 408.
3. Boling M, Padua D, Marshall S, Guskiewicz K, Pyne S, Beutler A. Gender differences in the incidence and prevalence of patellofemoral pain syndrome. *Scand J Med Sci Sports.* 2010; 20(5): 725–30.
4. Pal S, Besier TF, Beaupre GS, Fredericson M, Delp SL, Gold GE. Patellar maltracking is prevalent among patellofemoral pain subjects with patella alta: an upright, weightbearing MRI study. *J Orthop Res.* 2013; 31(3): 448–57.
5. Farrokhi S, Keyak JH, Powers CM. Individuals with patellofemoral pain exhibit greater patellofemoral joint stress: a finite element analysis study. *Osteoarthritis Cartilage.* 2011; 19(3): 287–94.
6. Wittstein JR, Bartlett EC, Easterbrook J, Byrd JC. Magnetic resonance imaging evaluation of patellofemoral malalignment. *Arthroscopy.* 2006; 22(6): 643–9.
7. Souza RB, Draper CE, Fredericson M, Powers CM. Femur rotation and patellofemoral joint kinematics: a weight-bearing magnetic resonance imaging analysis. *J Orthop Sports Phys Ther.* 2010; 40(5): 277–85.
8. Powers CM. The influence of abnormal hip mechanics on knee injury: a biomechanical perspective. *J Orthop Sports Phys Ther.* 2010; 40(2): 42–51.
9. Draper CE, Besier TF, Fredericson M, Santos JM, Beaupre GS, Delp SL, et al. Differences in patellofemoral kinematics between weight-bearing and non-weight-bearing conditions in patients with patellofemoral pain. *J Orthop Res.* 2011; 29(3): 312–7.
10. Brossmann J, Muhle C, Schroder C, Melchert UH, Bull CC, Spielmann RP, et al. Patellar tracking patterns during active and passive knee extension: evaluation with motion-triggered cine MR imaging. *Radiology.* 1993; 187(1): 205–12.
11. Regalado G, Lintula H, Eskelinen M, Kokki H, Kroger H, Svedstrom E, et al. Dynamic KINE-MRI in patellofemoral instability in adolescents. *Knee Surg Sports Traumatol Arthrosc.* 2014; 22(11): 2795–802.
12. Biyani R, Elias JJ, Saranathan A, Feng H, Guseila LM, Morscher MA, et al. Anatomical factors influencing patellar tracking in the unstable patellofemoral joint. *Knee Surg Sports Traumatol Arthrosc.* 2014; 22(10): 2334–41.
13. Teng HL, Chen YJ, Powers CM. Predictors of patellar alignment during weight bearing: an examination of patellar height and trochlear geometry. *Knee.* 2014; 21(1): 142–6.
14. Dejour D, Le Coultre B. Osteotomies in patellofemoral instabilities. *Sports Med Arthrosc.* 2007; 15(1): 39–46.
15. Powers CM, Ward SR, Fredericson M, Guillet M, Shellock FG. Patellofemoral kinematics during weight-bearing and non-weight-bearing knee extension in persons with lateral subluxation of the patella: a preliminary study. *J Orthop Sports Phys Ther.* 2003; 33(11): 677–85.
16. Tennant S, Williams A, Vedi V, Kinmont C, Gedroyc W, Hunt DM. Patello-femoral tracking in the weight-bearing knee: a study of asymptomatic volunteers utilising dynamic magnetic resonance imaging: a preliminary report. *Knee Surg Sports Traumatol Arthrosc.* 2001; 9(3): 155–62.
17. Barton CJ, Lack S, Malliaras P, Morrissey D. Gluteal muscle activity and patellofemoral pain syndrome: a systematic review. *Br J Sports Med.* 2013; 47(4): 207–14.
18. Davis IS, Powers CM. Patellofemoral pain syndrome: proximal, distal, and local factors, an international retreat, April 30–May 2, 2009, Fells Point, Baltimore, MD. *J Orthop Sports Phys Ther.* 2010; 40(3): A1–16.
19. Izadpanah K, Weitzel E, Vicari M, Hennig J, Weigel M, Sudkamp NP, et al. Influence of knee flexion angle and weight bearing on the Tibial Tuberosity-Trochlear Groove (TTTG) distance for evaluation of patellofemoral alignment. *Knee Surg Sports Traumatol Arthrosc.* 2014; 22(11): 2655–61.
20. Nha KW, Papannagari R, Gill TJ, Van de Velde SK, Freiberg AA, Rubash HE, et al. In vivo patellar tracking: clinical motions and patellofemoral indices. *J Orthop Res.* 2008; 26(8): 1067–74.

**Andrius Brazaitis, Algirdas Tamošiūnas,
Janina Tutkuvienė**

**GIRNELĖS IR ŠLAUNIKAULIO SĄNARIO
BIOMECHANIKA MOTERIMS SU SKAUSMU
PRIEKINĖJE SĄNARIO DALYJE TAIKANT
KINEMATINĮ SU APKROVA MAGNETINIO
REZONANSO TOMOGRAFIJOS TYRIMĄ**

Santrauka

Tyrimo tikslas. Įvertinti girnelės ir šlaunikaulio sąnario biomechaniką naudojant kinematinį su apkrova MRT tyrimą. Tikrinome hipotezę, ar moterims su vienpusiu patelofemoraliniu skausmu vidinės šlaunikaulio rotacijos kampas, girnelės rotacijos kampas, girnelės nuosvyrio kampas ir girnelės poslinkis skaudančiame sąnaryje skiriasi nuo sveiko kelio.

Metodai. Tyrime dalyvavo 44 moterys su vienpusiu patelofemoraliniu skausmu nuo 20 iki 40 metų. Kinematinis MRT tyrimas atliktas naudojant 1,5 T galingumo aparatą su pilno kūno svorio apkrova. Sagitaliniai ir ašiniai pjūviai atlikti nuo 50° sulenkimo

iki visiško sąnario ištiesimo. Tyrimui naudota kūno ritė. Kiekviename sulenkimo kampe matavome abiejų kelių vidinės šlaunikaulio rotacijos kampus, girnelės rotacijos kampus, girnelės nuosvyrio kampus ir girnelės poslinkį.

Rezultatai. Nustatėme statistškai patikimą girnelės poslinkį visuose sulenkimo kampuose. Girnelės nuosvyrio kampas didėjo tiesiant kelį, statistškai patikimo skirtumo tarp sveiko ir skaudančio sąnario neradome tik sulenkus 50°. Vidinė šlaunikaulio rotacija labiausiai skyrėsi pilnai ištiesus kelio sąnarį. Neradome statistškai reikšmingų skirtumų tarp girnelės rotacijos kampų pažeistame ir sveikame kelio sąnariuose.

Išvada. Moterų su vienpusiu patelofemoraliniu skausmu šlaunikaulio rotacija skaudančiame sąnaryje yra labiau išreikšta, palyginti su santykinai stabilia girnele.

Raktažodžiai: girnelės ir šlaunikaulio sąnarys, kinematinis magnetinio rezonanso tomografijos (MRT) tyrimas su apkrova, patelofemoralinis skausmas, kelio sąnarys