

Complications of orbital endoimplantation in the Eye Clinic of the Lithuanian University of Health Sciences

Raimonda Piškinienė,

Mantas Banevičius

*Eye Clinic, Medical Academy,
Lithuanian University
of Health Sciences,
Kaunas, Lithuania*

The aim of the study was to analyse the rate of complications of orbital endoimplantation in patients operated from 2002 to 2014 at the Eye Clinic of the Lithuanian University of Health Sciences and to compare it with the results in the literature. Enucleation must be performed very carefully in order to prevent any additional trauma, infection, deformation, and to create an optimal conjunctival socket. However, complications occur despite efforts and qualified surgeons. The most common complications described in the literature are thinning and cysts of the conjunctiva, a foreign body reaction, secretion, symblepharons, fornix deficiency, ptosis, permanent pain, dislocation, migration and protrusion of the implant, a primary or secondary infection, and implant extrusion.

From 2002 to 2014, 128 patients underwent orbital endoimplantation surgery at the Eye Clinic. The most common complications were conjunctival erosion (five patients, or 2.9%), cysts (nine patients, or 7%), and implant extrusion (five patients, or 2.9%). The type and rate of complications were very similar to the data in the literature.

Keywords: orbital implant, post-enucleation socket syndrome, orbital endoimplantation, enucleation

INTRODUCTION

An implant is a medical device, which is grown into the human body to replace a malfunctioning or missing part of the body or tissue, or to make their function more adequate. Since the surface of the implant is in contact with human tissue it should be produced from materials that are hypoallergenic, non-toxic, and indestructible chemically or mechanically as loose parts can disturb the activity of other organs (1).

This paper is about endoimplantation of the anophthalmic orbit. The purpose of this procedure is to restore the orbital volume, to save the function of extra-ocular muscles, to improve the motility of the artificial eye, and to minimize the symptoms of the post-enucleation socket syndrome (PESS).

The removal of the eyeball must be performed very carefully in order to avoid any unnecessary trauma, infection, deformation, or other complications and to create the optimal conjunctival sac. Despite the most favourable conditions and qualified surgeons, the possibility of complications still remains (2–8, 11, 24).

The most frequent complications of orbital endoimplantation found in the literature are

the following: thinning of the conjunctiva (3.2–8.3%), conjunctival cysts (3.2–6.0%), a foreign body reaction (5.4%), secretion (6.0–21.0%), symblepharons (3.0%), deficiency of conjunctival fornices (10.0%), ptosis (10.5–23.5%), permanent pain (2.0–6.0%), implant dislocation and/or migration (11.0%), erosion (0.8–36.8%), primary or secondary infection (0.4–5.8%), and implant extrusion (1.9–50.0%) (9–21, 37).

The reasons for complications of orbital endoimplantation are very different. The early postoperative period can be complicated by incorrect implantation, poor wound closure, haemorrhage, oedema, an over-sized implant, or infection. Complications of the late postoperative period are caused by the erosion of the tissue above the implant that can be caused by irregularity of the anterior surface of the implant, improper artificial eye or improper wearing of the artificial eye, or secondary infection of a protruded orbital implant.

A good surgical technique, a proper-sized and good-quality orbital implant (36, 38), appropriate and qualified care of the artificial eye and the ophthalmic socket are necessary for prevention of complications. If a complication occurs, adequate treatment is needed (39).

AIM OF THE STUDY

To evaluate complications of orbital endoimplantation during the period of 2002 to 2014 in the Eye Clinic of the Lithuanian University of Health Sciences and to compare them with the data in the literature.

MATERIALS AND METHODS

The work was performed at the Eye Clinic of the Lithuanian University of Health Sciences and was based on a retrospective analysis of the data of 128 patients who underwent orbital endoimplantation surgery at the clinic from 2002 to 2014. Primary and secondary orbital endoimplantation was performed on 111 patients (86.7%) and 17 patients (13.2%), respectively.

RESULTS

For primary and secondary endoimplantation silicone spheres (68–53.1%), hydroxyapatite (9–7.0%), bioceramic (8–6.3%), porous polyethylene (39–30.5%) implants, and autogenous dermofat graft (4–3.1%) were used (Fig. 1).

As can be seen from the data in the chart above, the most common complication was the conjunctival cyst (nine patients, 7%). Five implants (2.9%) were protruded, five (2.9%) extruded, and two (1.6%) dislocated. One (0.8%) patient had a lacrimal gland cyst formation, and three patients (2.3%) developed upper lid ptosis.

Protruded and dislocated implants were integrated, extruded were silicone implants. One implant (0.78%) extruded in the early postoperative period, during the first month after surgery. Other complications – five protrusions (2.9%), four extrusions (3.12%), and two dislocations (1.56%) – occurred during the late postoperative period, several years after surgery.

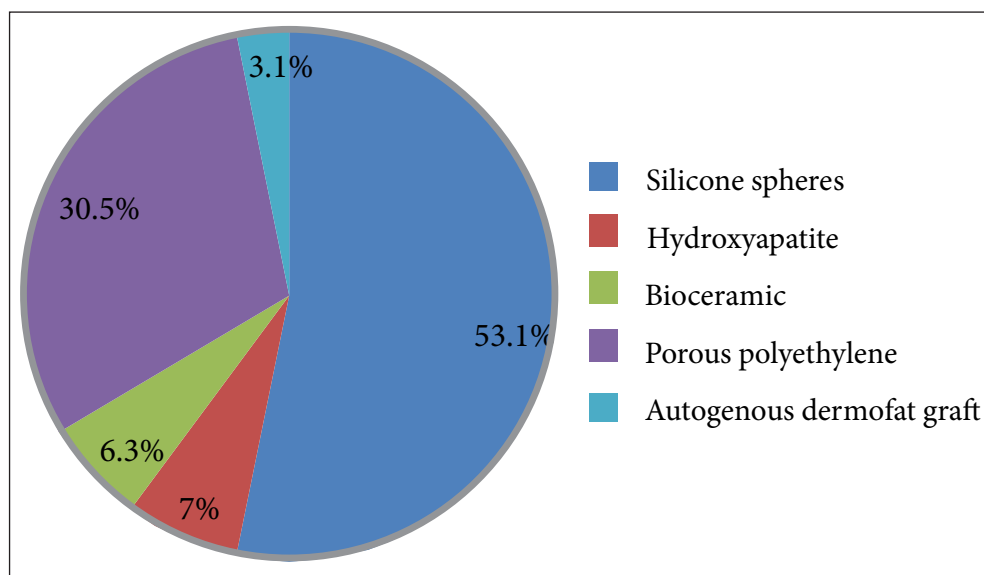


Fig. 1. Implants used for primary and secondary implantation

of it. The artificial eye, which presses the implant, causes ischemia, the implant protrudes and can be extruded. Treatment of this complication is difficult because of scarring and tissue contraction (23–28).

For one of our patients the implant extruded after he started wearing a new individual prosthesis, which, in to our opinion, was too large.

Infection is another well-known reason of implant protrusion and extrusion (29–31). Primary infection is the outcome of surgical intervention, and secondary infection is caused by partially protruded implant. There exist several opinions on the treatment of protruded implant. Some surgeons recommend conservative treatment (6, 11), others give preference to surgical treatment (27, 32–35) leaving the implant in place. The third group of surgeons hold the view that the protruded implant should be removed because it is the cause of infection (6).

We treated successfully one case of conjunctival erosion above the implant, two patients underwent surgical treatment leaving implant in place, one infected implant was removed after unsuccessful surgery, and one was extruded.

There is an opinion that non-integrated implants migrate and are extruded more often than integrated implants, but conjunctival erosion is more frequent above the latter (17, 19).

According to our data, five (2.9%) non-integrated silicone implants extruded, four (3.12%) integrated implants and one (0.78%) silicone implant protruded. Thus the above-mentioned results observed at the Eye Clinic of the Lithuanian University of Health Sciences confirm the data found in the literature.

CONCLUSIONS

1. The most common complications of orbital endoimplantation at the Eye Clinic during the analysed period were conjunctival erosion, cysts, and implant extrusion.

2. The types and the rate of complications observed in our study are consistent with the data found in the literature.

Received 20 January 2017

Accepted 1 June 2017

References

1. Implants and Prosthetics. Medical Devices. U.S. Food & Drug Administration. 2015.
2. Allen L, Ferguson EC, Braley AE. A quasi-integrated buried muscle cone implant motility with and advantages for prosthetic fitting. *Trans Amer Acad Ophthal Otolaryng.* 1960; good 64: 272.
3. Bartlett RE, Lewis F. Evaluation of enucleation and evisceration. *Amer J Ophthal.* 1964; 58: 835.
4. Fasanella RN, editor. *Management of Complications in Eye Surgery.* Philadelphia: Saunders, 1957.
5. Helveston EM. Human bank scleral patch for repair of exposed or extruded orbital implants. *Arch Ophthal Chicago.* 1969; 82: 83.
6. Iliff CE. The extruded implant. *Arch Ophthal Chicago.* 1967; 78: 742.
7. Smith B, Obear M, Leone CR. Jr. The correction of enophthalmos associated with anophthalmos by glass bead implantation. *Am J Ophthalmol.* 1967 Dec; 64(6): 1088–93.
8. Spivey BE, Allen L, Burns CA. The Iowa enucleation implant. A 10-year evaluation of technique and results. *Am J Ophthalmol.* 1969 Feb; 67(2): 171–88.
9. Fan JT, Robertson DM. Long-term follow-up of the Allen implant. 1967 to 1991. *Ophthalmology.* 1995; 102(3): 510–5.
10. Oestreicher JH. Treatment of exposed coral implant after failed scleral patch graft. *Ophthal Plast Reconstr Surg.* 1994; 10: 110–3.
11. Shannon GM, Connelly FJ. *Oculoplastic Surgery and prosthetics.* Boston: Little, Brown and Company, USA. 1970; 10(4): 681–849.
12. Adenis JP, Rulfi JY, Robert PI. Evisceration, using the technique of the Russian doll or of the parachute. *Abstracts of ESOPRS annual meeting, Santiago de Compostela, Spain.* 2001 June 14–16; p. 40, 44.
13. Kashkouli MB, Beigi B. Late exposure after upper eyelid tarsoconjunctival flap for exposed porous orbital implant. *Ophthalmic Surg Lasers Imaging.* 2004; 35(6): 499–502.
14. Iordanidou V, De Potter P. Porous polyethylene orbital implant in the pediatric population. *Am J Ophthalmol.* 2004; 138(3): 425–9.
15. Nolan LM, O'keefe M, Lanigan B. Hydroxyapatite orbital implant exposure in children. *J AAPOS.* 2003; 7(5): 345–8.
16. Heimann H, Bechrakis NE, Zepeda LC, Coup-land SE, Hellmich M, Foerster MH. Exposure of orbital implants wrapped with polyester-urethane

- after enucleation for advanced retinoblastoma. *Ophthal Plast Reconstr Surg.* 2005; 21(2): 123–8.
17. Chuah CT, Chee SP, Fong AS, Por YM, Choo CT, et al. Integrated hydroxyapatite implant and non-integrated implants in nucleated Asian patients. *Ann Acad Med Singapore.* 2004; 33(4): 477–83.
 18. Doung MH, Barraco P, Schapiro D, Ben Ayed H, Mordx S. Enucleation with on-the-table evisceration. Is it a good technique? *J Fr Ophthalmol.* 2001; 24(8): 836–41.
 19. Lumbroso L, Levy C, Plancher C, Validire P, Asselain B, Doz F, Schlienger P. Complications of hydroxyapatite orbital implants in children: a series of 105 cases. *J Fr Ophthalmol.* 2000; 23(3): 249–54.
 20. Christmas NJ, Van Quill K, Murray TG, Gordon CD, Garonzik S, Tse D, et al. Evaluation of efficacy and complications: primary pediatric orbital implants after enucleation. *Arch Ophthalmol.* 2000; 118(4): 503–6.
 21. Oestreicher JH, Lui E, Berkowitz M. Complications of Hydroxyapatite Orbital Implants. *Ophthalmology.* 1997; 104(2): 326–8.
 22. Stone W Jr. Complications of evisceration and enucleation. In: Fasanella RM, editor. *Management of Complications in Eye Surgery.* Philadelphia and London: Saunders, 1957.
 23. Levin MR. Enucleation, evisceration and exenteration. *AAO focal points 1984: clinical modules for ophthalmologists.* 1984; (4): 1–6.
 24. Custer PL, Kennedy RH, Woog JJ, Kaltreider SA, Meyer DR. Orbital implants in enucleation surgery: a report by the American Academy of Ophthalmology. *Ophthalmology.* 2003; 110(10): 2054–61.
 25. Jordan DR. Problems after evisceration surgery with porous orbital implants: experience with 86 patients. *Ophthal Plast Reconstr Surg.* 2004; 20(5): 374–80.
 26. Sagoo MS, Olver JM. Autogenous temporalis fascia patch graft for porous polyethylene (Medpor) sphere orbital implant exposure. *Br J Ophthalmol.* 2004; 88(7): 942–6.
 27. Sheikh I, Leibovitch I, Selva D, Daya S, Malhotra R. Pericranium grafts for exposed orbital implants. *Ophthal Plast Reconstr Surg.* 2005; 21(3): 216–9.
 28. Rubin PA, Fay AM, Remulla HD, Maus M. Ophthalmic plastic applications of acellular dermal allografts. *Ophthalmology.* 1999; 106(11): 2091–7.
 29. Jordan DR, Brownstein, Faraji H. Clinicopathologic analysis of 15 explanted hydroxyapatite implants. *Ophthal Plast Reconstr Surg.* 2004; 20(4): 285–90.
 30. Devoto MH, Zaffaroni MC. Orbital myiasis in a patient with a chronically exposed hydroxyapatite implant. *Ophthal Plast Reconstr Surg.* 2004; 20(5): 395–6.
 31. Iou JR, Seo JH, Kim IH, Choi WC. Six cases of bacterial infection in porous implants. *Jpn J Ophthalmol.* 2003; 47(5): 512–8.
 32. Tawfik HA, Budin H, Dutton JJ. Repair of exposed porous polyethylene implants utilizing flaps from the implant capsule. *Ophthalmology.* 2005; 112(3): 516–23.
 33. Salour H, Owji N, Farahi A. Two-stage procedure for management of large exposure defects of hydroxyapatite orbital implant. *Eur J. Ophthalmol.* 2003; 13(9–10): 789–93.
 34. Kim NJ, Choung HR, Khwarg SI, Yu YS. Free orbital fat graft to prevent porous polyethylene orbital implant exposure in patients with retinoblastoma. *Ophthal Plast Reconstr Surg.* 2005; 21(4): 253–8.
 35. Lee-Wing MW. Amniotic membrane for repair of exposed hydroxyapatite orbital implant. *Ophthal Plast Reconstr Surg.* 2003; 19(5): 401–2.
 36. Choi S, Lee SJ, Shin JH, Cheong I. Ultrastructural investigation of intact orbital implant surfaces using atomic force microscopy. *Scanning.* 2011; 33: 211–21.
 37. Su-Kyung J, Won-Kyung C, Ji-Sun P, Suk-Woo Y. Long-term surgical outcomes of porous polyethylene orbital implants: a review of 314 cases. *Br J Ophthalmol* doi:10. 1136/bjophthalmol-2011-300132
 38. Ramey N, Gupta D, Price K, Husain A, Richard M, Woodward J. Comparison of complication rates of porous anophthalmic orbital implants. *Ophtalmic Surg Lasers Imaging.* 2011 Sept–Oct; 42(5): 434–40.
 39. Lu L, Shi W, Luo M, Sun Y, Fan X. Repair of exposed hydroxyapatite orbital implants by subconjunctival tissue flaps. *J Craniofac Surg.* 2011 Jul; 22(4): 1452–6.

Raimonda Piškinienė, Mantas Banevičius

AKIDUOBĖS ENDOIMPLANTACIJOS KOMPLIKACIJOS LSMU AKIŲ LIGŲ KLINIKOJE

Santrauka

Tyrimo tikslas – išanalizuoti ligonių, operuotų LSMU Akių ligų klinikoje 2002–2014 m., akiduobės endoprotezavimo komplikacijas ir palyginti jas su literatūros duomenimis. Akies obuolį šalinti reikia labai rūpestingai, kad išvengtume bereikalingos papildomos traumos, infekcijos, deformacijų ir sukurtume optimalų junginės maišą. Tačiau, nepaisant palankiausių aplinkybių ir kvalifikuotų chirurgų, komplikacijų vis dėlto pasitaiko. Dažniausios literatūroje nurodomos akies obuolio pašalinimo su akiduobės endoimplantacija komplikacijos yra šios: junginės išplonėjimas, junginės cistos, sveitimūnio reakcija, sekrecija, simblefaronas, skliautų nepakankamumas, ptozė, nuolatinis skausmas, implanto dislokacija, migracija, prasigraužimas, pirminė ar antrinė infekcija, implanto išstūmimas. Tyrėme 128 ligonius, operuotus LSMU Akių ligų klinikoje 1999–2010 m. Nustatėme, kad dažniausios LSMU Akių klinikoje operuotiems ligoniams pasitaikiusios akiduobės endoimplantacijos komplikacijos – junginės erozija (5 pacientai – 2,9 %), cistos (9 pacientai – 7 %) ir implanto išstūmimas (5 pacientai – 2,9 %).

Komplikacijų dažnis ir pobūdis panašūs į literatūroje pateiktus duomenis.

Raktažodžiai: akiduobės implantas, poenukleacinis sindromas, akiduobės endoimplantacija