

Primary pulmonary plasmacytoma: a case report

Pirminė plaučių plazmacitoma: klinikinis atvejis

Andreja Arsovski¹, Liljana Stojanovska², Sasho Banev³, Zoran Dimitrov⁴

¹ *Private General Hospital "Remedika", Department of Surgery, 16-ta Makedonska brigada Str., No. 18, 1000 Skopje, Macedonia*

E-mail: arsovskia@yahoo.com; aarsovski@remedika.com.mk

² *Private General Hospital "Remedika", Department of Surgery, 16-ta Makedonska brigada Str., No. 18, 1000 Skopje, Macedonia*

E-mail: stojanovska_liljana@yahoo.com

³ *Private Health Institution Laboratory of Cytology and Histology "Biopsy", Vasil Levski Str., No. 1A, 1000 Skopje, Macedonia*

E-mail: banevs@freemail.com.mk

⁴ *Public Healthcare Institution "General Hospital Gevgelija", Department of Surgery, Slobodan Mitrov - Danko Str., No. 38, 1480 Gevgelija, Macedonia*

E-mail: dimitrov_zoran@yahoo.com

Background

Extramedullary plasmacytoma is a plasma cell malignancy that most commonly occurs in the upper respiratory tract. These tumors account for less than 5% from all plasma cell neoplasms. In most of the cases, tumor first appears in the mucosa of the upper respiratory tract, mainly in the paranasal sinuses. When only located in the lower respiratory tract (primary pulmonary plasmacytoma), the diagnosis is difficult and is usually based on the pathological findings from excised tissue.

Case report

We present one case of primary pulmonary plasmacytoma, which accidentally was diagnosed in our hospital, and this is the first case of primary pulmonary plasmacytoma reported in our country. In the present article, we describe a primary pulmonary plasmacytoma (PPP) of the right lower lobe without loco-regional lymph node involvement, treated radically. The histological finding was confirmed by immunohistochemistry. There was no clinical evidence for the presence of multiple myeloma.

Conclusion

Primary pulmonary plasmacytoma present a rare neoplasm which could be differentially diagnostically classified as adenocarcinoma. The diagnosis of this tumor is based on pathological findings from excised tissue. The radical surgical treatment presents primary treatment option and, if there are no signs of the dissemination of the disease or of the presence of multiple myeloma, adjuvant chemotherapy is not needed.

Key words: primary pulmonary plasmacytoma, extramedullary plasmacytoma, plasma cell neoplasm

Introduction

Extramedullary plasmacytoma is a plasma cell malignancy that most commonly occurs in the upper respiratory tract. These tumors account for less than 5% of all plasma cells neoplasms [1]. In most of the cases, tumor first appears in the mucosa of the upper respiratory tract, mainly in the paranasal sinuses [2]. Plasmacytoma located in the lung is an unusual finding, and in such cases the disease may be confined to the lung and regional lymph nodes or may be disseminated [3]. When only located in the lower respiratory tract (primary pulmonary plasmacytoma), the diagnosis is difficult and is usually based on the pathological findings from excised tissue [3]. These tumors seldom produce paraprotein, but those that do are generally associated with immunoglobulin (Ig) G kappa monoclonal gammopathy [4].

We present one case of primary pulmonary plasmacytoma, which accidentally was diagnosed in our hospital, and this is the first case of primary pulmonary plasmacytoma reported in our country.

In the present article, we describe a primary pulmonary plasmacytoma (PPP) of the right lower lobe without loco-regional lymph node involvement, treated radically. The histological finding was confirmed by immunohistochemistry and there was no clinical evidence for the presence of multiple myeloma (MM).

Primary pulmonary plasmacytoma (PPP) is a rare plasma cell neoplasm and in the medical literature is described only as case reports.

Case report

In our report, we present a case of 72-year-old male patient with the history of 20 years of type 2 diabetes mellitus. More than two years he is on insulin treatment.

In spite of this, he has a diagnosed arterial hypertension and signs and symptoms of weakened circulation in lower extremities, loss of toenails on the legs and trophic changes on the left foot. He is a non-smoker. The patient came to our hospital for the treatment of arterial insufficiency and trophic changes in the left foot.

The patient was advised by a vascular surgeon to make CT (computed tomography) angiography of the aorta and large blood vessels of the lower extremities.

Radiological findings

CT angiography of the aorta and large blood vessels of the lower extremities was performed. Arterial circulation in the fetlock of both lower limbs was significantly compromised by advanced atherosclerotic changes. Obstruction in arterial circulation in the right leg was dominant in the right anterior tibial artery and in the peroneal artery. In the left leg, the obstruction was dominant in two branches of the posterior tibial artery – peroneal artery and medial malleolar artery.

Additionally, on the lung, the radiologist described a rounded nodular pathological mass in the right lower lobe. He advised to perform CT of the lung.

In this patient, an enhanced chest CT scan with native series and a series after the intravenously administered contrast were performed.

On the CT scan, in the right lower lobe, in the medial-basal segment there was detected a circumscribed, rounded tumorous consolidation with the dimension of 3 cm, clearly confined from the surrounding normal tissue.

The other findings of the lungs and mediastinum were without pathologic abnormalities. No enlarged loco-regional lymph nodes were detected on the CT scan.

On virtually performed bronchoscopy from CT scans, an orderly transition of the tracheobronchial tract was detected.

On CT series after intravenous administration of the contrast, pathologic consolidation seen in native series was detected as a pathologic abnormality with the retention of the administered contrast (Figure 1).

Percutaneous trans-thoracic needle core biopsy from the detected tumor in the right lower lobe was performed. The patient was advised to consult a thoracic surgeon.

After consultation with the thoracic surgeon, additional examinations were performed.

Hematology findings

Hb – 125 g/L; Hct – 35.4%; RBC – $4.40 \times 10^{12}/L$; WBC – $7.3 \times 10^9/L$; PLT – $243 \times 10^9/L$.

Biochemistry findings

K – 4.58 mmol/L; Na – 140.4 mmol/L; Cl – 99.3 mmol/L; urea – 5.5 mmol/L; creatinine –

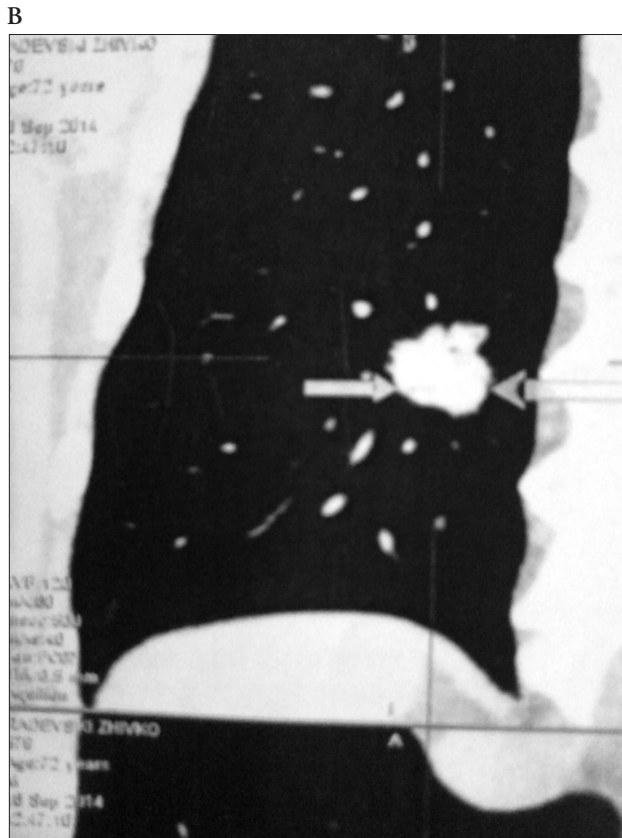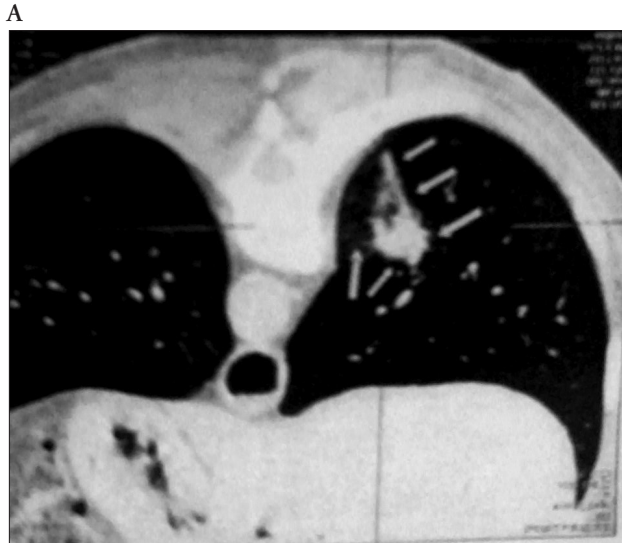


Figure 1. Enhanced chest computed tomography scan with intravenously administered contrast (A and B – CT scan reconstruction). Pathological mass with the retention of contrast – marked with arrows

64 $\mu\text{mol/L}$; albumin – 43 g/L; total proteins – 65 g/L, and CRP – 5.28 mg/L.

Pulmonary function test findings

FVC 3.51 L; FEV₁ – 3.03 L; FEV₁ / FVC 86.3%; PEF – 4.87 L/s; FEF25 – 4.60 L/s; FEF50 – 3.35 L/s; FEF75 – 1.81 L/s; FET 2.03 s.

Echocardiography findings

LVedd – 5 cm; LVesd – 3.6 cm; RV – 2.5 cm; MV – 0.9 m/s; muscle mass – 198 g; EF – 57%; LV – with a medium diastolic dysfunction; RV – orderly function; mitral valve, aortic valve, pulmonary valve, tricuspid valve – with orderly function.

Cytology findings from trans-thoracic needle core biopsy

Cytology findings from tumor core biopsy show a solid to irregular gland-like architecture built from cylindrical cells with vacuolated cytoplasm and a large nucleus with separate mitosis, with suggestive mucin production. Cytological finding according to the pathologist was in favor of moderate differentiated solid adenocarcinoma of the lung (Figure 2).

Treatment

According to the cytological diagnosis, CT finding and results obtained from other examinations, an indication for surgical treatment was established.

After the preoperative preparation of the patient for surgical intervention and the examination by the anesthesiologist, the patient was operated on under general anesthesia with a double-lumen endotracheal tube.

A lateral, muscle-sparing thoracotomy was performed. In the right lower lobe, a solid, rounded tumor mass with approximately 3 cm in the diameter was found.

Intraoperative vascular and bronchial staplers were used. A radical right lower lobectomy was performed without any intraoperative complications.

A loco-regional lymphadenectomy was done. Macroscopically excised lymph nodes were not enlarged. Two thoracic drains were placed.

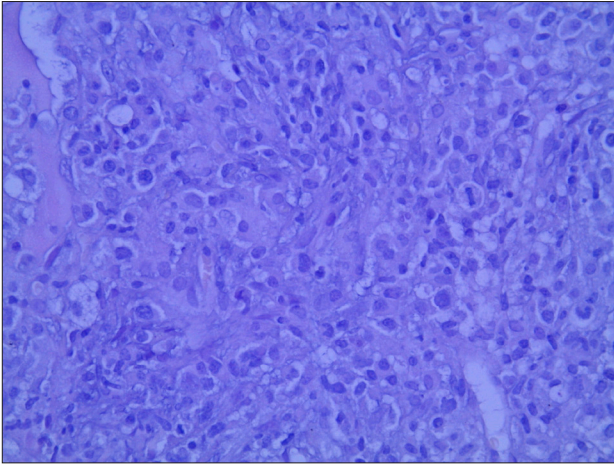


Figure 2. Cytological image (original magnification x 400). Hematoxylin and eosin staining of tumor biopsy. Solid to irregular gland-like architecture of the cells

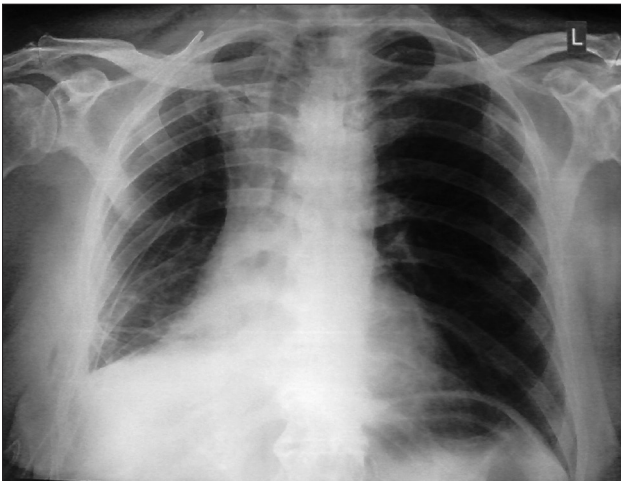


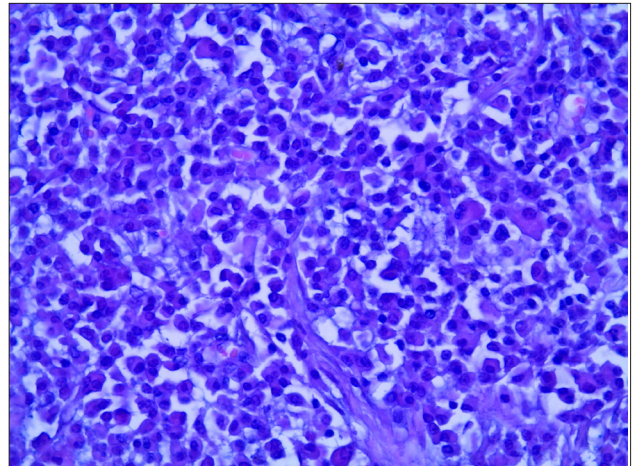
Figure 3. Postoperative X-ray control evaluation. Status after right lower lobectomy with ordinary transparency of the right upper and middle lobes and the mediastinum dragged to the right

Postoperatively, as an antibiotic treatment, amp. Clindamycin à 0,6 g 2 x 1 (Klimicin, Lek pharmaceutical company d.d. Ljubljana, Slovenia) was administered and a high epidural catheter for analgesia was placed.

The resected tissue was sent for pathological analysis.

Thoracic drains were removed on the second and fourth postoperative days. Chest X-ray evaluation was performed on the first and fifth postoperative days (Figure 3).

A



B

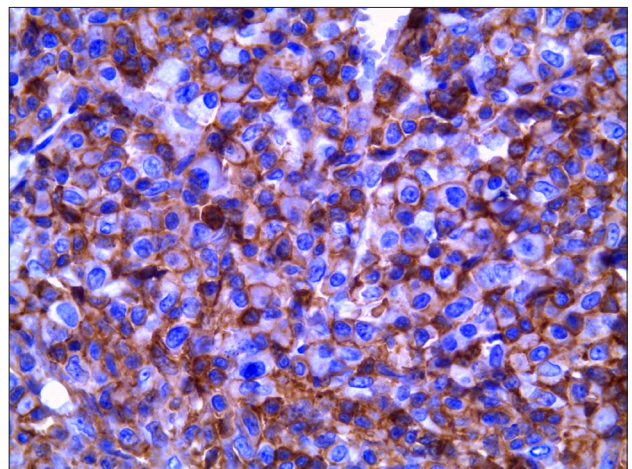


Figure 4. Hematoxylin and eosin staining of resected right lower lobe (4A). Immunohistochemical staining of tumor with antibodies to CD79 α (4B)

The patient was discharged from our hospital on the seventh postoperative day, and the first control was carried out after seven days with orderly postsurgical findings.

Pathological finding

In the resected tissue, the pathologist found a macroscopically well visible circumscribed, rounded, grey-white nodule 3 cm in diameter. The microscopic finding showed irregular sheets of atypical and normal plasma cells, and scanty fibro-vascular tissue was found between plasma cells (Figure 4, A).

Immunohistochemical analysis of the resected tumor showed a strong positive CD79 α (Figure 4, B).

The differential diagnosis from pathological findings includes plasma cell granuloma (inflammatory neofibroblastic tumor), but the lack of mixed inflammatory cells and myofibroblastic cells favor the diagnosis of primary pulmonary plasmacytoma (PPP).

There was no evidence of MM in the subsequent bone marrow biopsy made after receiving the pathological finding. At the same time, biochemistry finding for the urinary Bence–Jones protein was performed, and the result was negative.

The final diagnosis of primary pulmonary plasmacytoma was made.

Discussion

Extramedullary plasmacytoma is a monoclonal proliferation of plasma cells in soft tissues or in organs. The relationship among multiple myeloma, solitary plasmacytoma of bone, and extramedullary plasmacytoma is not well understood.

Extramedullary plasmacytoma should be regarded differently from primary plasma cell bone marrow tumors [2].

Extramedullary plasmacytoma in the upper airways is more common in men. The most usual age of the onset is 50 to 60 years, and clinical signs reflect the location of the tumor [3]. Primary pulmonary plasmacytoma evolves differently from multiple myeloma, and prolonged survival rates have been described.

However, they are so rare that nothing is known about the prognosis. The 10-year overall survival rate from extramedullary plasmacytoma according to some studies is 70% [5].

In the largest series in the literature, 66% survived for 2 years and 40% for 5 years. Two patients survived for 20 years [6].

The rate of progression to multiple myeloma is lower

than in solitary bone plasmacytoma, ranging within 11–30% in 10 years [7].

The treatment for primary pulmonary plasmacytoma has not been fully established. Surgical resection can be considered curative if it is complete [8, 9].

In some of the surgically treated patients, radiotherapy was performed as a post-operative treatment, and other patients were treated with radiotherapy and chemotherapy. There was no difference in the survival, although it is difficult to evaluate as the follow-up information is scanty.

After receiving the results of pathological findings, additional examinations were performed (bone marrow biopsy and urine test for the presence of the Bence–Jones protein). The existence of multiple myeloma was excluded from the obtained result of bone marrow biopsy and negative urine test for the presence of the Bence–Jones protein.

The final diagnosis of primary pulmonary plasmacytoma was made.

After consultations with the hematologist and the oncologist, it was decided not to administer any additional therapy.

The patient was advised to perform a routine check-up every six months for monitoring of the further course the disease.

Conclusion

Primary pulmonary plasmacytoma presents a rare neoplasm which could diagnostically be classified as adenocarcinoma. The diagnosis of this tumor is based on pathological findings from excised tissue. The treatment protocol for this neoplasm is not established due to the limited follow-up data only for a little number of patients. Radical surgical treatment presents the primary treatment option, and if there are no signs of the dissemination of the disease or of the presence of multiple myeloma, adjuvant chemotherapy is not needed.

REFERENCES

1. Galieni P, Cavo M, Pulsoni A, et al. Clinical outcome of extramedullary plasmacytoma. *Haematologica* 2000; 85: 47–51.
2. Wiltshaw E. The natural history of extramedullary plasmacytoma and its relation to solitary myeloma of bone and myelomatosis. *Medicine (Baltimore)* 1976; 55: 217–238.
3. Carmen Montero, Ana Souto, Iria Vidal, María del Mar Fernández, Marina Blanco, Héctor Vereá. Three cases of Primary Pulmonary Plasmacytoma. *Arch Bronconeumol* 2009; 45 (11); 564–566.
4. Sen Wei, MD, Xin Li, MD et al. Primary endobronchial plasmacytoma involving local lymph nodes and presenting with rare immunoglobulin G lambda monoclonal gammopathy. *Can Respir J* 2012. May–Jun: 19 (3); 28–30.
5. Soutar R, Lucraft H, Jackson G et al. Guidelines on the diagnosis and management of solitary plasmacytoma of bone and solitary extramedullary plasmacytoma. *Clin Oncol (R Coll Radiol)* 2004; 16 (6): 405–413.
6. Koss MN, Hochholzer L, Moran CA. Pulmonary plasmacytomas: a clinicopathologic and immunohistochemical study of five cases. *Ann Diagn Pathol* 1998; 2: 1–11.
7. Hu K, Yahalom J. Radiotherapy in the management of plasma cell tumours. *Oncology (Huntingt)* 2000; 14 (1): 101–108, 111.
8. Wang J, Pandha HS, Treleaven J, Powles R. Metastatic extramedullary plasmacytoma of the lung. *Leuk Lymphoma* 1999; 35: 423–425.
9. Hayes-lattin B, Blanke CD, Deloughery T. Pulmonary and intracerebral plasmacytomas in a patient without multiple myeloma: a case report. *Am J Hematology* 2003; 73: 131–134.